Infección del tracto urinario (ITU) y Reflujo Vesicoureteral (RVU)

Isabel Roca
SIMM Molecular
Barcelona

Consecuencias a largo término de las Pielonefritis Agudas en Pediatría

- Cicatrices corticales
- Lesiones corticales difusas y riñón pequeño
- Proteinuria
- Hipertension
- Complicaciones durante el embarazo: infecciones urinarias, HTA,…
- Enfermedad renal crónica
- Insuficiencia renal…

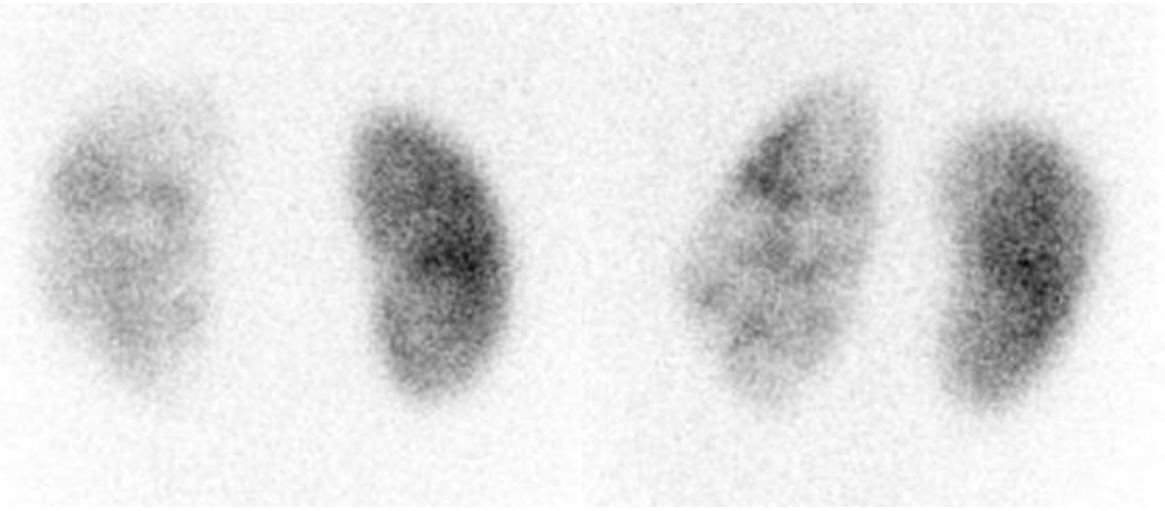

Medicina Nuclear en Pediatría - ITU y RVU

1- GAMMAGRAFÍA RENAL CORTICAL ^{99m}Tc-DMSA
2- CISTOGAMMAGRAFÍA DIRECTA
3- CISTOGAMMAGRAFÍA INDIRECTA

DMSA

Cistogammagrafía Directa

Cistogammagrafía Directa

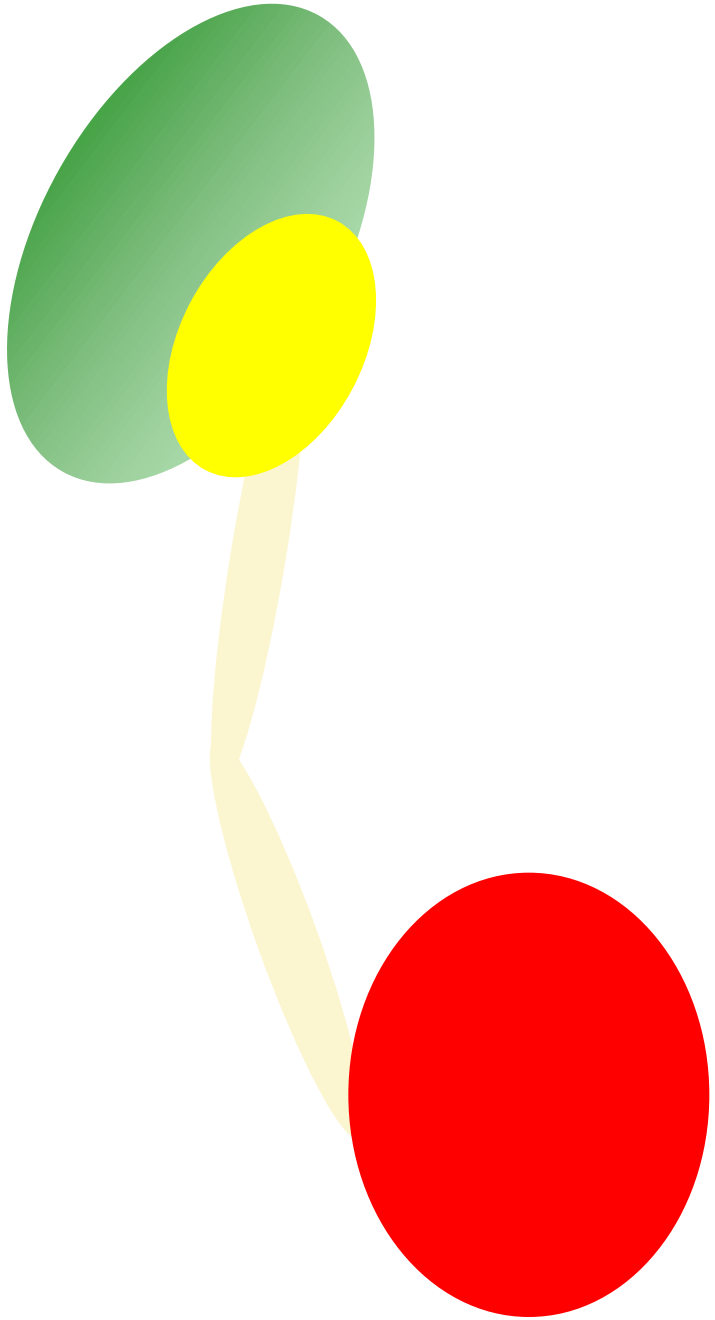

- Gammagrafía cortical renal con ^{99m}Tc-DMSA
- Cistogammagrafía
- ITU y RVU
- Guias Clínicas – Indicaciones actuales
- Qué hay de nuevo? – Líneas de futuro

- Gammagrafía cortical renal con ^{99m}Tc-DMSA
- Cistogammagrafía
- ITU y RVU
- Guias Clínicas – Indicaciones actuales
- Qué hay de nuevo? – Líneas de futuro

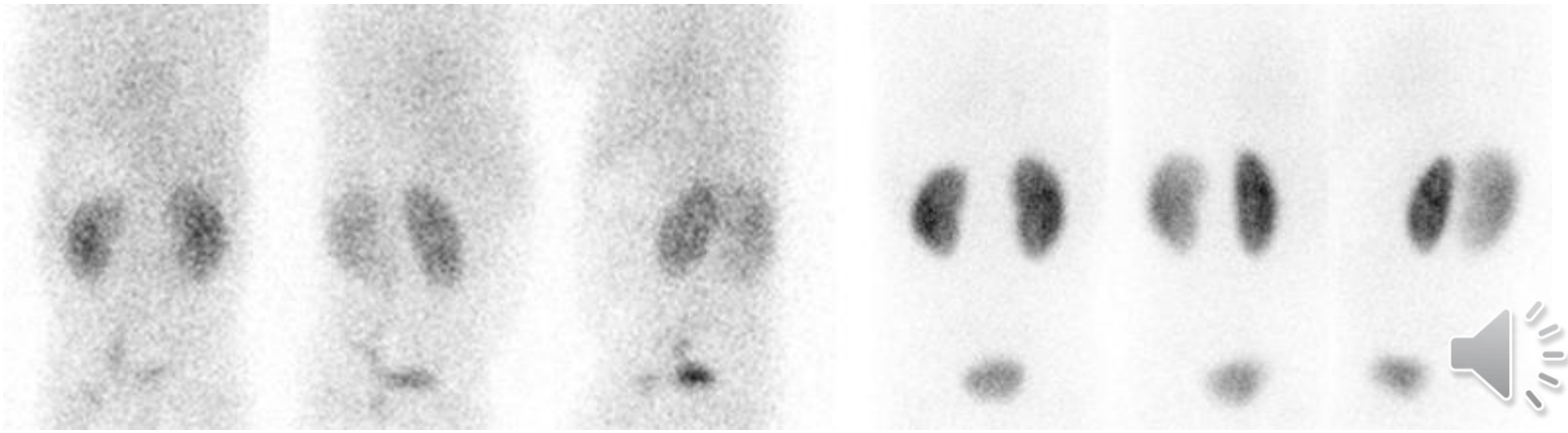

TÉCNICA - Guidelines

SNMMI Value Initiative
SOCIETY OF NUCLEAR MEDICINE & MOLECULAR IMAGING

Society of Nuclear Medicine Procedure Guideline for Renal Cortical Scintigraphy in Children

version 3.0, Approved June 20, 2003

Authors: Gerald A. Mandell, MD (Phoenix Children's Hospital, Phoenix, AZ); Douglas F. Eggli, MD (Pennsylvania State University/Milton S. Hershey Medical Center, Hershey, PA); David L. Gilday, MD (Hospital For Sick Children, Toronto, Ontario, Canada); Sydney Heyman, MD (Children's Hospital of Philadelphia, PA); Joe C. Leonard, MD (Oklahoma Children's Memorial Hospital, Oklahoma City, OK); John H. Miller, MD (Children's Hospital Los Angeles, Los Angeles, CA); Helen R. Nadel, MD (Children's Hospital, British Columbia, Vancouver, Canada); Amy Piepsz, MD (CHU St. Pierre, Department of Radioisotopes, Brussels, Belgium); and S. Ted Treves, MD (Children's Hospital, Boston, MA).

EANM
European Association of Nuclear Medicine

GUIDELINES ON ^{99m}Tc-DMSA SCINTIGRAPHY IN CHILDREN

Issued: October 3, 2009

Amy Piepsz[1], Paula Colarinha[2], Isky Gordon[3], Klaus Hahn[4], Pierre Olivier[5], Isabel Roca[6], Rune Sixt[7], Jeannette van Velzen[8].

CHU St Pierre, Brussels, Belgium[1]; Instituto Português de Oncologia, Lisbon, Portugal[2] ; Great Ormond Street Hospital for Children, London, UK[3]; Dept. of Nuclear Medicine, University of Munich, Germany[4]; CHU Nancy, France[5]; Hospital Vall d'Hebron, Barcelona, Spain[6]; The Queen Silvia Children's Hospital, Göteborg, Sweden[7], liaison person from ARPES[8].

Under the Auspices of the Paediatric Committee of the European Association of Nuclear Medicine – update 2009.

Methodology for ^{99m}Tc DMSA scintigraphy

Dose:

minimum: 15 – 20 MBq
maximum (adult): 100-110 MBq (HUVH 74 MBq)

Imaging:

2-3 hours post injection
Delayed imaging (up to 24hrs) if hydronephrosis present
Posterior view – min 200K or 5 minutes
Both posterior oblique views
Anterior view: horseshoe kidney, renal ectòpia, kidney transplant
High resolution parallel hole collimator

Additional imaging

- Pinhole using 2-4 mm aperture insert.
- 100 -150 K or 10 minutes
- SPECT

Timing of DMSA studies

Acute

– Detection of pyelonephritis
- As soon as possible after the onset of the f-UTI: 24-48 h, less than 7 days

Chronic

– Detection of scarring
– Must wait at least 6-12 months from acute UTI

DOSIS

dosis mínima óptima

DOSIS
MÍNIMA
ÓPTIMA

Nos permite:

- obtener la mejor calidad posible de imagen
- administrar la menor dosimetría
- Neonatos: Dosis mínima

Último update

Agosto 2016

ALARA

EANM European Association of Nuclear Medicine — BIOMEDICAL IMAGING AND THERAPY FOR PERSONALIZED HEALTHCARE

Dosage Card (Version 5.7.2016)

Multiple of Baseline Activity

Weight kg	Class A	Class B	Class C	Weight kg	Class A	Class B	Class C
3	1	1	1	32	3.77	7.29	14.00
4	1.12	1.14	1.33	34	3.88	7.72	15.00
6	1.47	1.71	2.00	36	4.00	8.00	16.00
8	1.71	2.14	3.00	38	4.18	8.43	17.00
10	1.94	2.71	3.67	40	4.29	8.86	18.00
12	2.18	3.14	4.67	42	4.41	9.14	19.00
14	2.35	3.57	5.67	44	4.53	9.57	20.00
16	2.53	4.00	6.33	46	4.65	10.00	21.00
18	2.71	4.43	7.33	48	4.77	10.29	22.00
20	2.88	4.86	8.33	50	4.88	10.71	23.00
22	3.06	5.29	9.33	52-54	5.00	11.29	24.67
24	3.18	5.71	10.00	56-58	5.24	12.00	26.67
26	3.35	6.14	11.00	60-62	5.47	12.71	28.67
28	3.47	6.43	12.00	64-66	5.65	13.43	31.00
30	3.65	6.86	13.00	68	5.77	14.00	32.33

$$A[MBq]_{\text{Administered}} = BaselineActivity \times Multiple$$

a) For a calculation of the administered activity, the baseline activity value has to be multiplied by the multiples given above for the recommended radiopharmaceutical class (see reverse).

b) If the resulting activity is smaller than the minimum recommended activity, the minimum activity should be administered.

c) The national diagnostic reference levels should not be exceeded!

Examples:

a) ^{18}F FDP-PET Brain, 50 kg: activity to be administered [MBq] = 14.0 x10.71 [MBq] ≈ 150 MBq

b) ^{123}ImIBG, 3 kg: activity to be administered [MBq] = 28.0 x1 [MBq] = 28 MBq
< 37 MBq (Minimum Recommended Activity)
→ **activity to be administered: 37 MBq**

This card is based upon the publication by Jacobs F, Thierens H, Piepsz A, Bacher K, Van de Wiele C, Ham H, Dierckx RA. Optimized tracer-dependent dosage cards to obtain weight-independent effective doses. Eur J Nucl Med Mol Imaging. 2005 May; 32(5):581-8.

This card summarizes the views of the Paediatric and Dosimetry Committees of the EANM and reflects recommendations for which the EANM cannot be held responsible.
The dosage recommendations should be taken in context of „good practice" of nuclear medicine and do not substitute for national and international legal or regulatory provisions.

Android App

iPhone App

EANM Executive Office
Schmalzhofgasse 26 · 1060 Vienna, Austria
Phone: +43 (0) 1 890 44 27, fax: +43 (0) 1 890 44 27-9
office@eanm.org - www.eanm.org - fb.com/officialEANM

Recommended Amounts in MBq

Radiopharmaceutical	Class	Baseline Activity (for calculation purposes only) MBq	Minimum Recommended Activity[1] MBq
^{123}I (Thyroid)	C	0.6	3
^{123}I Amphetamine (Brain)	B	13.0	18
^{123}I HIPPURAN (Abnormal renal function)	B	5.3	10
^{123}I HIPPURAN (Normal renal function)	A	12.8	10
^{123}I mIBG	B	28.0	37
^{131}I mIBG	B	5.6	35
^{18}F FDG-PET torso	B	25.9	26
^{18}F FDG-PET brain	B	14.0	14
^{18}F Sodium fluoride	B	10.5	14
^{67}Ga Citrate	B	5.6	10
^{68}Ga-labelled peptides	B	12.8	14
^{99m}Tc ALBUMIN (Cardiac)	B	56.0	80
^{99m}Tc COLLOID (Gastric Reflux)	B	2.8	10
^{99m}Tc COLLOID (Liver/Spleen)	B	5.6	15
^{99m}Tc COLLOID (Marrow)	B	21.0	20
^{99m}Tc DMSA	B	6.8	18.5
^{99m}Tc DTPA (Abnormal renal function)	B	14.0	20
^{99m}Tc DTPA (Normal renal function)	A	34.0	20
^{99m}Tc ECD	B	51.8	100
^{99m}Tc HMPAO (Brain)	B	51.8	100
^{99m}Tc HMPAO (WBC)	B	35.0	40
^{99m}Tc IDA (Biliary)	B	10.5	20
^{99m}Tc MAA / Microspheres	B	5.6	10
^{99m}Tc MAG3	A	11.9	15
^{99m}Tc MDP	B	35.0	40
^{99m}Tc Pertechnetate (Cystography)	B	1.4	20
^{99m}Tc Pertechnetate (Ectopic Gastric Mucosa)	B	10.5	20
^{99m}Tc Pertechnetate (Cardiac First Pass)	B	35.0	80
^{99m}Tc Pertechnetate (Thyroid)	B	5.6	10
^{99m}Tc RBC (Blood Pool)	B	56.0	80
^{99m}Tc SestaMIBI/Tetrofosmin (Cancer seeking agent)	B	63.0	80
^{99m}Tc SestaMIBI/Tetrofosmin[2] (Cardiac rest scan 2-day protocol min)	B	42.0	80
^{99m}Tc SestaMIBI/Tetrofosmin[2] (Cardiac rest scan 2-day protocol max)	B	63.0	80
^{99m}Tc SestaMIBI/Tetrofosmin[2] (Cardiac stress scan 2-day protocol min)	B	42.0	80
^{99m}Tc SestaMIBI/Tetrofosmin[2] (Cardiac stress scan 2-day protocol max)	B	63.0	80
^{99m}Tc SestaMIBI/Tetrofosmin[2] (Cardiac rest scan 1-day protocol)	B	28.0	80
^{99m}Tc SestaMIBI/Tetrofosmin[2] (Cardiac stress scan 1-day protocol)	B	84.0	80
^{99m}Tc Spleen (Denatured RBC)	B	2.8	20
^{99}Tc TECHNEGAS (Lung ventilation)[3]	B	49.0	100

[1] The minimum recommended activities are calculated for commonly used gamma cameras or positron emission tomographs. Lower activities could be administered when using systems with higher counting efficiency.

[2] The minimum and maximum values correspond to the recommended administered activities in the EANM/ESC procedural guidelines (Hesse B, Tagil K, Cuocolo A, et al). EANM/ESC procedural guidelines for myocardial perfusion imaging in nuclear Cardiology. Eur J Nucl Med Mol Imaging. 2005 Jul;32(7):855-97.

[3] This is the activity load needed to prepare the Technegas device. The amount of inhaled activity will be lower.

Jacobs F, Thierens H, Piepsz A, Bacher K, Van de Wiele C, Ham H, Dierckx RA. Optimized tracer-dependent dosage cards to obtain weightindependent effective doses. Eur J Nucl Med Mol Imaging. 2005 May; 32(5):581-8.

M. Lassmann, S.T.Treves. Pediatric Radiopharmaceutical Administration: Harmonization of the 2007 EANM Paediatric Dosage Card (Version 1.5.2008) and the 2010 North America Consensus guideline, Eur J Nucl Med Mol Imaging. 2014, DOI: 10.1007/s00259-014-2731-9.

Lassmann M, Biassoni L, Monsieurs M, Franzius C; EANM Dosimetry and Paediatrics Committees. The new EANM paediatric dosage card: additional notes with respect to F-18. Eur J Nucl Med Mol Imaging. 2008 Sep;35(9):1666-8. doi: 10.1007/s00259-008-0799-9. Epub 2008 Jun 24. Erratum in: Eur J Nucl Med Mol Imaging. 2008 Nov;35(11):2141

https://www.eanm.org/publications/dosage-card/

DOSIS y DOSIMETRIA

Summary of Guidelines for Dosing ^{99m}Tc-DMSA

Parameter	SNMMI (*6*)	NACG (*7*)	ACR (*8*)	EANM (*9,10,13*)
Activity per kilogram	NA	1.85 MBq/kg (0.05 mCi/kg)	1.85–3.7 MBq/kg (0.05–0.1 mCi/kg)	Dose card based on BW (*9*)
Minimum activity	~11 MBq (0.3 mCi)	18.5 MBq (0.5 mCi)	11.1–37 MBq (0.3–1.0 mCi)	15 MBq (0.4 mCi) (*10*)
Maximum activity	~110 MBq (3.0 mCi)	NA	111–185 MBq (3.0–5.0 mCi)	80–160 MBq (2.2–4.3 mCi) (*13*)
Parallel counts or time	300,000–500,000 (no time listed)	NA	300,000 or 5 min	300,000 or ~5 min (*10*)
Pinhole counts or time	~150,000 counts or 15–20 min/image	NA	100,000–150,000 counts or 10 min/image	100,000–150,000 or ~10 min/image (*10*)

Galbraith W, Nguyen A, Harrison DL, Chen X, Talley K.
Evaluation of 99mTc-succimer dosing in pediatric patients
J Nucl Med Technol. 2013 Jun;41(2):81-4

DOSIS y DOSIMETRIA

DMSA
Rango 0.9 a 1 mSv

CUMS – Cistouretrografía miccional seriada radiológica
Rango 0.6 a 3,2 mSv

GAMMAGRAFÍA RENAL CORTICAL

^{99m}Tc - DMSA

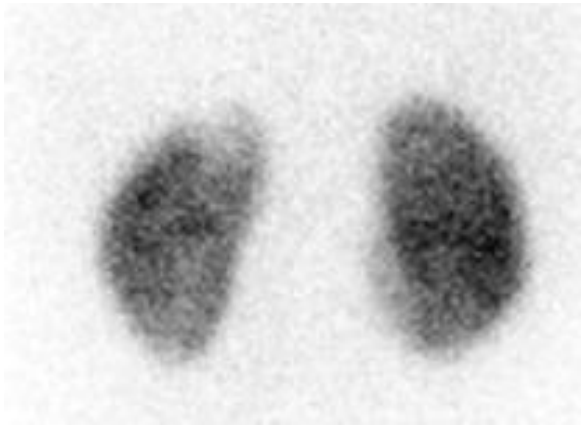

Planar



SPECT*

Pin hole

*Thanks to Dr. Zvi Bar Sever

VARIABLES NORMALES

- APLANAMIENTO del polo o tercio superolateral del riñón izquierdo
- Hipoactividad del polo superior del riñón izquierdo por atenuación esplénica
- Columnas de Bertin con captación prominente

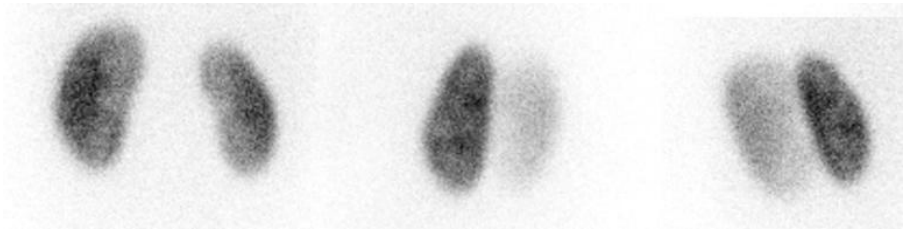

ARTEFACTOS POR MOVIMIENTO

sin sedación…
…a veces la colaboración es difícil

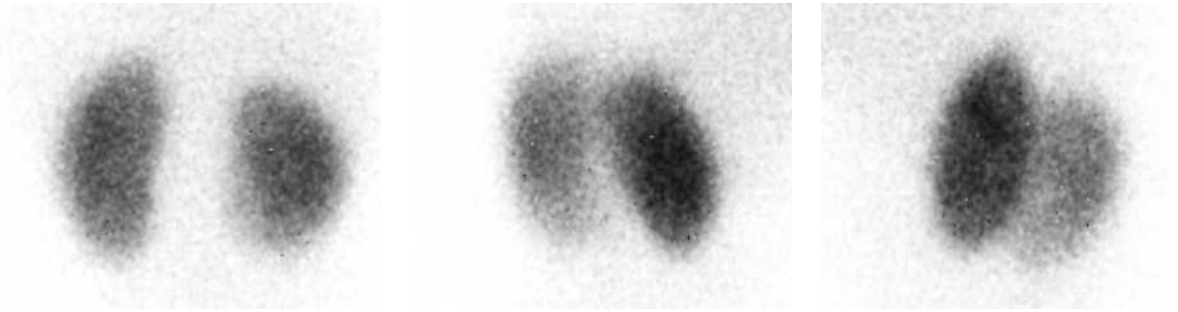

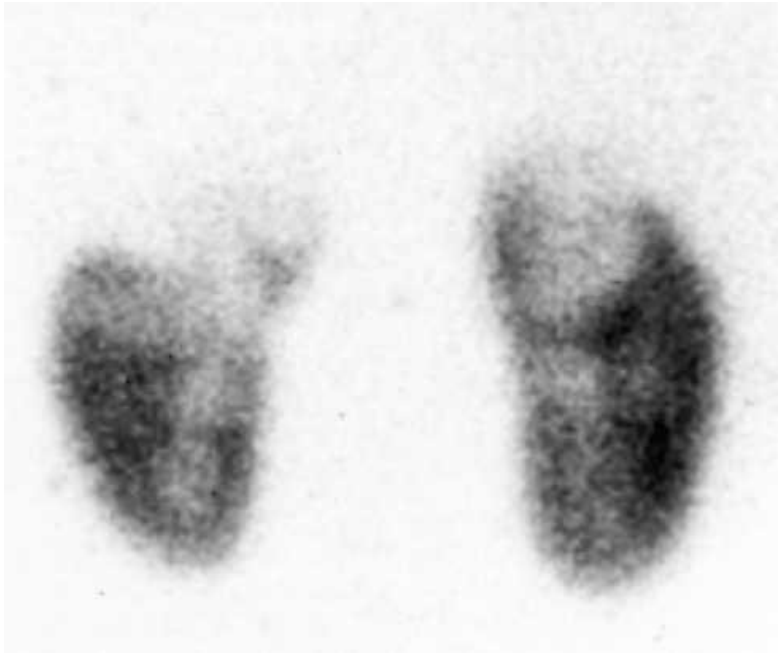

Tenemos que obtener imágenes de calidad suficientemente buena para detectar y poder valorar defectos corticales focales

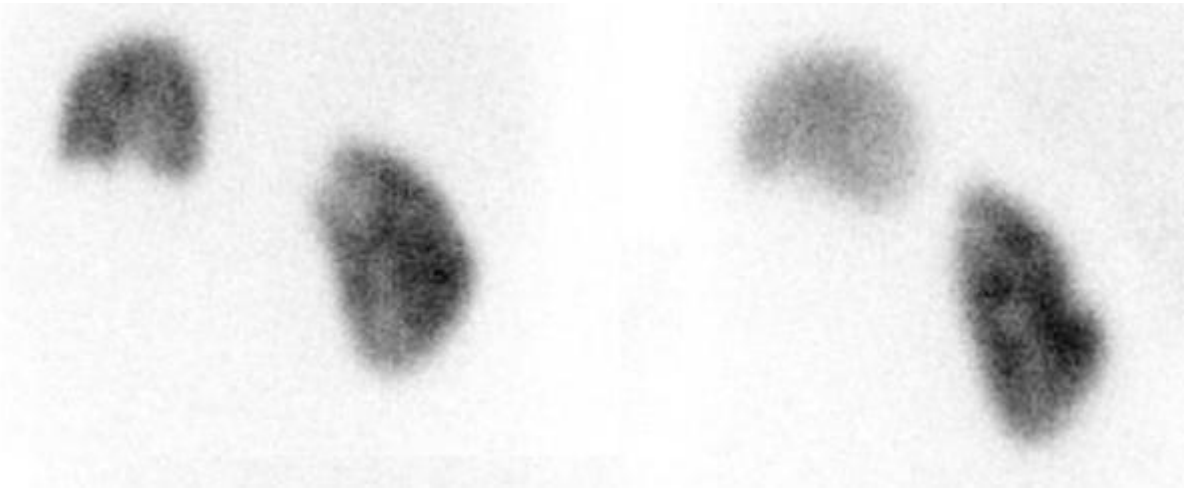

Las detecciones oblícuas laterales derecha e izquierda son obligatorias

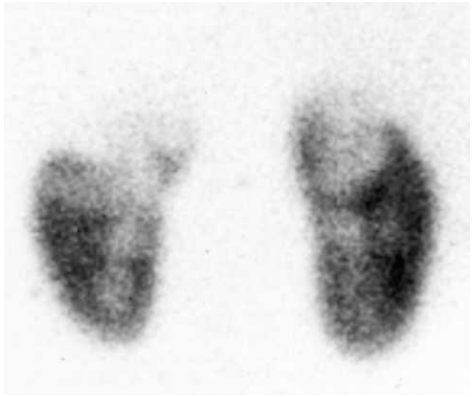

- Las áreas con PNA son hipoactivas o frías y pueden no afectar el contorno renal

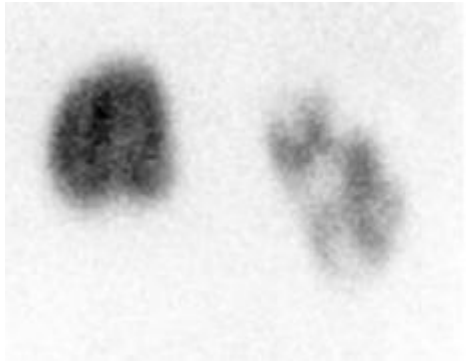

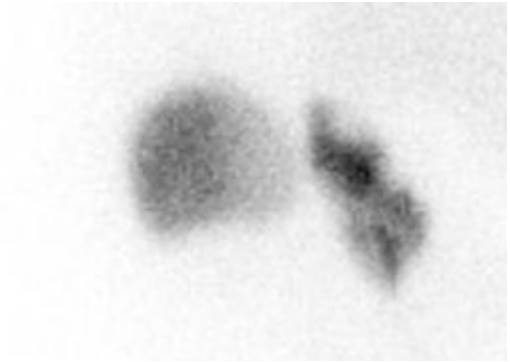

- Las lesiones pielonefríticas crónicas = concavidades que deforman con retracciones el contorno renal

GAMMAGRAFÍA RENAL CORTICAL

NORMAL

1 m

6 m

PIELONEFRITIS AGUDA

En el periodo neonatal

Controles: secuelas severas

12 m

24 m

MECANISMO DE OBTENCIÓN DE IMAGEN

CAPTACIÓN RENAL ^{99M}TC-DMSA

- Filtrado glomerular unido a α1-microglobulina
- Endocitosis en la células del túbulo contorneado proximal
- Actividad residual en orina - vejiga

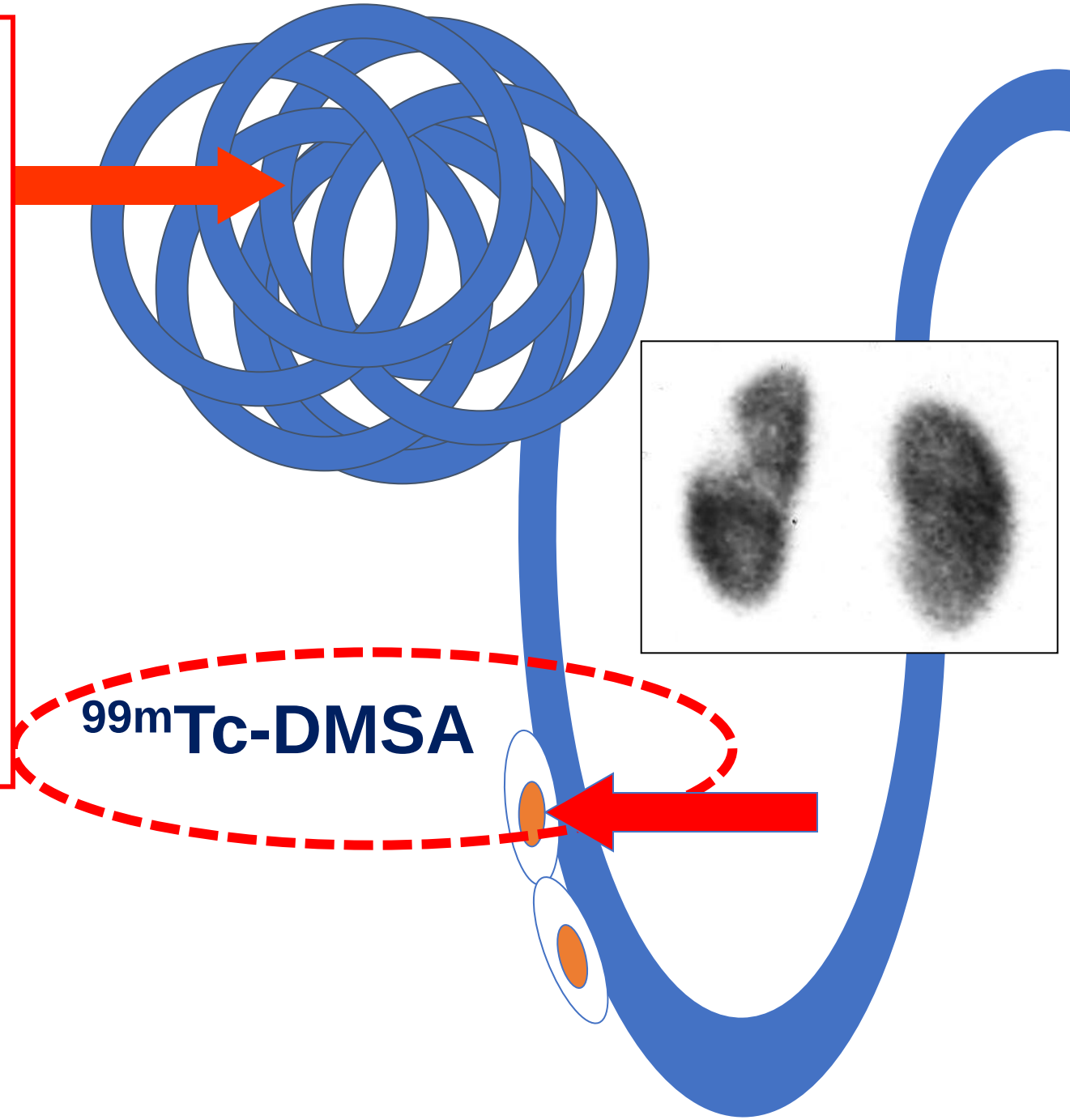

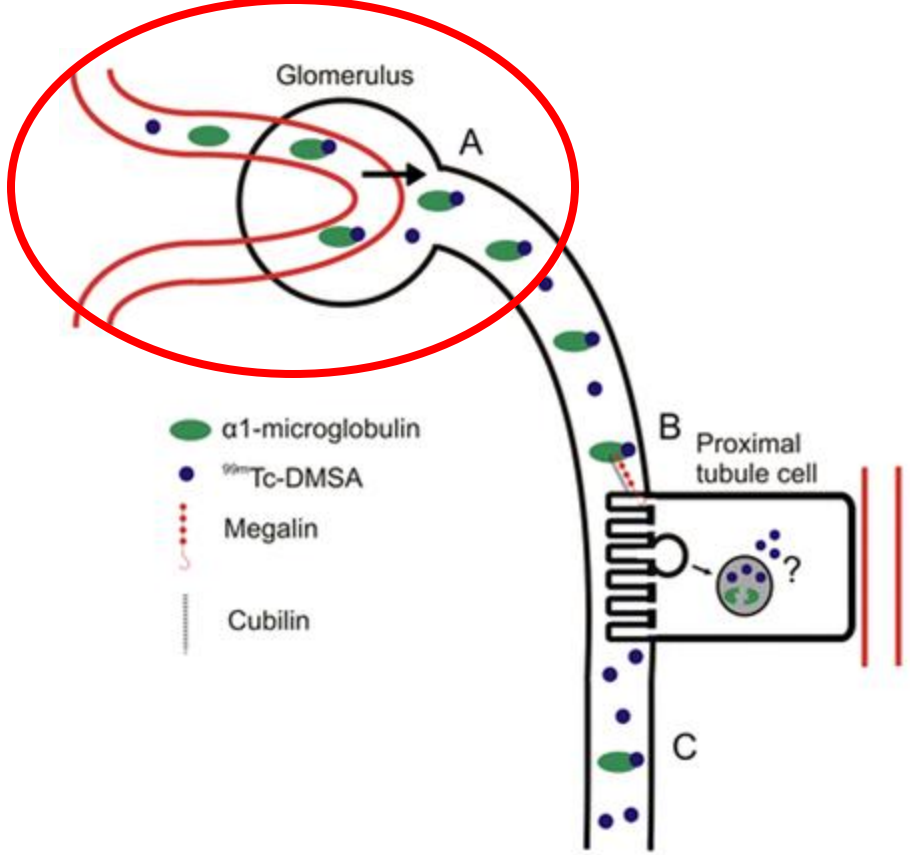

MECANISMO de CAPTACIÓN RENAL DE ^{99M}TC-DMSA:

A: α1-microglobulin–bound ^{99m}Tc-DMSA is freely **filtered by glomeruli**

B: accumulates in renal proximal tubules by endocytosis mediated by multiligand-binding **megalin/cubilin** receptors

C: Free ^{99m}Tc-DMSA and trace amounts of α1-microglobulin–bound ^{99m}Tc-DMSA are excreted in urine.

Renal Uptake of ^{99m}Tc-Dimercaptosuccinic Acid Is Dependent on Normal Proximal Tubule Receptor–Mediated Endocytosis

Kathrin Weyer[1], Rikke Nielsen[1], Steen V. Petersen[1], Erik I. Christensen[1], Michael Rehling[2], and Henrik Birn[1,3]

[1]*Department of Biomedicine, Aarhus University, Aarhus, Denmark;* [2]*Department of Clinical Physiology and Nuclear Medicine, Aarhus University Hospital, Aarhus, Denmark; and* [3]*Department of Nephrology, Aarhus University Hospital, Aarhus, Denmark*

J Nucl Med 2013; 54:159–165

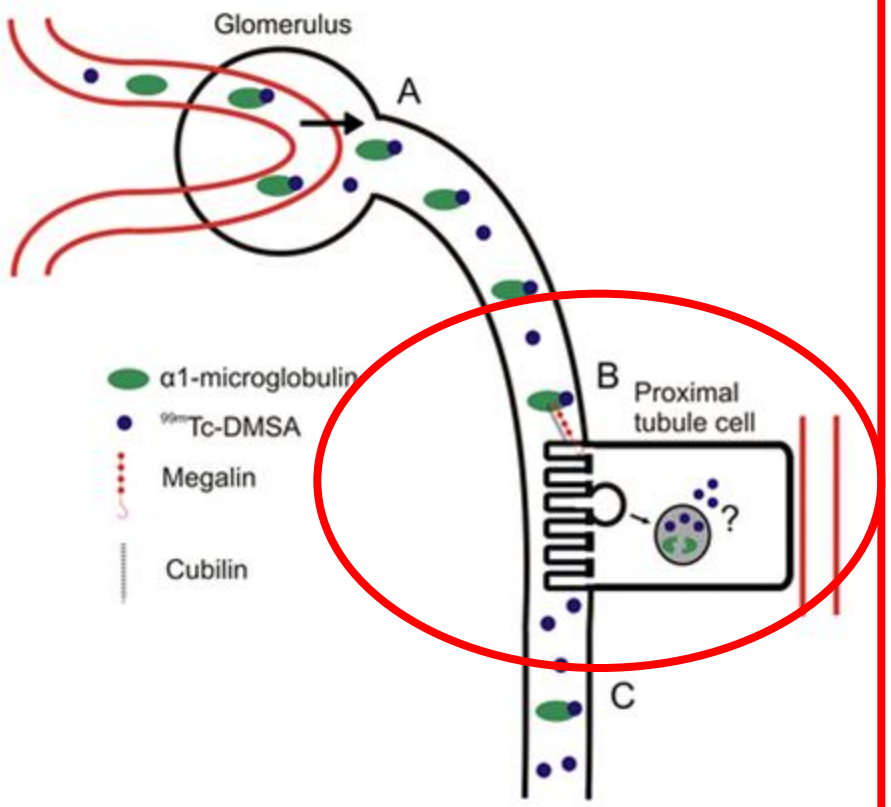

MECANISMO de CAPTACIÓN RENAL DE ^{99M}TC-DMSA:

A: α1-microglobulin–bound ^{99m}Tc-DMSA is freely **filtered by glomeruli**

B: accumulates in renal proximal tubules by endocytosis mediated by multiligand-binding **megalin/cubilin** receptors

C: Free ^{99m}Tc-DMSA and trace amounts of α1-microglobulin–bound ^{99m}Tc-DMSA are excreted in urine.

Renal Uptake of ^{99m}Tc-Dimercaptosuccinic Acid Is Dependent on Normal Proximal Tubule Receptor–Mediated Endocytosis

Kathrin Weyer[1], Rikke Nielsen[1], Steen V. Petersen[1], Erik I. Christensen[1], Michael Rehling[2], and Henrik Birn[1,3]

[1]Department of Biomedicine, Aarhus University, Aarhus, Denmark; [2]Department of Clinical Physiology and Nuclear Medicine, Aarhus University Hospital, Aarhus, Denmark; and [3]Department of Nephrology, Aarhus University Hospital, Aarhus, Denmark

J Nucl Med 2013; 54:159–165

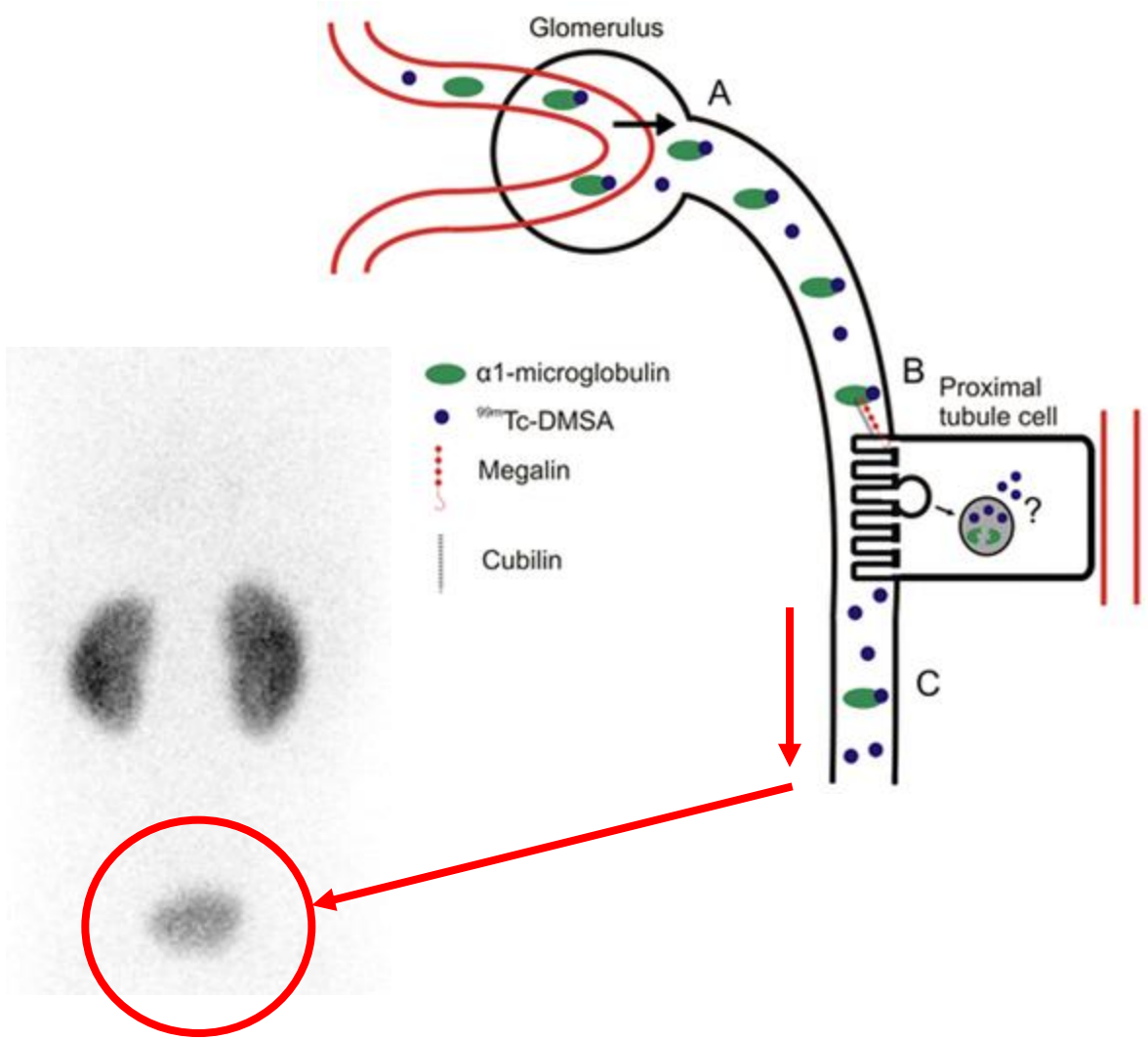

MECANISMO de CAPTACIÓN RENAL DE ^{99M}TC-DMSA:

A: α1-microglobulin–bound ^{99m}Tc-DMSA is freely **filtered by glomeruli**

B: accumulates in renal proximal tubules by endocytosis mediated by multiligand-binding **megalin/cubilin** receptors

C: Free ^{99m}Tc-DMSA and trace amounts of α1-microglobulin–bound ^{99m}Tc-DMSA are excreted in urine.

Renal Uptake of ^{99m}Tc-Dimercaptosuccinic Acid Is Dependent on Normal Proximal Tubule Receptor–Mediated Endocytosis

Kathrin Weyer[1], Rikke Nielsen[1], Steen V. Petersen[1], Erik I. Christensen[1], Michael Rehling[2], and Henrik Birn[1,3]

[1]Department of Biomedicine, Aarhus University, Aarhus, Denmark; [2]Department of Clinical Physiology and Nuclear Medicine, Aarhus University Hospital, Aarhus, Denmark; and [3]Department of Nephrology, Aarhus University Hospital, Aarhus, Denmark

J Nucl Med 2013; 54:159–165

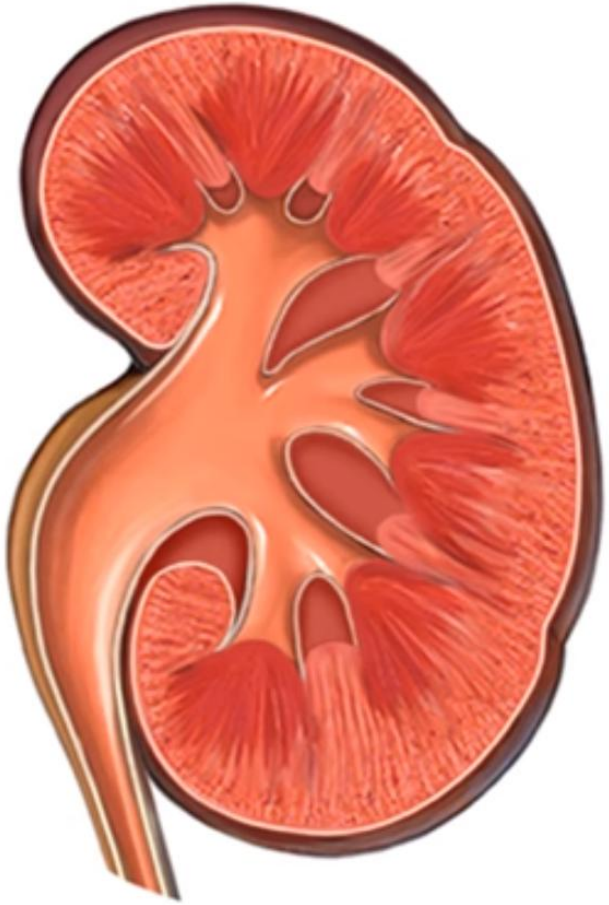

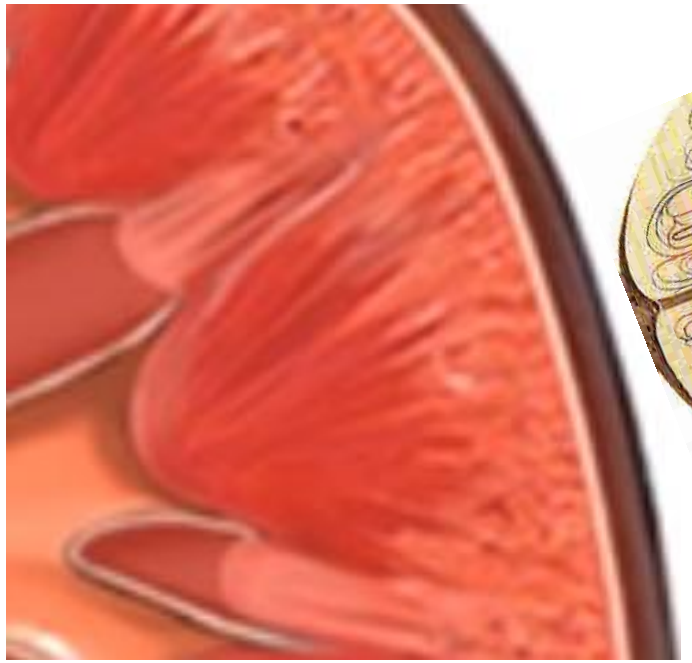

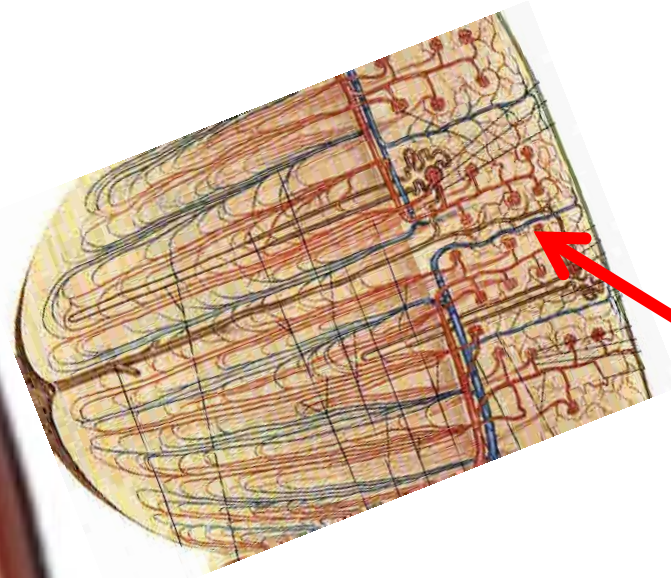

DMSA

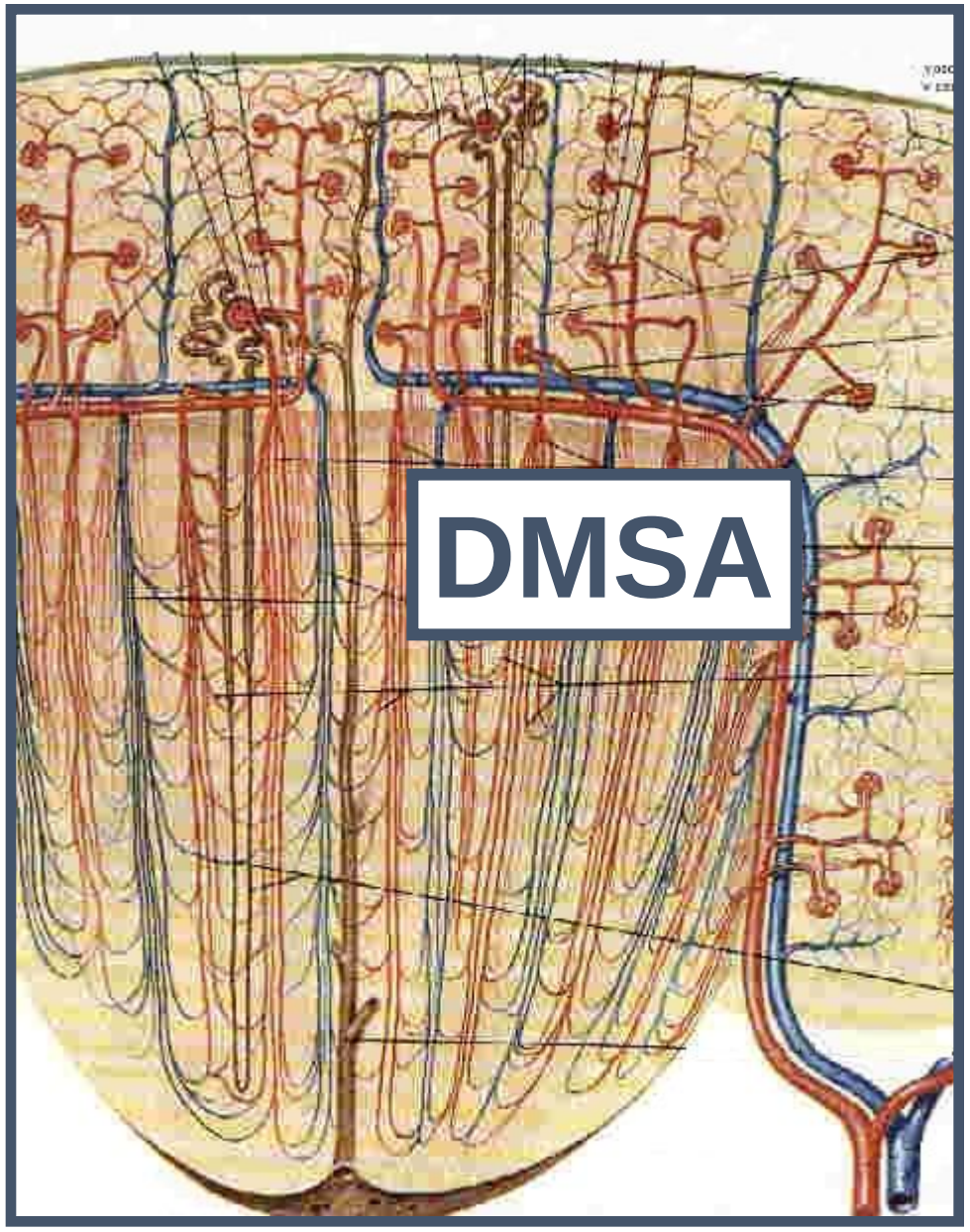

- MAYOR GROSOR, MAS CAPTACIÓN
- Menor grosor y captación en polos y alrededor de la pelvis renal
- Columnas de Bertin
- Banda captante en duplicidad

PIELONEFRITIS AGUDA

DIAGNOSTICO → **CLINICO**

PIELONEFRITIS AGUDA

DIAGNOSTICO → **CLINICO**

TÉCNICAS DE IMAGEN

- ECOGRAFÍA
- CT
- RM
- UIV

- GAMMAGRAFIA RENAL DMSA

→ TÉCNICA DE REFERENCIA

ECOGRAFÍA en la PIELONEFRITIS AGUDA

< 20 % anormal

- Aumento del tamaño renal
- Ecogenicidad anormal
- Dilatación del Sistema excretor

ECOGRAFÍA
en la
PIELONEFRITIS AGUDA

< 20 % anormal

- Aumento del tamaño renal
- Ecogenicidad anormal
- Dilatación del Sistema excretor

UNA **ECOGRAFÍA NORMAL**
NO EXCLUYE UNA **PNA** !

ECOGRAFÍA en la PIELONEFRITIS AGUDA

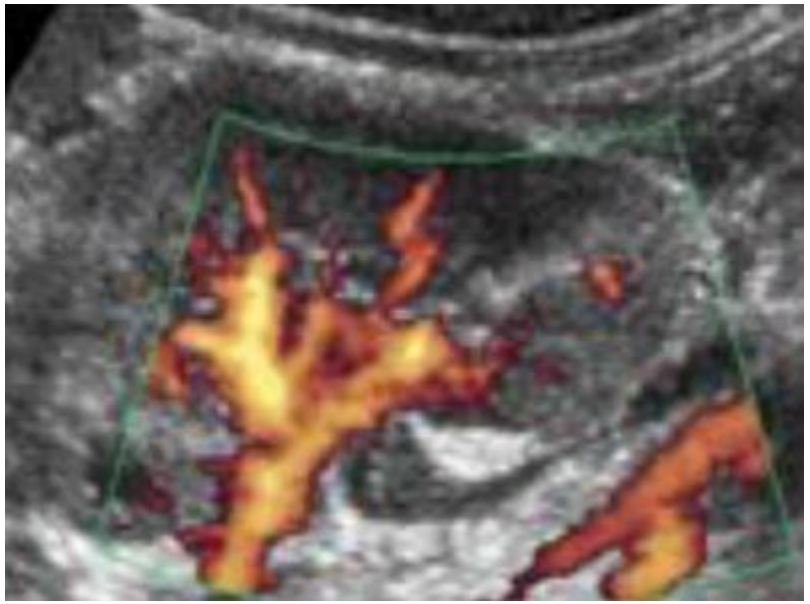

< 20 % anormal

- Aumento del tamaño renal
- Ecogenicidad anormal
- Dilatación del Sistema excretor

LA **ECOGRAFÍA DOPPLER** AUMENTA LA SENSIBILIDAD

Radiology, January 2001



Experimental Studies

Massoud Majd

Anna R. Nussbaum Blask, MD
Bruce M. Markle, MD
Eglal Shalaby-Rana, MD
Hans G. Pohl, MD
Jae-Shin Park, MD
Roma Chandra, MD
Khodayar Rais-Bahrami, MD
Nayan Pandya, CNMT
Kantilal M. Patel, PhD
H. Gil Rushton, MD

Acute Pyelonephritis: Comparison of Diagnosis with ^{99m}Tc-DMSA SPECT, Spiral CT, MR Imaging, and Power Doppler US in an Experimental Pig Model[1]

DATOS EXPERIMENTARES EN ANIMALES

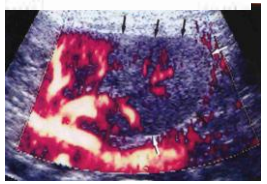

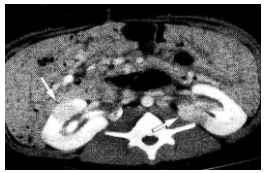

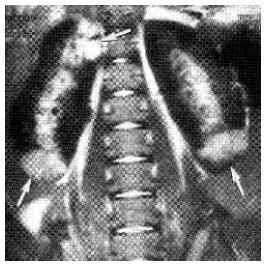

	SENSIB	ESPECIF
DMSA	92.1	93.8
US	74.3	56.7
CT	86.8	87.5
MR	89.5	87.5

Acute pyelonephritis: comparison of diagnosis with 99mTc-DMSA, SPECT, spiral CT, MR imaging, and power Doppler US in an experimental pig model
Majd M et al
Radiology. 2001 Jan;218(1):101-8

Rushton HG,Majd M et al *J. Urol 140: 1169 – 1174, 1988*
Parkhouse HG, Godley ML et al *Nucl Med Commun 10: 63 - 70, 1989*
Rossleigh MA, Farnsworth RH et al *J Nucl Med 39: 1280 – 1285, 1998*
Farhat W. et al *J Urol 2002, 168(3):1114-17*

PIELONEFRITIS AGUDA
Seguimiento y detección de secuelas

DMSA a los 6 - 12 meses de la fase aguda diferentes series

- 50-80 % de las áreas corticales hipoactive han mejorado o se han normalizado
- Cicatrices corticales:
  - Más severas en caso de RVU grado III o superior
  - Más frecuentes en caso de multifocalidad

Patofisiología de la PNA

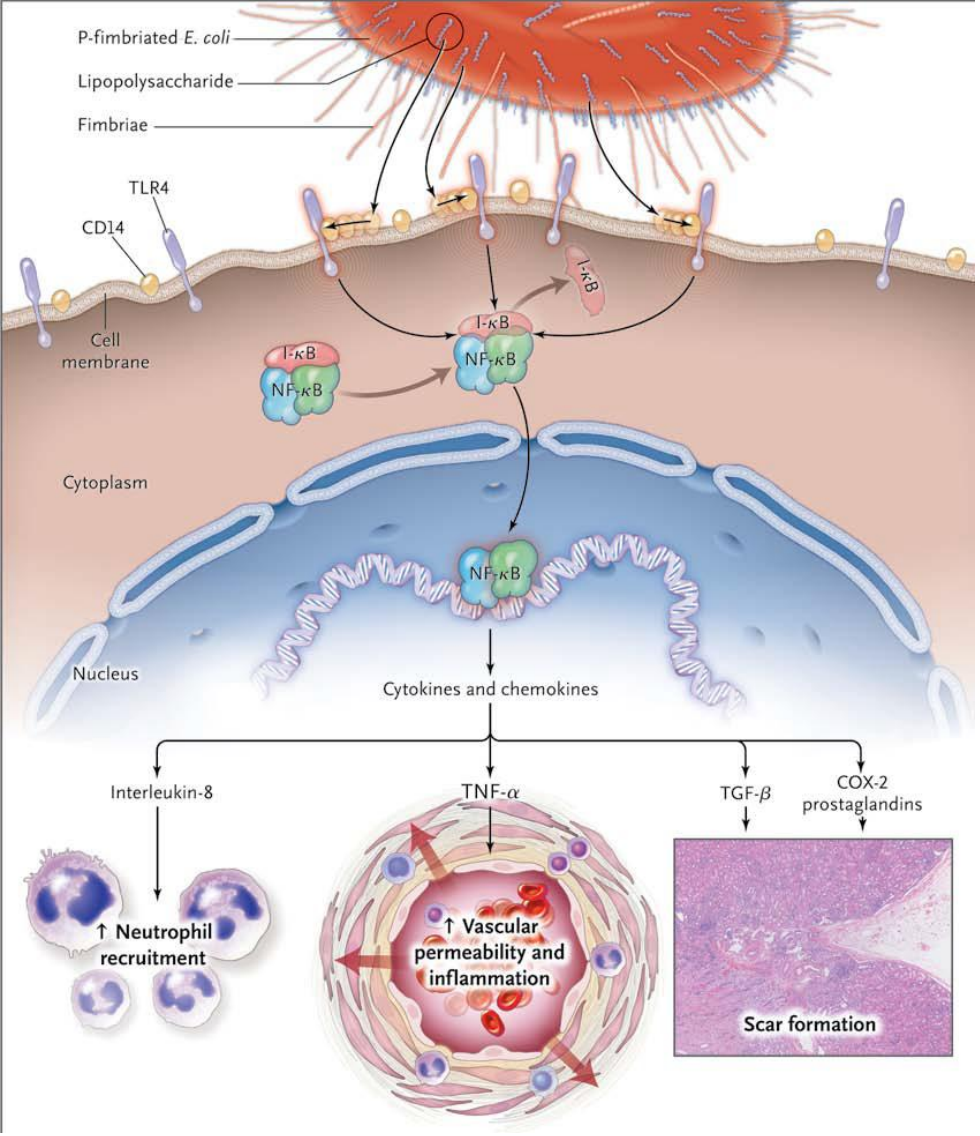

- **EDEMA**
- **INFLAMACION**
- **INFECCION**
- **VASCULAR**
  - **INFARTO**
  - **TROMBO**

Febrile urinary tract infections in children.
Montini G, **Tullus** K, Hewitt I.
N Engl J Med. 2011 Jul 21;365(3):239-50

PNA + RVU



PNA

+6m

PNA + RVU

Secuelas

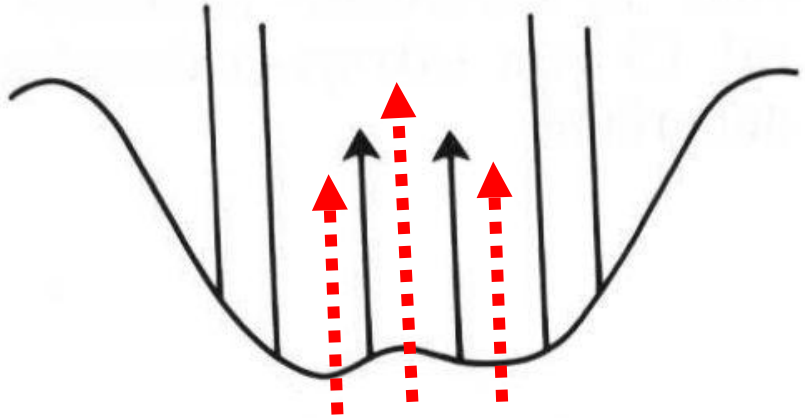

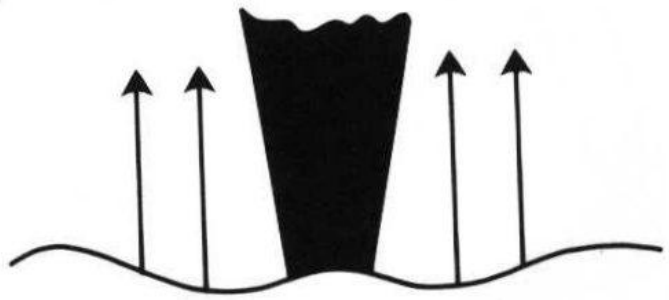

PNA

DIFERENTES IMAGENES DURANTE LA FASE AGUDA

Unilateral

Multifocal

Multifocal

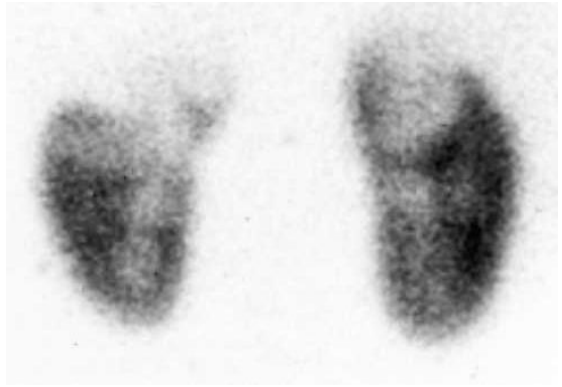

bilateral

Multifocal

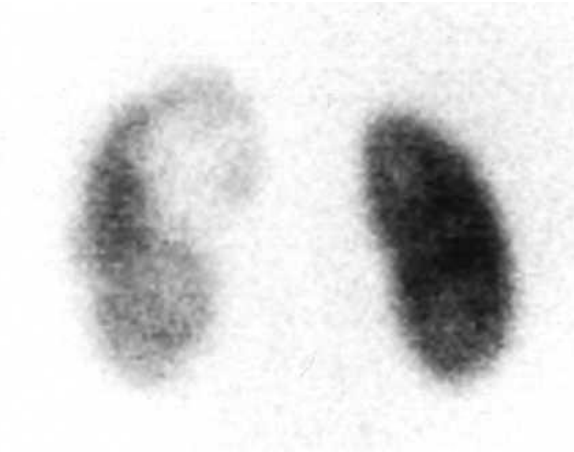

RVU

< funcion

Pielonefritis Aguda

Infección Febril del Tracto Urinario → **DMSA+ PNA** → ≈60% Defectos de captación corticales → ≈10-40% cicatrices permanentes

La gammagrafía renal cortical con DMSA permite diferenciar la infección urinaria alta (PNA) y baja (cistitis).
En caso de PNA es útil para el DIAGNÓSTICO e informe de parámetros de severidad.

Esta información clínica se tiene que evaluar en el contexto de las recomendaciones actuales de las guías clínicas.

PNA

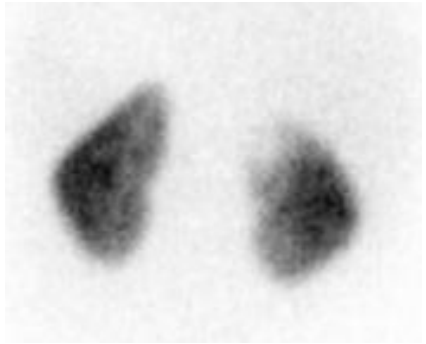

Unifocal

Multifocal

Bilateral duplicidad renal

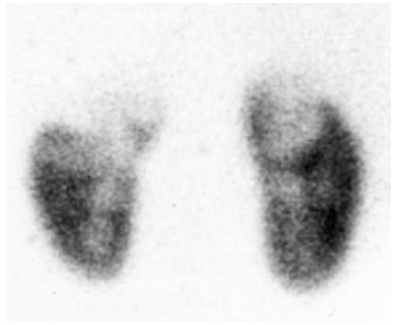

Multifocal bilateral

PNA

Megaureter Bilateral Congenito

Baja función renal

^{99m}Tc-DMSA INDICACIONES

PIELO NEFRITIS

- **AGUDA**
  - ≈60% defectos captación
    - ≈10-40% Lesiones permanentes
- **CICATRIZ RENAL**
  - Seguimiento

OTRAS INDICACIONES

- DEFECTOS FOCALES CORTICALES
- RIÑÓN ECTÓPICO
- SOSPECHA DUPLICIDAD RENAL
  - Con/sin drenaje ectópico
- FUNCIÓN SI/NO
  - Riñón multiquístico

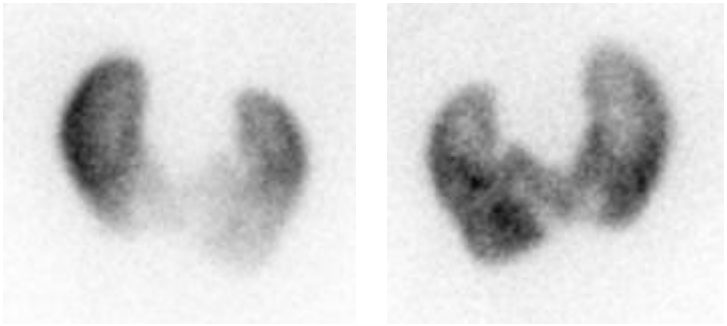

Riñón en herradura

^{99m}Tc-DMSA INDICACIONES

PIELO NEFRITIS

- **AGUDA**
  - ≈60% defectos captación
    - ≈10-40% Lesiones permanentes
- **CICATRIZ RENAL**
  - Seguimiento

OTRAS INDICACIONES

- DEFECTOS FOCALES CORTICALES
- RIÑÓN ECTÓPICO
- SOSPECHA DUPLICIDAD RENAL
  - Con/sin drenaje ectópico
- FUNCIÓN SI/NO
  - Riñón multiquístico

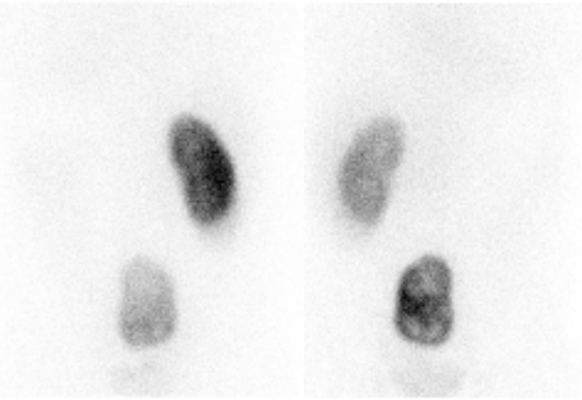

Ectopia renal

Riñón pélvico

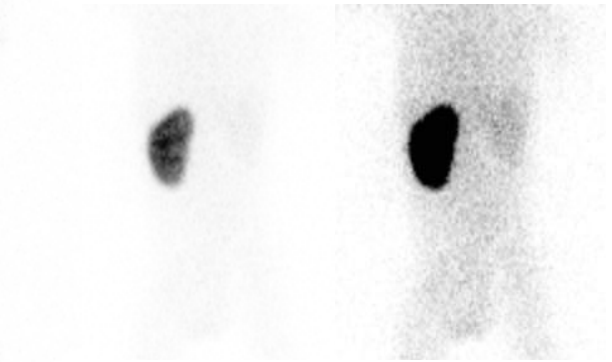

Agenesia renal

^{99m}Tc-DMSA INDICACIONES

PIELO NEFRITIS

- **AGUDA**
  - ≈60% defectos captación
    - ≈10-40% Lesiones permanentes
- **CICATRIZ RENAL**
  - Seguimiento

OTRAS INDICACIONES

- DEFECTOS FOCALES CORTICALES
- RIÑÓN ECTÓPICO
- SOSPECHA DUPLICIDAD RENAL
  - Con/sin drenaje ectópico
- FUNCIÓN SI/NO
  - Riñón multiquístico

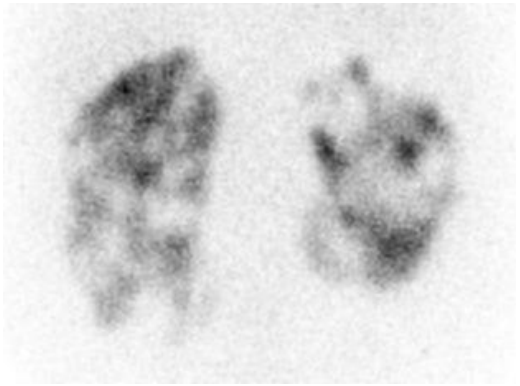

Poliquistosis renal

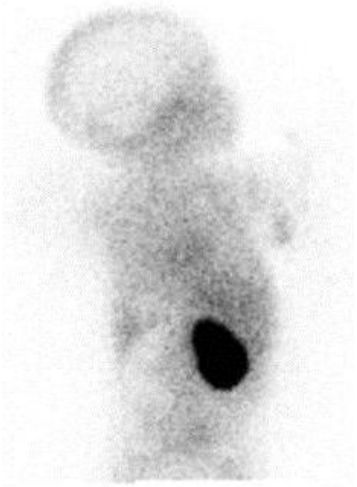

Riñón Multiquistico

- Gammagrafía cortical renal con ^{99m}Tc-DMSA
- Cistogammagrafía
- ITU y RVU
- Guias Clínicas – Indicaciones actuales
- Qué hay de nuevo? – Líneas de futuro

Cistogammagrafía Directa

Cistogammagrafía Indirecta

- DRC
  DIRECT
  RADIONUCLIDE
  CYSTOGRAPHY



- IRC
  INDIRECT
  RADIONUCLIDE
  CYSTOGRAPHY

CISTOGAMMAGRAFÍA DIRECTA



Misma técnica que la CUMS radiológica

- Catéter vesical
- Tratamiento AB 48 h
- Llenado vesical con SSF
- Altura del SSF para llenado vesical: 60 cm
- Estudiar una o dos micciones
- radiofármaco:
  - 1 mCi ^{99m}Tc-sulfuro coloidal

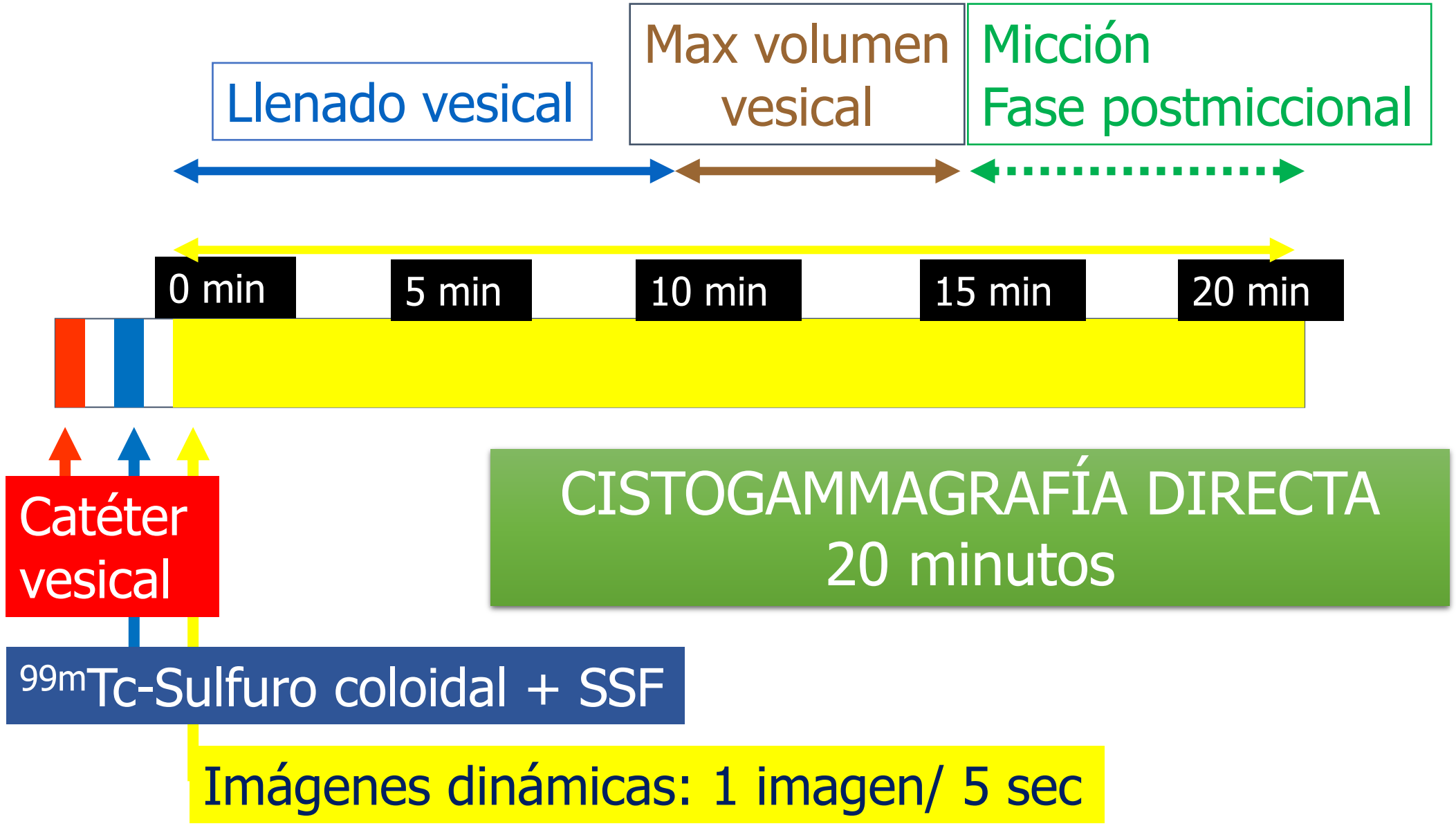
Llenado vesical
Max volumen vesical
Micción
Fase postmiccional
0 min
5 min
10 min
15 min
20 min
Catéter vesical
CISTOGAMMAGRAFÍA DIRECTA
20 minutos
99mTc-Sulfuro coloidal + SSF
Imágenes dinámicas: 1 imagen/ 5 sec

CISTOGAMMAGRAFÍA DIRECTA



- MINIMA DOSIMETRIA
- ALTA SENSIBILIDAD

pero
- CATETER VESICAL

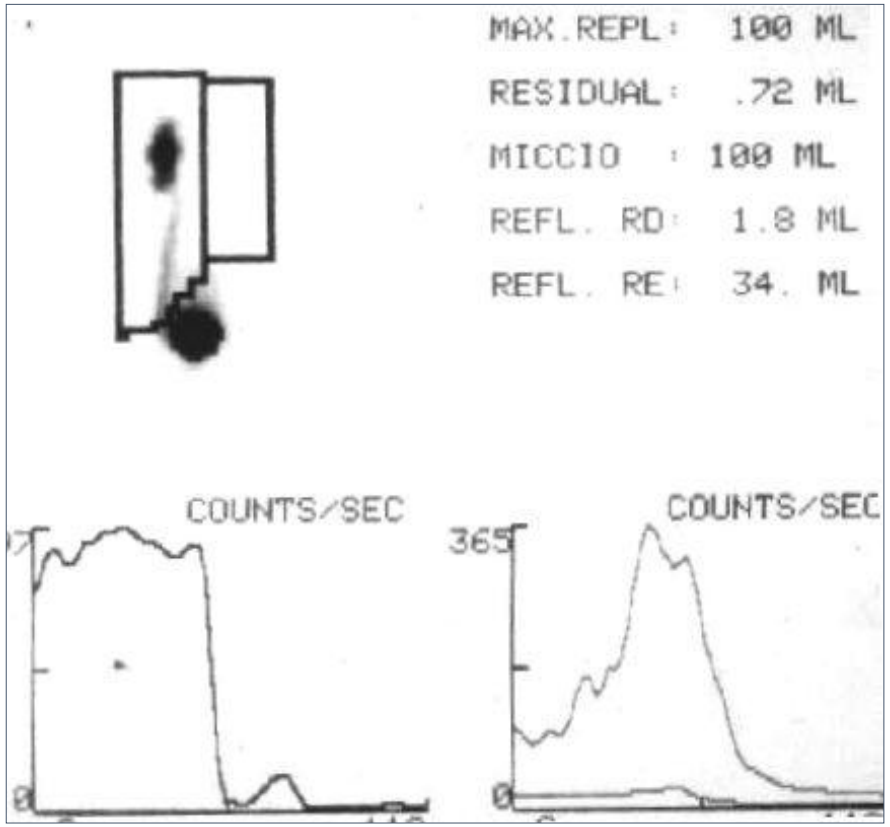

Cuantificación:
- Tiempo total con reflujo
- Volumen del reflujo
- Numero de episodios de reflujo

- Reflujos cíclicos: vejiga neurógena
- Reflujo miccional o premiccional

CUMS
CISTOURETRIGRAFÍA MICCIONAL SERIADA

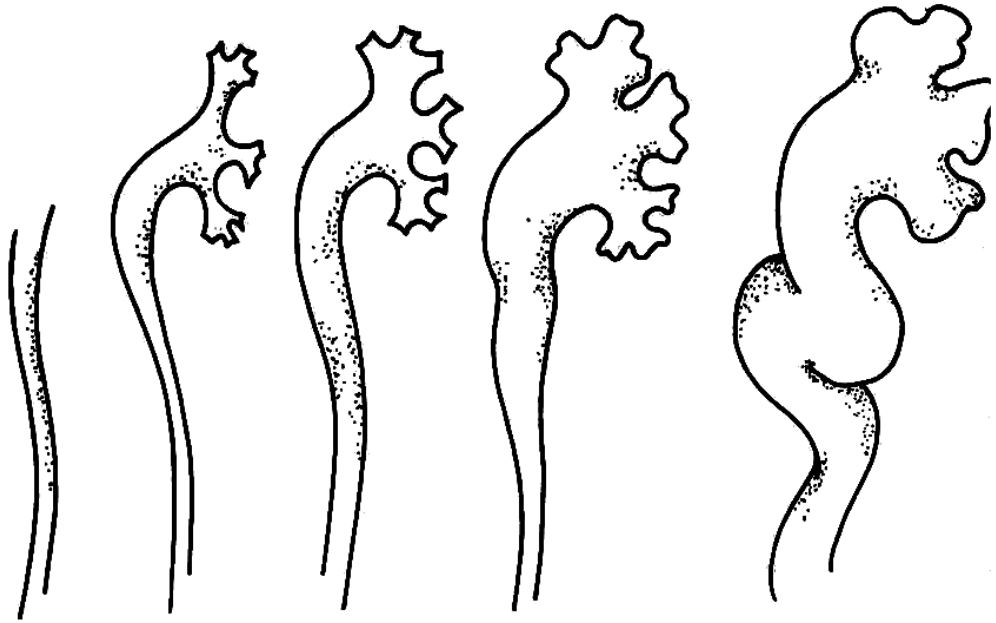

- Grados de reflujo
  - Ureteral …. Renal
  - Dilatacion …. No dilatacion
  - Reflujo Intrarenal

CISTOGAMMAGRAFÍA DIRECTA

Cuantificación:
- Tiempo total con reflujo
- Volumen del reflujo
- Numero de episodios de reflujo

- Reflujos cíclicos: vejiga neurógena
- Reflujo miccional o premiccional

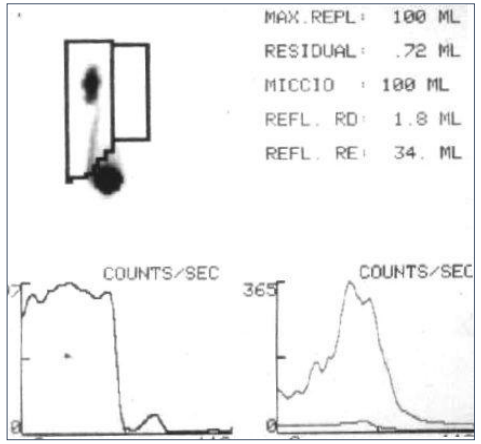

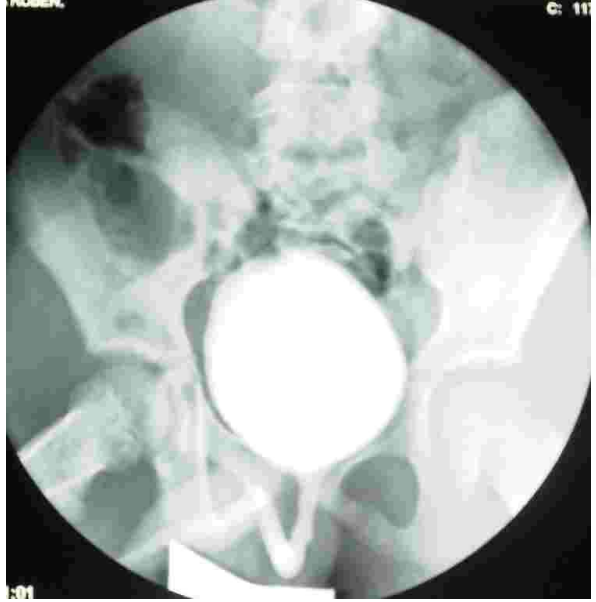

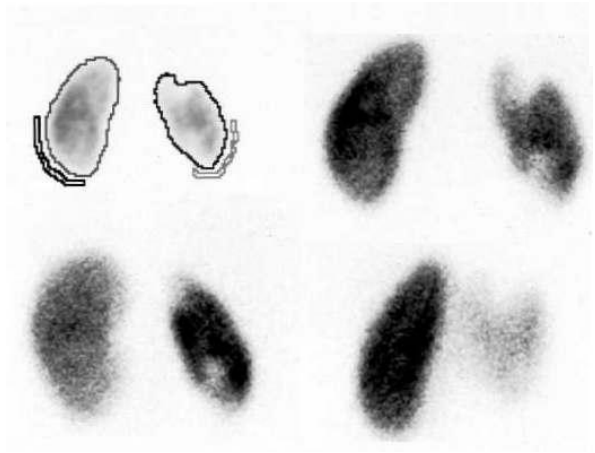

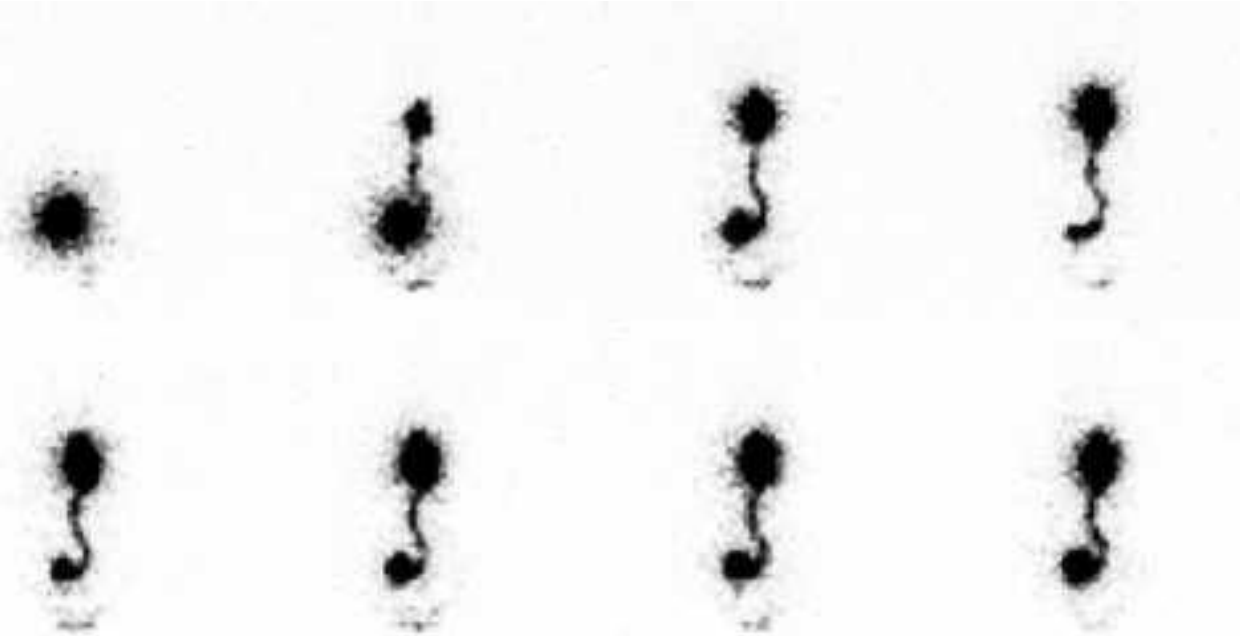

CISTOGAMAGRAFÍA DIRECTA

17 % discordancias con CUMS

sensibilidad CGD > CUMS

- DRC
  DIRECT
  RADIONUCLIDE
  CYSTOGRAPHY



- IRC
  INDIRECT
  RADIONUCLIDE
  CYSTOGRAPHY

CISTOGAMMAGRAFÍA INDIRECTA

1- hidratación oral previa + furosemida
2- renograma MAG3 20 min

3- cistografía

→ MAG_3 → función renal diferencial

→ CISTO → RVU

NIÑOS > 4-5 AÑOS

CON CONTROL DE ESFÍNTER VESICAL

CISTOGAMMAGRAFÍA INDIRECTA

1- hidratación oral previa + furosemida
2- renograma MAG3 20 min

3- cistografía

→ MAG_3 → función renal diferencial

→ CISTO → RVU

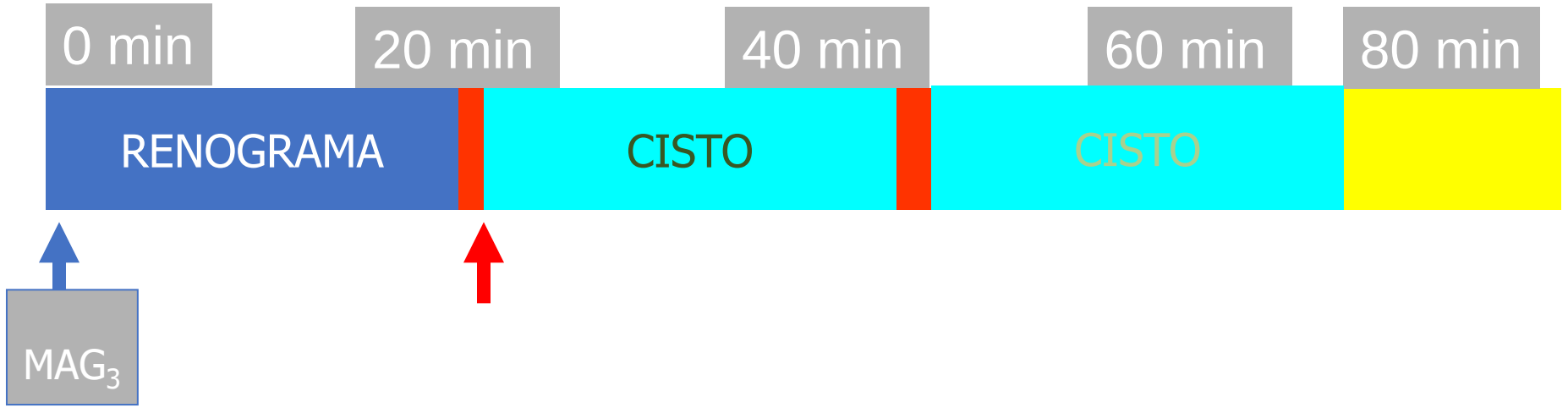

LACTANTES
NIÑOS SIN CONTROL DE ESFÍNTER

CISTOGAMMAGRAFÍA INDIRECTA

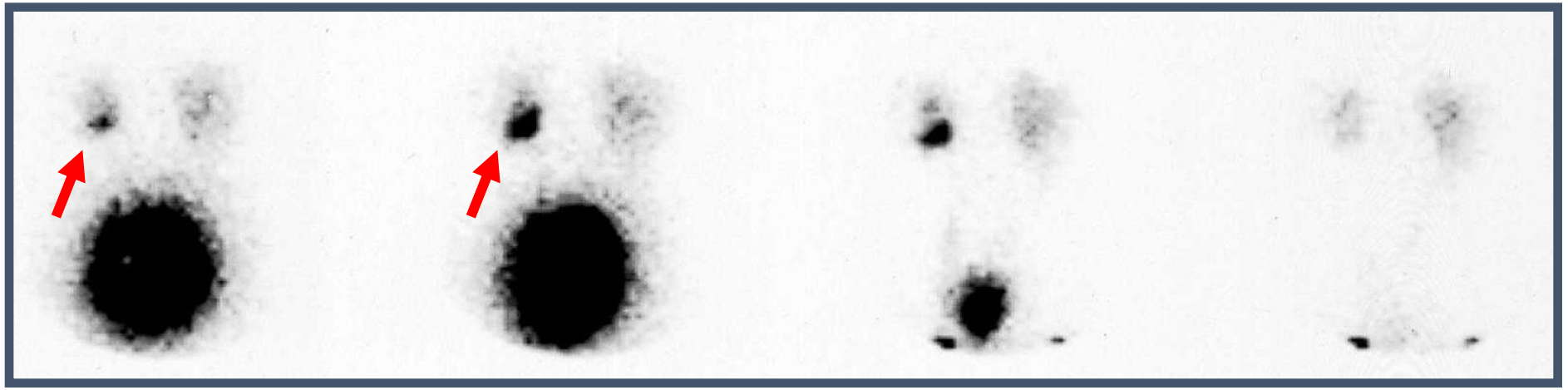

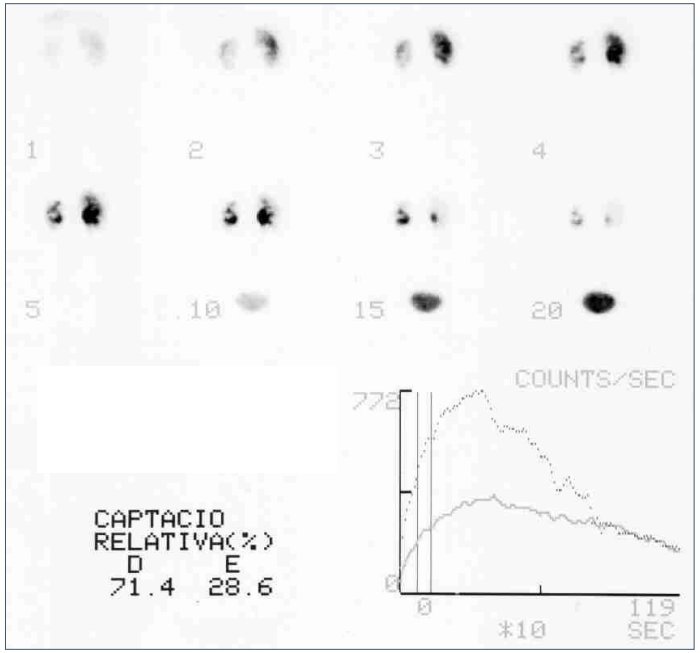

- Solo detecta RVU grado 3 o superior
  - RVU III-IV-V
- NO CATETER VESICAL
- % FUNCION RENAL DIFERENCIAL

- BAJA DOSIMETRIA

COMPARACION CUMS - CGD – CGI

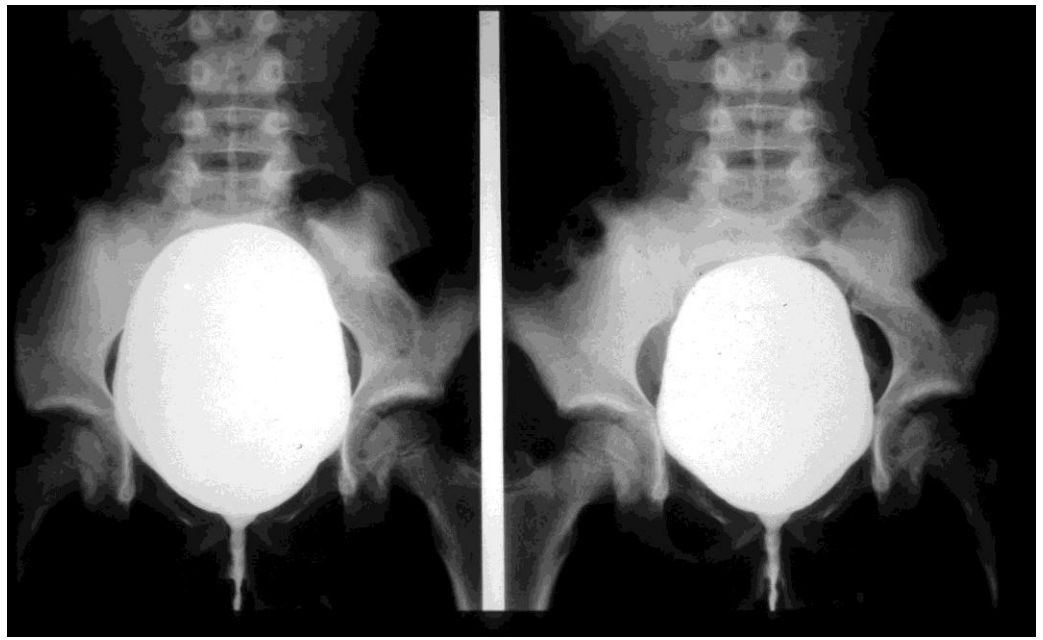

Sensibilidad para la detección de reflujo

- CGD > CUMS > CGI

Sensibilidad para RVU grado III, IV o V

- CGD = CUMS = CGI

Detección de RVU grado I o II

- solo CUMS

CUMS vs CGD

DISCORDANCIA:
CUMS: no RVU
CGD: RVU a RI

COMPARACION CUMS - CGD – CGI

CUMS
- Técnica de referencia
- Morfologia (valvas, vejiga)
- Alta dosimetría >>>>> GCI > CGD (x200)

CISTOGAMMAGRAFIA DIRECTA O INDIRECTA
- Criterios de severidad?
  - Tiempo de persistencia de reflujo
  - Numero de episodios de RVU
- CG indirecta:
  - no cateter
  - detecta RVU significativo >III

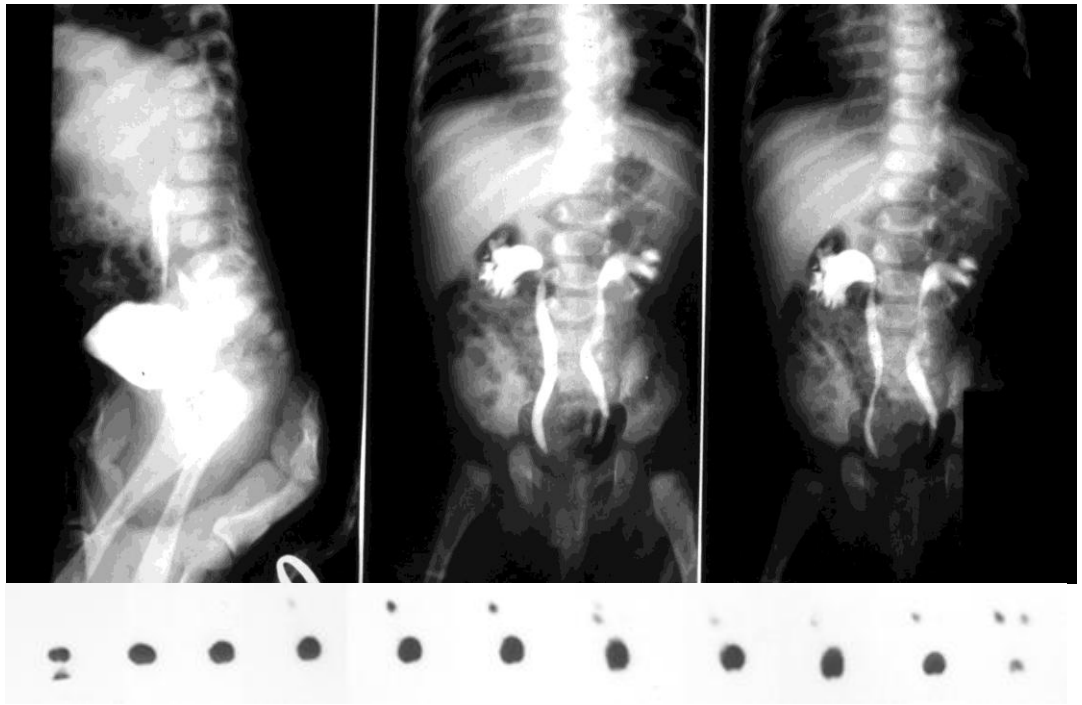

CUMS vs CGD

Coincidente:

RVU bilateral, III

Valor añadido CGD:

RD: solo RVU miccional

RI: RVU persistente >20min

DETECCIÓN DE REFLUJO CUMS - CGD

		VCUG	DRC
Dikshit	1993	87%	= 96%
Merrick	1995	47%	< 78%
Polito	2000	55%	< 94%
McLaren	2001	43%	< 91%
Unver	2006	85%	= 69%
Promedio		**63%**	**< 86%**

- Gammagrafía cortical renal con ^{99m}Tc-DMSA
- Cistogammagrafía
- ITU y RVU
- Guias Clínicas – Indicaciones actuales
- Qué hay de nuevo? – Líneas de futuro

Prospective trial of operative versus non-operative treatment of severe vesicoureteric reflux in children: five years' observation

BIRMINGHAM REFLUX STUDY GROUP

surgery	ureter reimplanted
reflux abolished:	98%
no surgery	
severe reflux at 5 y	>50%
progression scaring	
at all ages	
more frequent	first 2y observation
	2-7 y at allocation

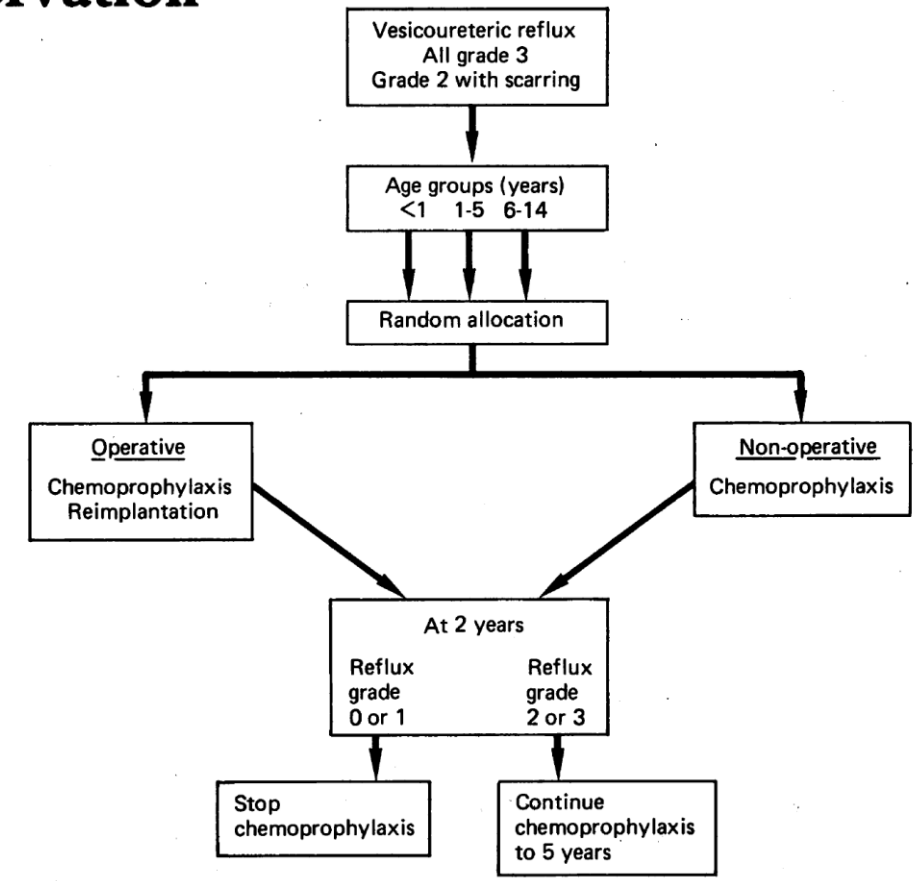

Prospective trial of operative versus non-operative treatment of severe vesicoureteric reflux in children: five years' observation. Birmingham Reflux Study Group
Br Med J (Clin Res Ed). 1987 Jul 25;295(6592):237-41

A prospective trial of operative versus non-operative treatment of severe vesico-ureteric reflux: 2 years' observation in 96 children.
The Birmingham Reflux Study Group
Contrib Nephrol. 1984;39:169-85

Gammagrafia renal DMSA

- fase aguda
- 6-12 m despues de ITU-f
- fase aguda + control

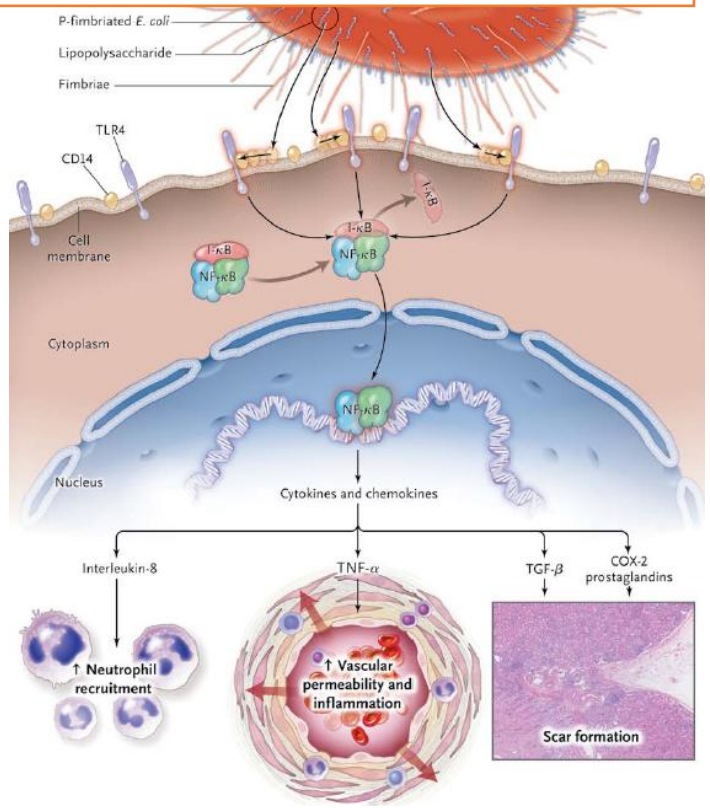

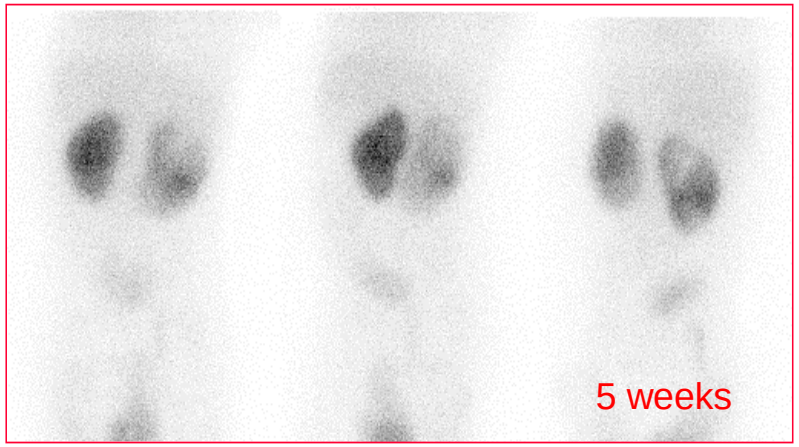

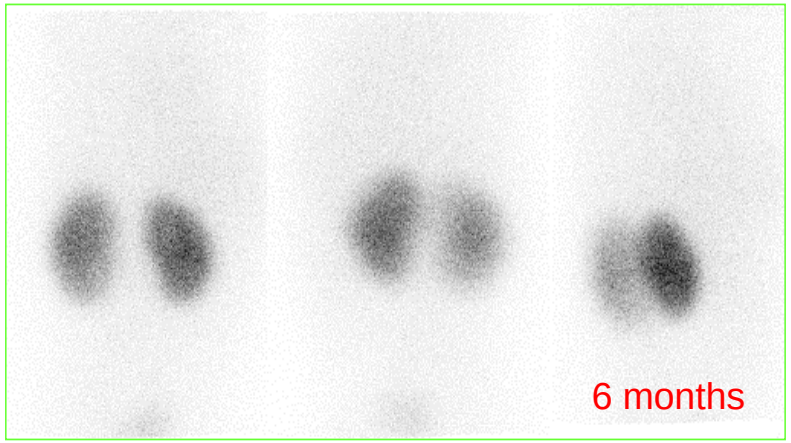

RVU>=III y ITU-f

- mayor % PNA
- mayor % secuelas

Febrile urinary tract infections in children.
Montini G, **Tullus** K, Hewitt I.
N Engl J Med. 2011 Jul 21;365(3):239-50

Gammagrafia renal DMSA

- fase aguda
- 6-12 m despues de ITU-f
- fase aguda + control

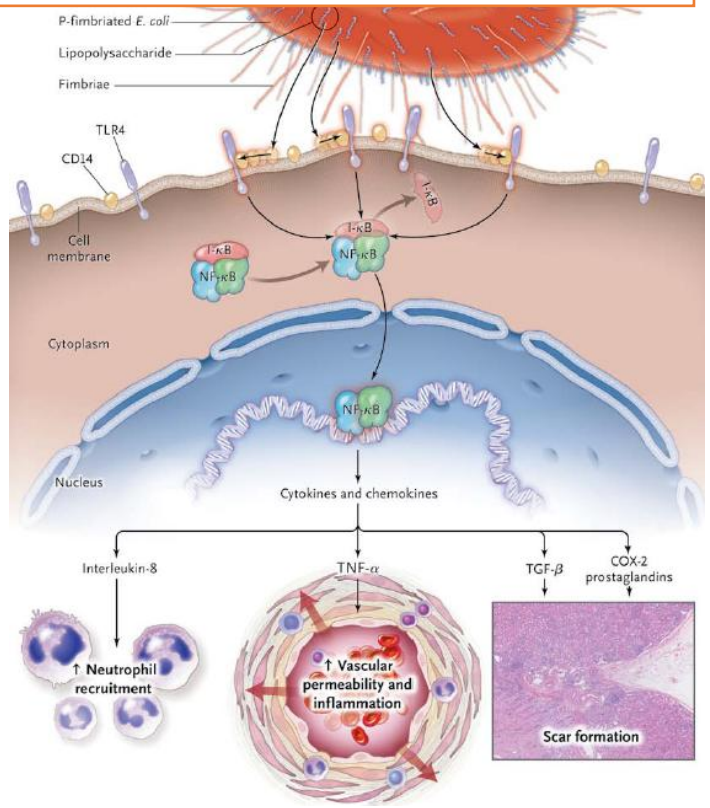

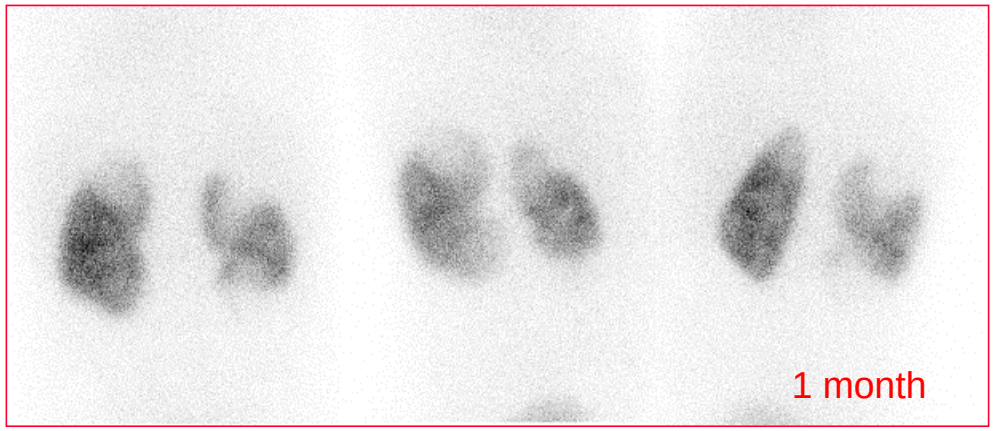

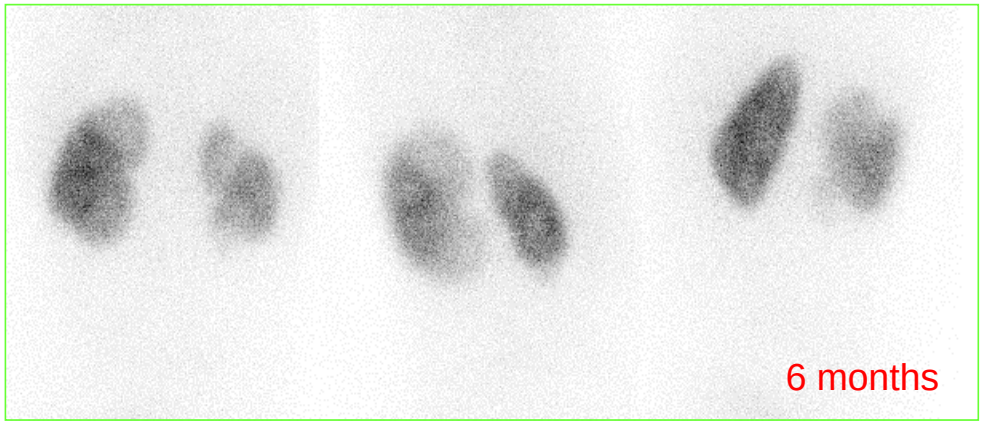

RVU>=III y ITU-f

- mayor % PNA
- mayor % secuelas

Febrile urinary tract infections in children.
Montini G, **Tullus** K, Hewitt I.
N Engl J Med. 2011 Jul 21;365(3):239-50

DISPLASIA RENAL CONGÉNITA Y REFLUJO

Muchas lesiones corticales diagnosticades como secundarias a reflujo son de hecho zones de displàsia congénita

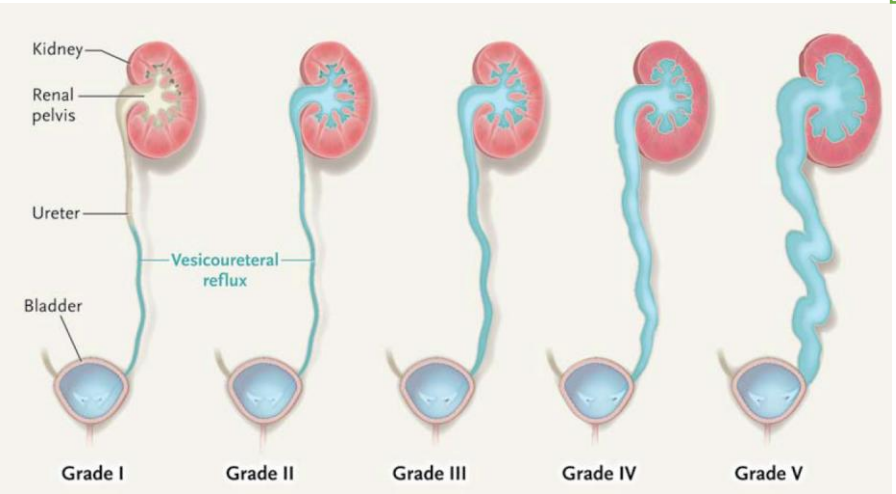

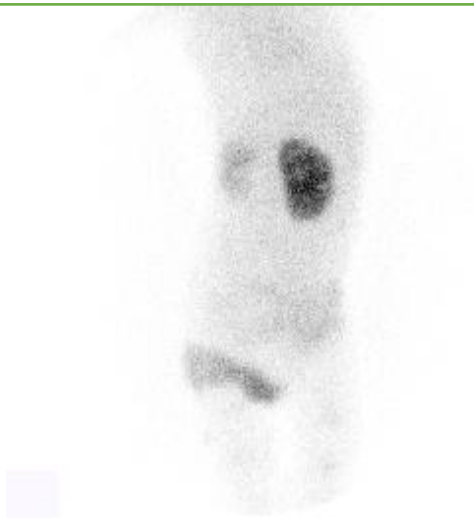

Febrile urinary tract infections in children.
Montini G, **Tullus** K, Hewitt I.
N Engl J Med. 2011 Jul 21;365(3):239-50

INCIDENCIA DE PNA EN LAS ITU-f

65% Goldraich Ped Neph 1995 (Review)

51% Preda J Pediatric 2007 (<1yr)
70% Tseng J Pediatric 2007 (<2yr)
51% Hansson J Urol 2004 (<2yr)
80% Ataei Pediatr Nephrol 2005 (>5yr)
61% Vanderfoille Ped Neph 1998 (>5yr)
63% Benador Lancet 1997 (0-16yrs)

DIAGNÓSTICO DE PNA
CLÍNICA vs IMAGEN

Clinical diagnosis:

- False positive 50%
- False negative 33%

Imaging diagnosis:

- Accuracy rates exceed 90%
- using DMSA planar/pinhole or SPECT techniques
- with very high inter-observer agreement.

Majd M, Rushton HG
Renal cortical scintigraphy in the diagnosis of acute pyelonephritis
Semin Nucl Med. 1992 Apr;22(2):93-111

TRATAMIENTO DE LA PNA

- Las cicatrices renals post PNA son más frecuentes si hay retraso en el diagnóstico y tratamiento

- Se ha publicado que hay equivalencia de resultados entre diferentes tipos de tratamiento antibiotico
  - Solo oral
  - IV y después oral
  - Solo IV

  Pero estos datos se basan en el diagnóstico final clinic y bacteriologico pero no con control de imagen de DMSA

Cochrane Review 2008

Relación entre PNA y primera ITU-f

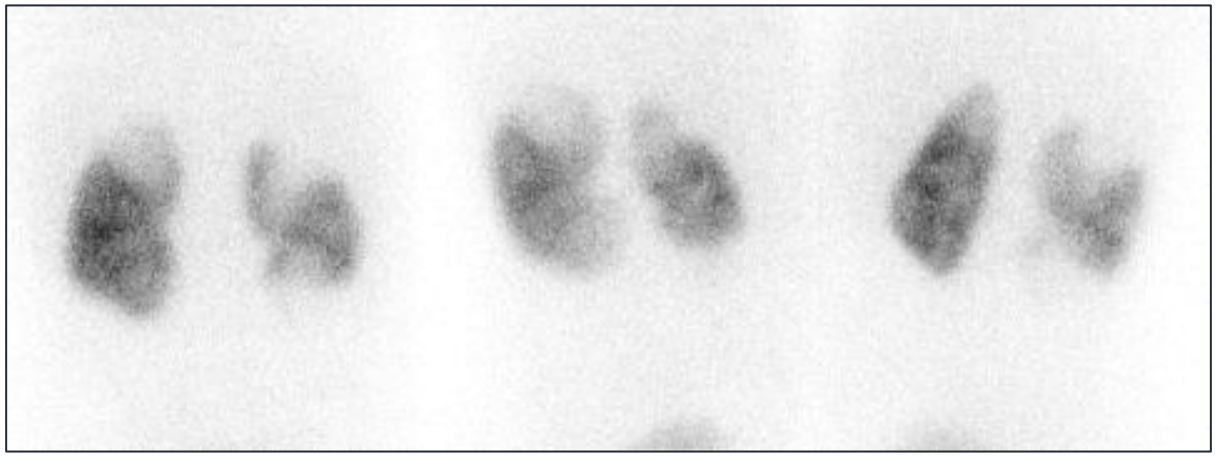

- Las ITU-f sob 2-3 veces más frecuentes en niños varones < 6 meses
- **La mayor incidencia de ITU-f es durante el primer año de vida**

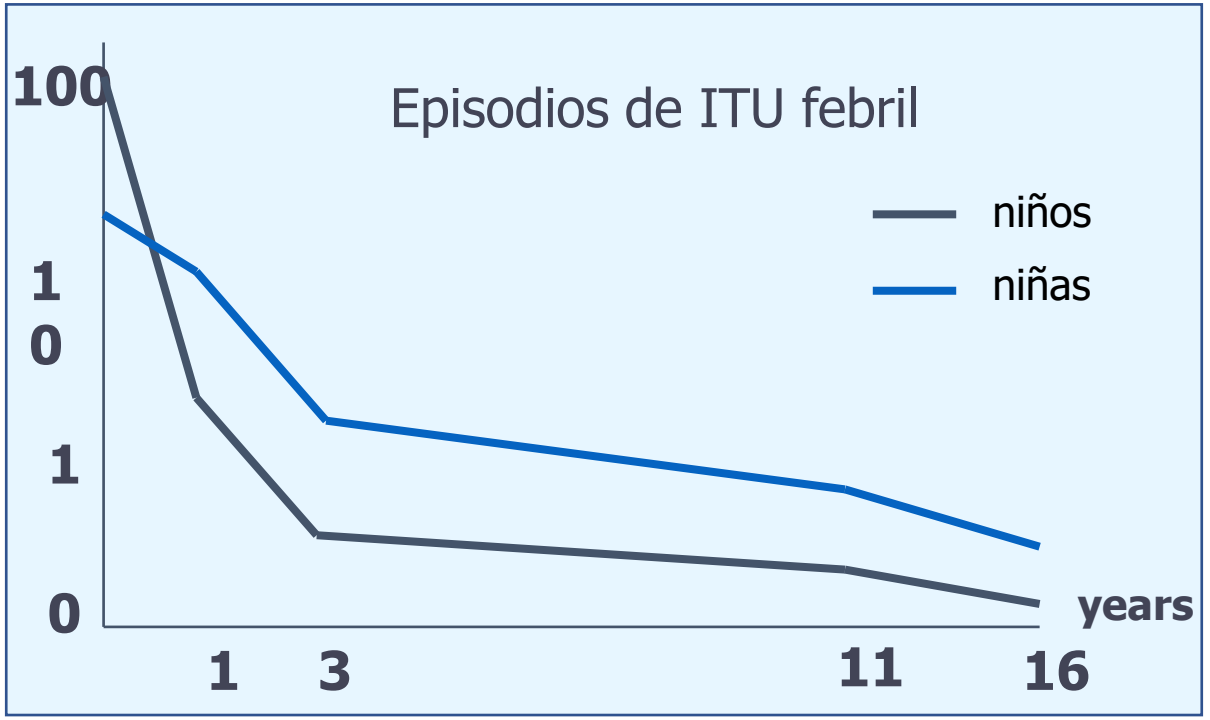

Winberg J, Bergström T, Jacobsson B.
Morbidity, age and sex distribution, recurrences and renal scarring in symptomatic urinary tract infection in childhood.
Kidney Int Suppl. 1975 Aug;4:S101-6.

PNA
Cicatrices renales y Número de episodios de PNA

También en los 80 se describió la relación entre % de cicatrices renales y el número de episodios de PNA

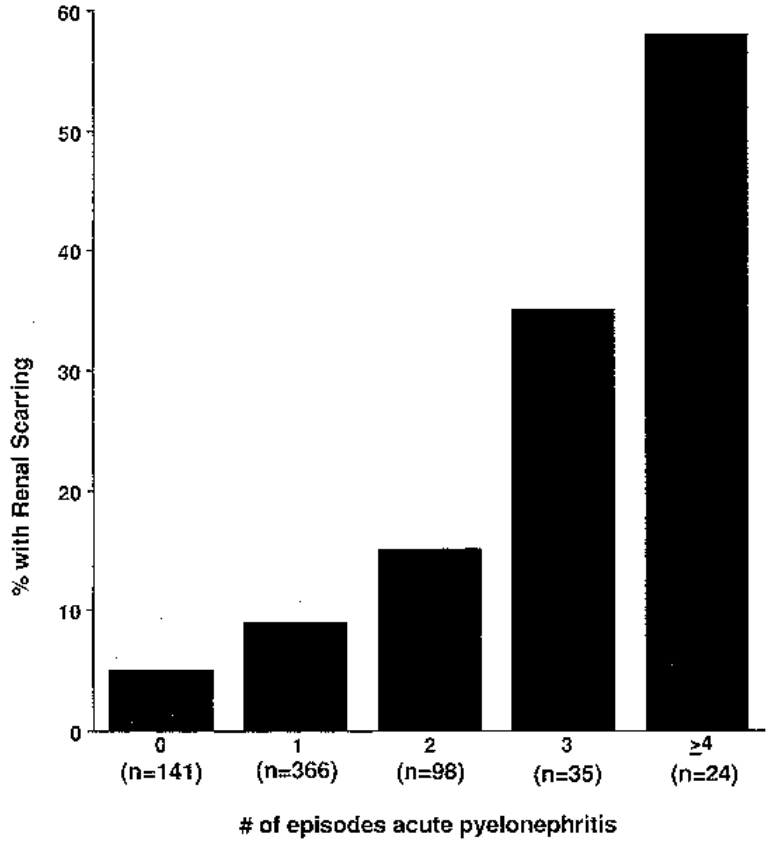

Jodal U.
The natural history of bacteriuria in childhood.
Infect Dis Clin North Am 1:713, 1987

PNA en pacientes con y sin RVU

	% de pacientes	
	con RVU	sin RVU
Stockland	47	39
Jacobsson	34	58
Rosenberg	40	9
Majd	37	21
Hansson	34	34
Ataei	13	29
Tseng	30	12
Preda	30	15
Benador	38	37
Average	**34%**	**28%**

PNA
cicatrices corticales y severidad del RVU

Ya hace décadas (en los 80) que se describió la relación entre % de cicatrices renales y grado de severidad del reflujo

Grado RVU	% cicatrices
I	5
II	6
III	17
IV	25
V	50

Skoog SJ, Belman AB, Majd M.
A nonsurgical approach to the management of primary vesicoureteral reflux.
J Urol. 1987 Oct;138(4 Pt 2):941-6.

- Gammagrafía cortical renal con ^{99m}Tc-DMSA
- Cistogammagrafía
- ITU y RVU
- **Guias Clínicas – Indicaciones actuales**
- Qué hay de nuevo? – Líneas de futuro

▸ SITUACIÓN ACTUAL – GUIAS CLÍNICAS

MANEJO CLINICO DEL NIÑO CON PNA

- LAS GUÍAS ACTUALES han cambiado el manejo del niño con PNA porqué...

En el diagnóstico por imagen de la PNA

- La dosimetría debe tenerse en cuenta
- DMSA 1mSv
- Cistografía miccional 1.8+/-0.9 mSv

Qué significa una ITU en el niño

En el pasado…

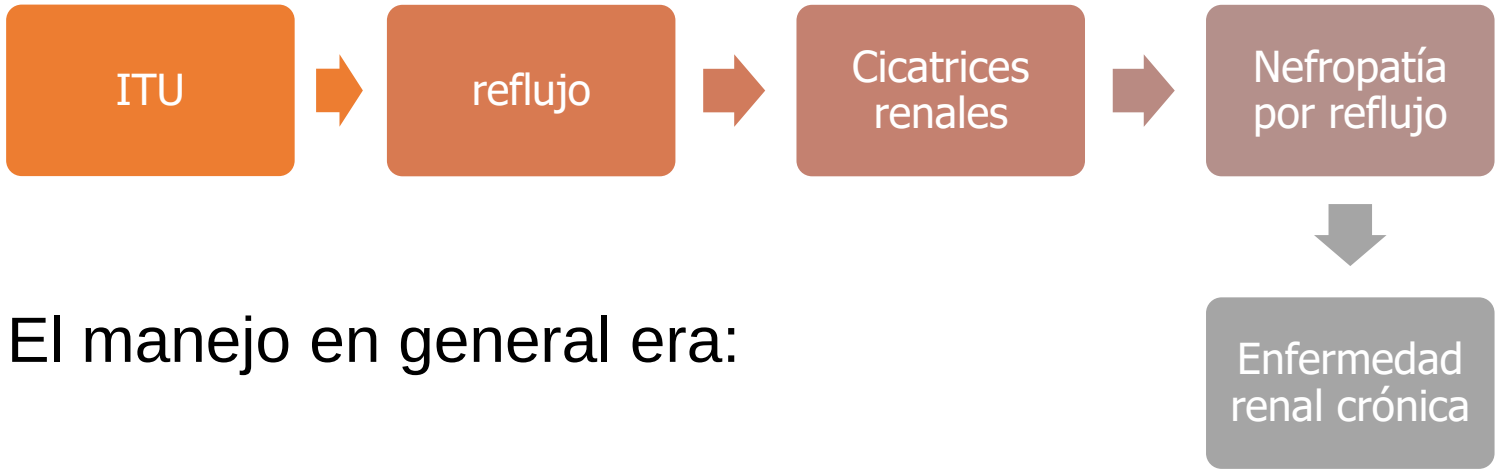

El manejo en general era:

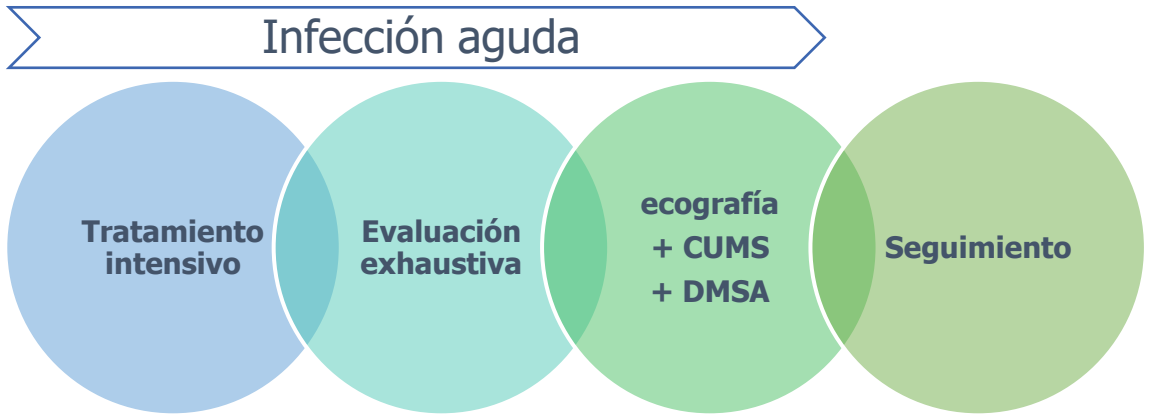

Orientación ACTUAL de la ITU febril y de las cicatrices corticales

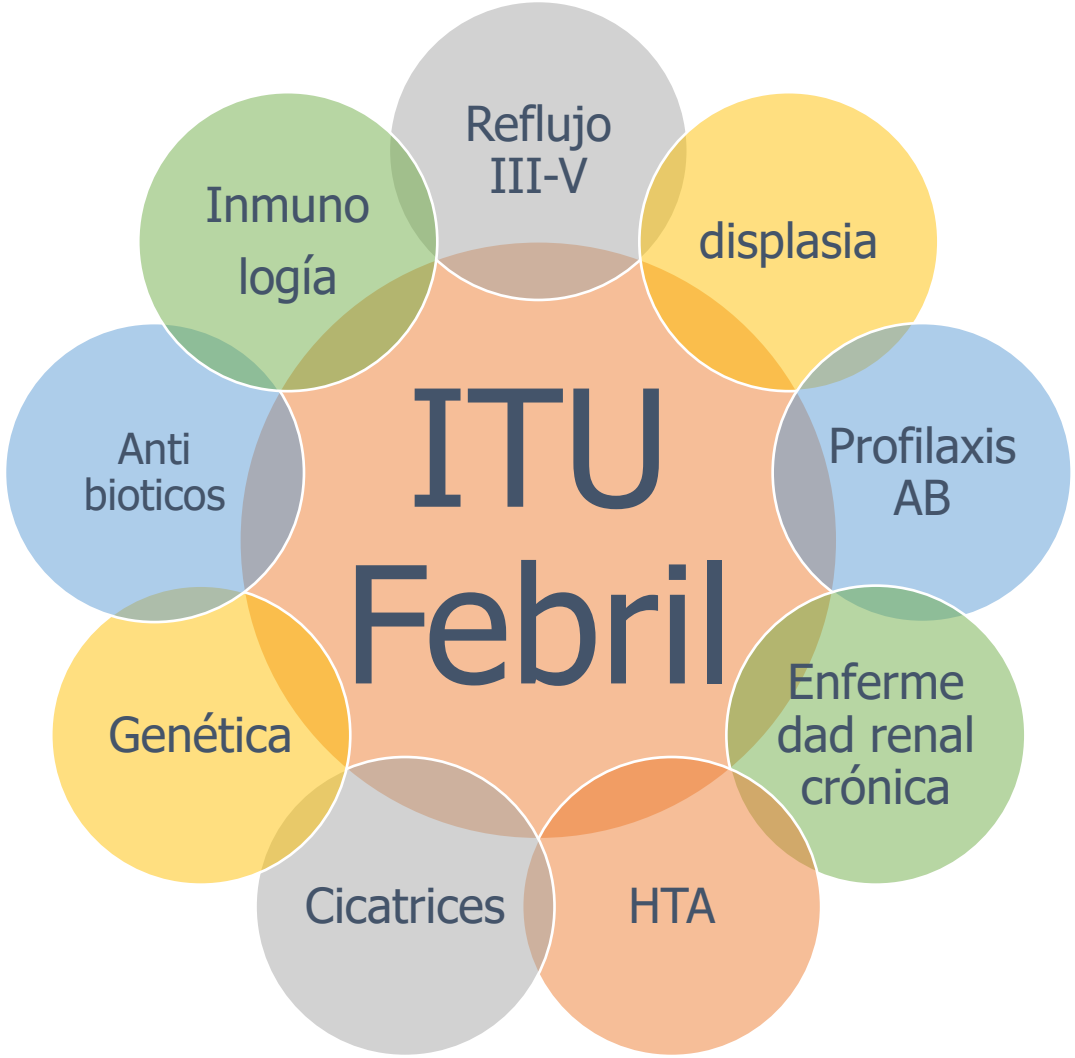

Cambios en el manejo de la ITU febril

Tratamiento de la PNA	Significado del RVU	Prevención del daño renal
1-2 semanas antibiótico EV	riesgo de cicatriz renal	Riesgo de ITU recurrente
3 días antibiótico EV + tratamiento oral	CUMS	Profilaxis universal
Antibiótico via oral en >1-3 meses	RVU I-II (III ?) No relación con daño renal	tratamiento no indicado en RVU de bajo grado

▸ PRINCIPALES GUÍAS CLÍNICAS DE REFERENCIA ACTUALES

1. **American Academy of Pediatrics**: Urinary Tract Infection: Clinical Practice Guidelines of the Diagnosis and Management of the Initial UTI in Febrile Infants and Children 2 to 24 months. Subcommittee on Urinary Tract Infection, Steering Committee on Quality Improvement and Management. Pediatrics 128 (3): 595 – 610, 2011

2. **National Institute for Health and Clinical Excellence**; Urinary Tract Infection in Children: Diagnosis, treatment and long term management www.nice.org.uk/nicemedia/pdf/CG54fullguideline.pdf

3. **Top Down Approach**: Preda, J., Jodal, U., Sixt, R., Stokland, E,. Hansson, S.: Normal Dimercaptosuccinic Acid Scintigraphy Make Voiding Cystourethrography Unnecessary after Urinary Tract Infection. J Pediatr: 151: 581- 584, 2007

4. **Royal Children's Hospital Melbourne** – Clinical practice guidelines. www.rch.org.au/clinicalguide/cpg.cfm?doc_id5241

5. **Italian Society of Pediatric Nephrology** – Ammenti, A., Catatoli, L., Chimenz, R.,
et al: Febrile Urinary Tract Infections in young children: recommendation for the diagnosis, treatment and follow up. Acta Paediatr 101 (5): 451 – 457, 2012

▸ PRINCIPALES GUÍAS CLÍNICAS DE REFERENCIA ACTUALES

Table 3 Imaging Recommendations of 5 Guidelines

Guidelines	Ultrasound	Voiding Cystogram	Late DMSA Scan
RCH	Yes	If boys <6 mo of age or positive findings on ultrasonography or both	No
NICE			
<6 mo	Yes	If positive findings on ultrasonography or atypical UTI or both[a]	If atypical UTI[a]
≥6 mo	If atypical UTI[a]	If children with risk factors[b]	If atypical UTI[a]
TDA	No	If positive remarkable findings on DMSA scintigraphy	If positive remarkable findings on DMSA scintigraphy
AAP	Yes	If positive findings on ultrasonography	No
ISPN	Yes	If positive findings on ultrasonography or children with risk factors[c]	If positive findings on ultrasonography or for VUR or both

RCH, Royal Children's Hospital, Melbourne; TDA, top-down approach; ISPN, International Society of Pediatric Nephrology.

[a]Seriously ill, poor urine flow, abdominal or bladder mass, raised creatinine levels, septicemia, failure to respond to correct antibiotic treatment within 48 hours, or infection with non–*Escherichia coli* organisms.

[b]Dilatation on ultrasonography, poor urine flow, non–*Escherichia coli* infection, or family history of VUR.

[c]Abnormal prenatal ultrasonography of the urinary tract, family history of VUR, septicemia, renal failure, age <6 months in a male infant, likely noncompliance of the family, abnormal bladder emptying, no clinical response to correct antibiotic treatment within 72 hours, or non–*Escherichia coli* infection.

TOP DOWN APPROACH: ^{99}Tc DMSA e ITU

^{99m}Tc DMSA es más sensible que la ecografía (defectos de captación= focos de PNA y cicatrices)

^{99m}Tc DMSA es útil para detector el riesgo de reflujo de alto grado y reducer otras técnicas de imagen (cistografía CUMS) en niños de bajo riesgo

PNA

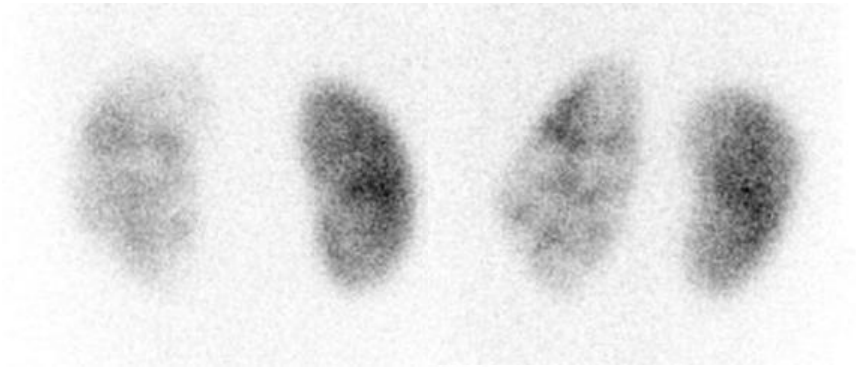

Cicatrices renales

Preda, J., Jodal, U., Sixt, R., Stokland, E,. Hansson, S.: Normal Dimercaptosuccinic Acid Scintigraphy Make Voiding Cystourethrography Unnecessary after Urinary Tract Infection. J Pediatr: 151: 581- 584, 2007

NICE Guidelines

in UTI in children

Infant under 6 months

Test	Responds well to treatment within 48 hours	Atypical UTI	Recurrent UTI
Ultrasound during the acute infection	No	Yes[1]	Yes
Ultrasound within 6 weeks	Yes[2]	No	No
DMSA 4–6 months following the acute infection	No	Yes	Yes
MCUG	No	Yes	Yes

Infant from 6 months to under 3 years

Test	Responds well to treatment within 48 hours	Atypical UTI	Recurrent UTI
Ultrasound during the acute infection	No	Yes[1]	No
Ultrasound within 6 weeks	No	No	Yes
DMSA 4–6 months following acute infection	No	Yes	Yes
MCUG	No	No[3]	No[3]

Child aged 3 or over

Test	Responds well to treatment within 48 hours	Atypical UTI	Recurrent UTI
Ultrasound during the acute infection	No	Yes[4,5]	No
Ultrasound within 6 weeks	No	No	Yes[4]
DMSA 4–6 months following acute infection	No	No	Yes
MCUG	No	No	No

https://pathways.nice.org.uk/pathways/urinary-tract-infection-in-under-16s#content=view-node%3Anodes-imaging

▸ PRINCIPALES GUÍAS CLÍNICAS DE REFERENCIA ACTUALES

Top-down" approach

- Focalizado en el daño renal
- DMSA en fase aguda

"Bottom-up" approach

- Focalizado al reflujo renal
- Cistografía

"Top-down" diagnostic approach

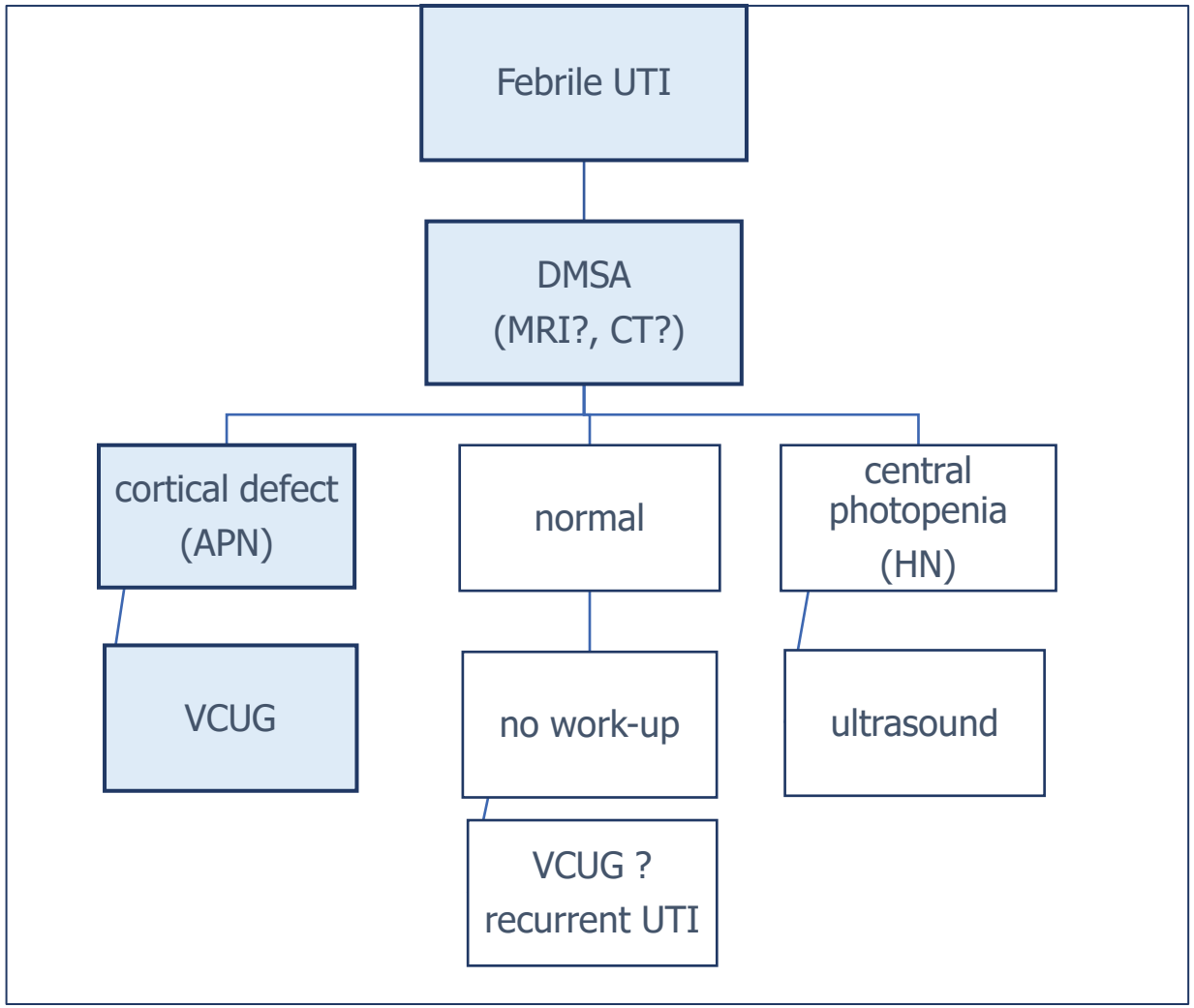

"Bottom-up" diagnostic approach

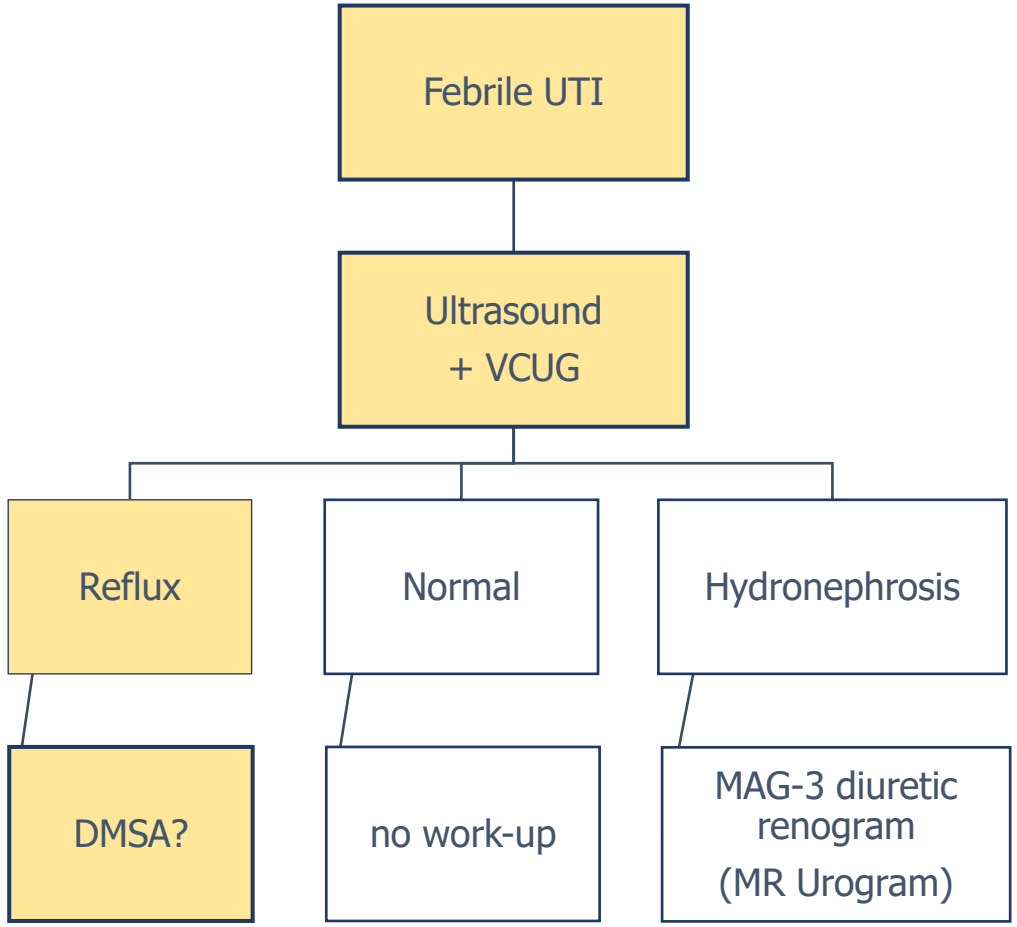

DMSA en fase aguda de la PNA

Recomendado
TDA (“top down” approach)
No recomendado
NICE (National Institute of clinical excellence)
ISPN (Italian society of Pediatric Nephrology)
RCH (Royal Children’s Hospital of Melbourne)
AAP (American Academy of Pediatrics)

DMSA para detectar secuelas de PNA

Recomendado	cuando
TDA ("top down" approach)	Si DMSA + en fase aguda
NICE (National Institute of clinical excellence)	ITU febril atípica o recurrente
ISPN (Italian society of Pediatric Nephrology)	Ecografía positiva o cistografía con reflujo
Not recommended	
RCH (Royal Children's Hospital of Melbourne)	
AAP (American Academy of Pediatrics)	

RESUMEN

▸ PRINCIPALES GUÍAS CLÍNICAS DE REFERENCIA ACTUALES

- Todas las guías excepto TDA recomiendan ECOGRAFÍA como la primera exploración de imagen
- Todas las guías restringen el uso de la cistografía CUMS a casos seleccionados: ecografía +, ITU atípicas o recurrentes, otros factores de riesgo, DMSA patológico
- Todas limitan la indicación del DMSA tardío para detector secuelas a los casos de ITU-f atípicas o recurrentes o con ecografía positiva o con DMSA previo patológico
- RCH y AAP no recomiendan DMSA tardío

RESUMEN

▸ PRINCIPALES GUÍAS CLÍNICAS DE REFERENCIA ACTUALES

- No existe un protocolo de diagnóstico ideal para una primera ITU febril

- Los protocolos "agresivos" tienen una alta sensibilidad para detector refkujo y cicatrices pero con alto coste económico y dosimetría

- No hay consenso por la incerteza del significado clínico a largo término del reflujo y de las cicatrices renales

- El daño renal atribuido previamente a cicatrices pielonefríticas se atribuye actualmente de forma más frecuente a lesiones congénitas

RESUMEN

- PRINCIPALES GUÍAS CLÍNICAS DE REFERENCIA ACTUALES

DMSA en ITU-f

INDICACIONES

- cicatrices corticales a los 6-12 meses de una ITU-F: confirmacion de PNA
- Riñón pequeño con captación uniforme: sugiere patología congénita prenatal
- Defecto focal con pérdida del contorno sugiere infección en relación con cicatriz

- Top down approach –DMSA en fase aguda
  - Solo se realiza cistografía CUMS si DMSA patológico
  - disminución significativa del número de cistografías

- Bottom up approach – DMSA solo si RVU
  - Ecografía + CUMS
  - DMSA tardío en caso de reflujo
  - DMSA patológico confirma una PNA previa

DMSA en ITU-f

INDICACIONES

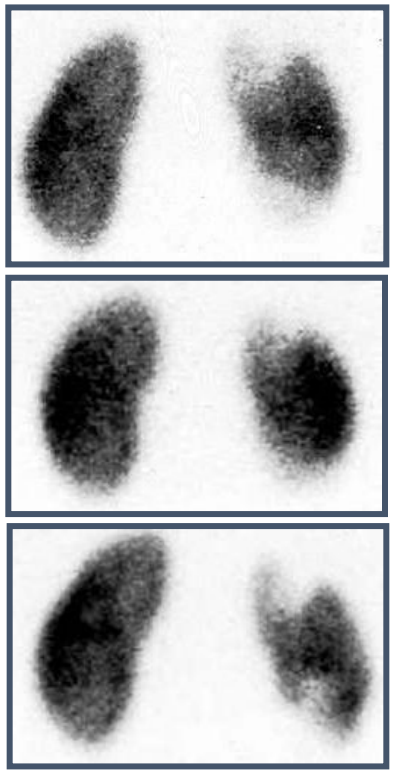

- **cicatrices corticales a los 6-12 meses de una ITU-F: confirmacion de PNA**
- Riñón pequeño con captación uniforme: sugiere patología congénita prenatal
- Defecto focal con pérdida del contorno sugiere infección en relación con cicatriz

- Top down approach –DMSA en fase aguda
  - Solo se realiza cistografía CUMS si DMSA patológico
  - disminución significativa del número de cistografías

- Bottom up approach – DMSA solo si RVU
  - Ecografía + CUMS
  - DMSA tardío en caso de reflujo
  - DMSA patológico confirma una PNA previa

DMSA en ITU-f

INDICACIONES

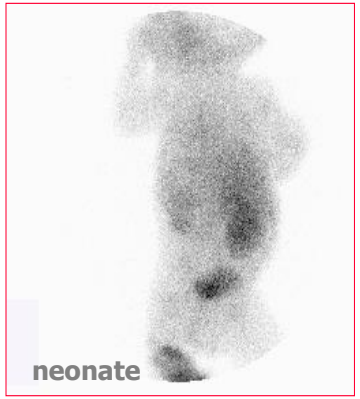

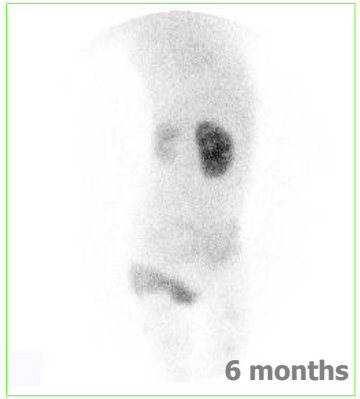

- cicatrices corticals a los 6-12 meses de una ITU-F: confirmacion de PNA

- **Riñón pequeño con captación uniforme: sugiere patología congénita prenatal**

- Defecto focal con pérdida del contorno sugiere infección en relación con cicatriz

- Top down approach –DMSA en fase aguda
  - Solo se realiza cistografía CUMS si DMSA patológico
  - disminución significativa del número de cistografías

- Bottom up approach – DMSA solo si RVU
  - Ecografía + CUMS
  - DMSA tardío en caso de reflujo
  - DMSA patológico confirma una PNA previa

DMSA en ITU-f

INDICACIONES

- cicatrices corticales a los 6-12 meses de una ITU-F: confirmacion de PNA
- Riñón pequeño con captación uniforme: sugiere patología congénita prenatal
- **Defecto focal con pérdida del contorno sugiere infección en relación con cicatriz**

PNA

6 m

2nda PNA

- Top down approach –DMSA en fase aguda
  - Solo se realiza cistografía CUMS si DMSA patológico
  - disminución significativa del número de cistografías
- Bottom up approach – DMSA solo si RVU
  - Ecografía + CUMS
  - DMSA tardío en caso de reflujo
  - DMSA patológico confirma una PNA previa

DMSA en ITU-f

INDICACIONES

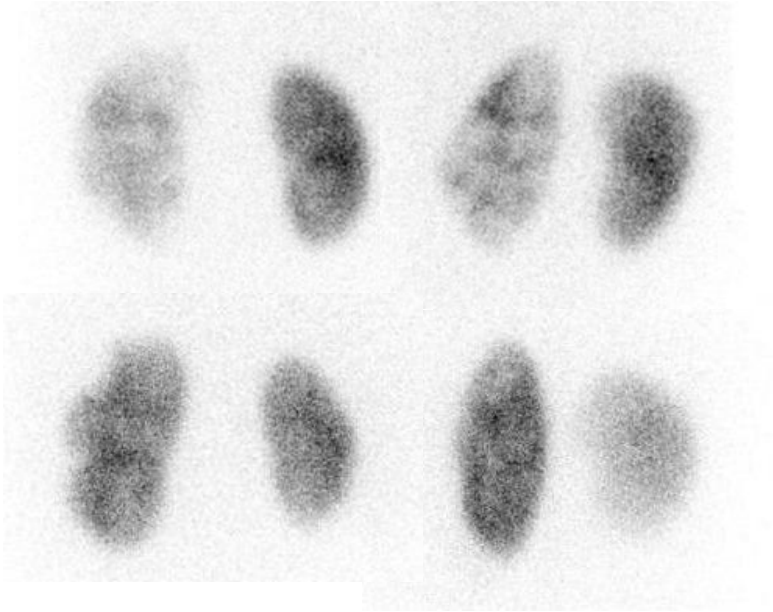

- cicatrices corticales a los 6-12 meses de una ITU-F: confirmacion de PNA
- Riñón pequeño con captación uniforme: sugiere patología congénita prenatal
- Defecto focal con pérdida del contorno sugiere infección en relación con cicatriz

- **Top down approach –DMSA en fase aguda**
  - **Solo se realiza cistografía CUMS si DMSA patológico**
  - **disminución significativa del número de cistografías**

- Bottom up approach – DMSA solo si RVU
  - Ecografía + CUMS
  - DMSA tardío en caso de reflujo
  - DMSA patológico confirma una PNA previa

DMSA en ITU-f

INDICACIONES

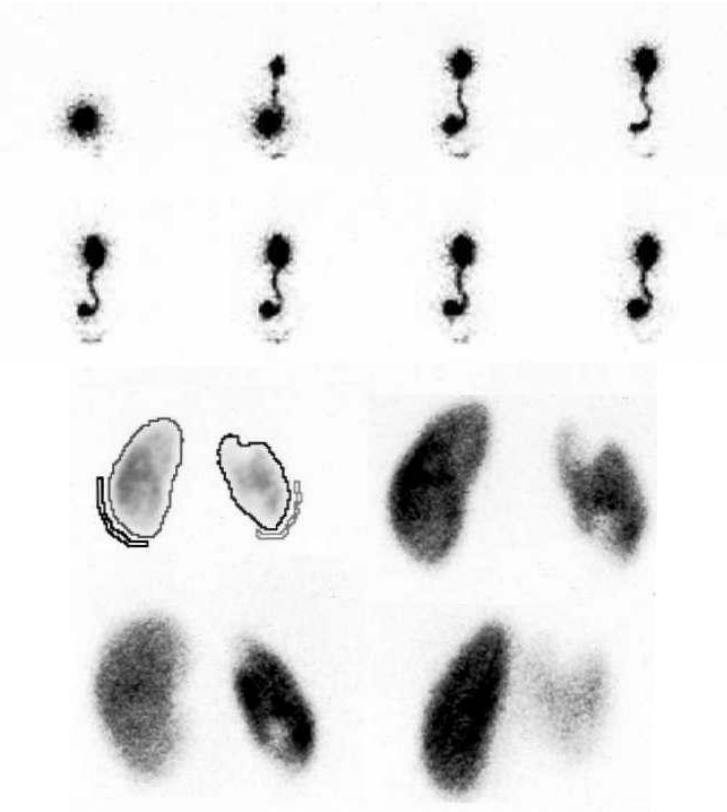

- cicatrices corticales a los 6-12 meses de una ITU-F: confirmacion de PNA
- Riñón pequeño con captación uniforme: sugiere patología congénita prenatal
- Defecto focal con pérdida del contorno sugiere infección en relación con cicatriz

- Top down approach –DMSA en fase aguda
  - Solo se realiza cistografía CUMS si DMSA patológico
  - disminución significativa del número de cistografías

- **Bottom up approach – DMSA solo si RVU**
  - **Ecografía + CUMS**
  - **DMSA tardío en caso de reflujo**
  - **DMSA patológico confirma una PNA previa**

^{99m}Tc-DMSA en fase aguda: predicción de la existencia de reflujo con dilatación grados III-IV-V

473 lactantes =<2 años
edad media 5 meses
289 niños & 184 niñas
1era ITU-f

DMSA en fase aguda
patológico: 282 (59.6%)

Reflujo VU: 153 (32.3%)
Reflujo con dilatación: 95 (20.1%)

^{99}Tc-DMSA **Sensibilidad** reflujo con dilatación	**^{99}Tc-DMSA** **VPN** Valor predictivo negativo	**^{99}Tc-DMSA** **Positive likelihood ratio**	**^{99}Tc-DMSA** **Negative likelihood ratio**
95.8%	97.9%	1.90	0.08

Sheu, Ji-Nan et al.
Clin Nuclear Medicine 2013 38(3):163-168

Predicción de daño renal basada en DMSA tardío: comparación de 5 guías

TABLE 6 Diagnostic Ability of 5 Guidelines as Predictors of Parenchymal Renal Damage Based on Late DMSA Scan

Guidelines	Scars Detected	Percent (95% CI)					
	n (%)	Sensitivity	Specificity	PPV	NPV	LR+	LR−
RCH	0/45 (0)	NA	NA	NA	NA	NA	NA
NICE	17/45 (38)	38 (24–52)	84 (80–89)	29 (18–41)	89 (85–93)	2.4 (1.9–2.8)	0.7 (0.5–1)
TDA	45/45 (100)	100	56 (49–62)	28 (21–35)	100	2.2 (2.1–2.4)	0
AAP	0/45 (0)	NA	NA	NA	NA	NA	NA
ISPN	20/45 (47)	44 (30–59)	86 (82–90)	36 (23–48)	90 (86–94)	3.2 (2.7–3.6)	0.6 (0.4–0.9)

NA, not applicable.

DMSA en fase aguda | 95,8% | 98%

La Scola C et al.
Pediatrics 2013; 131: e665-e671

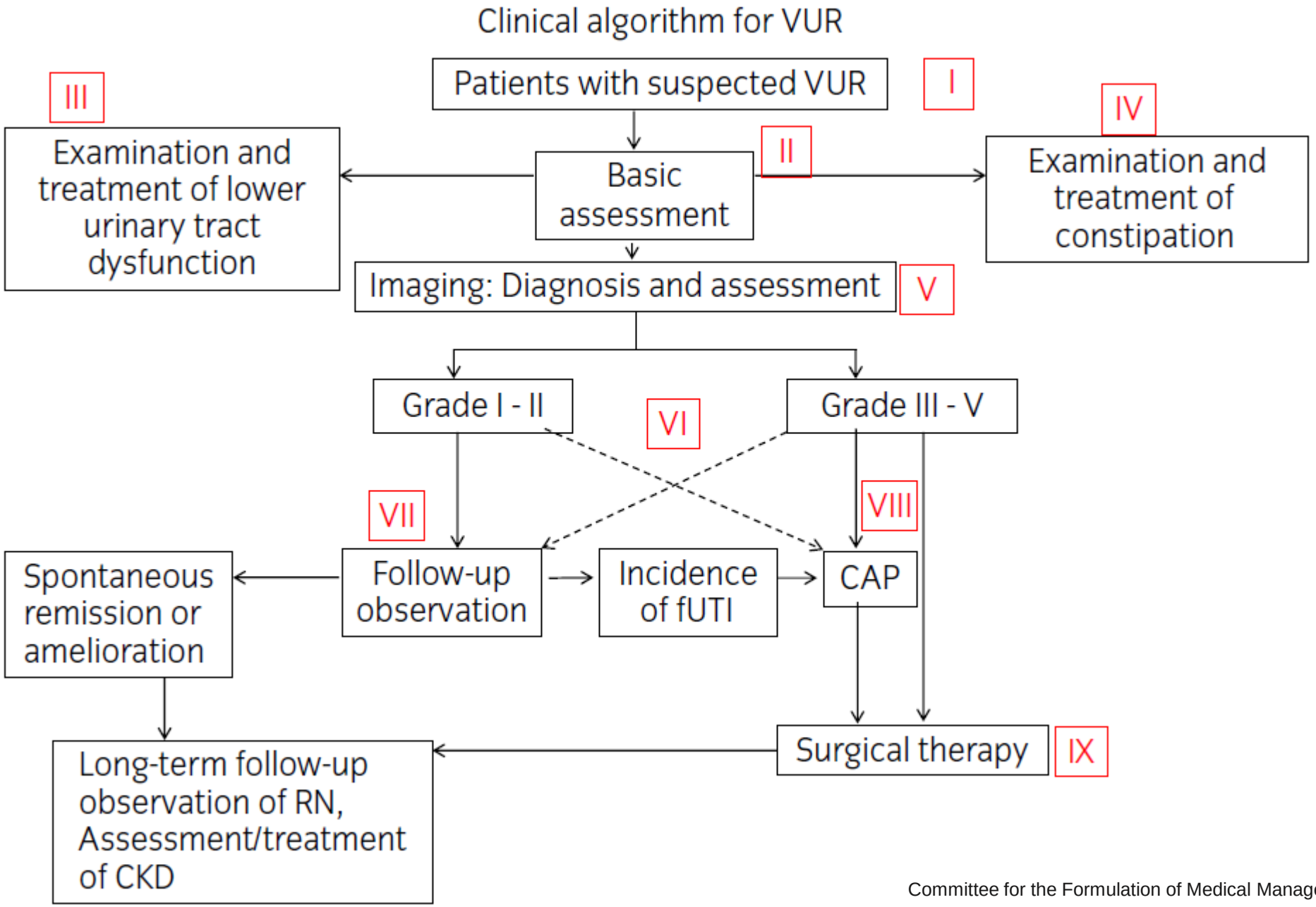

Committee for the Formulation of Medical Management Guidelines for Pediatric Vesicoureteral Reflux, Japanese Society of Pediatric Urology
Guidelines for the medical management of pediatric vesicoureteral reflux
International Journal of Urology (2020) 27, 480--490

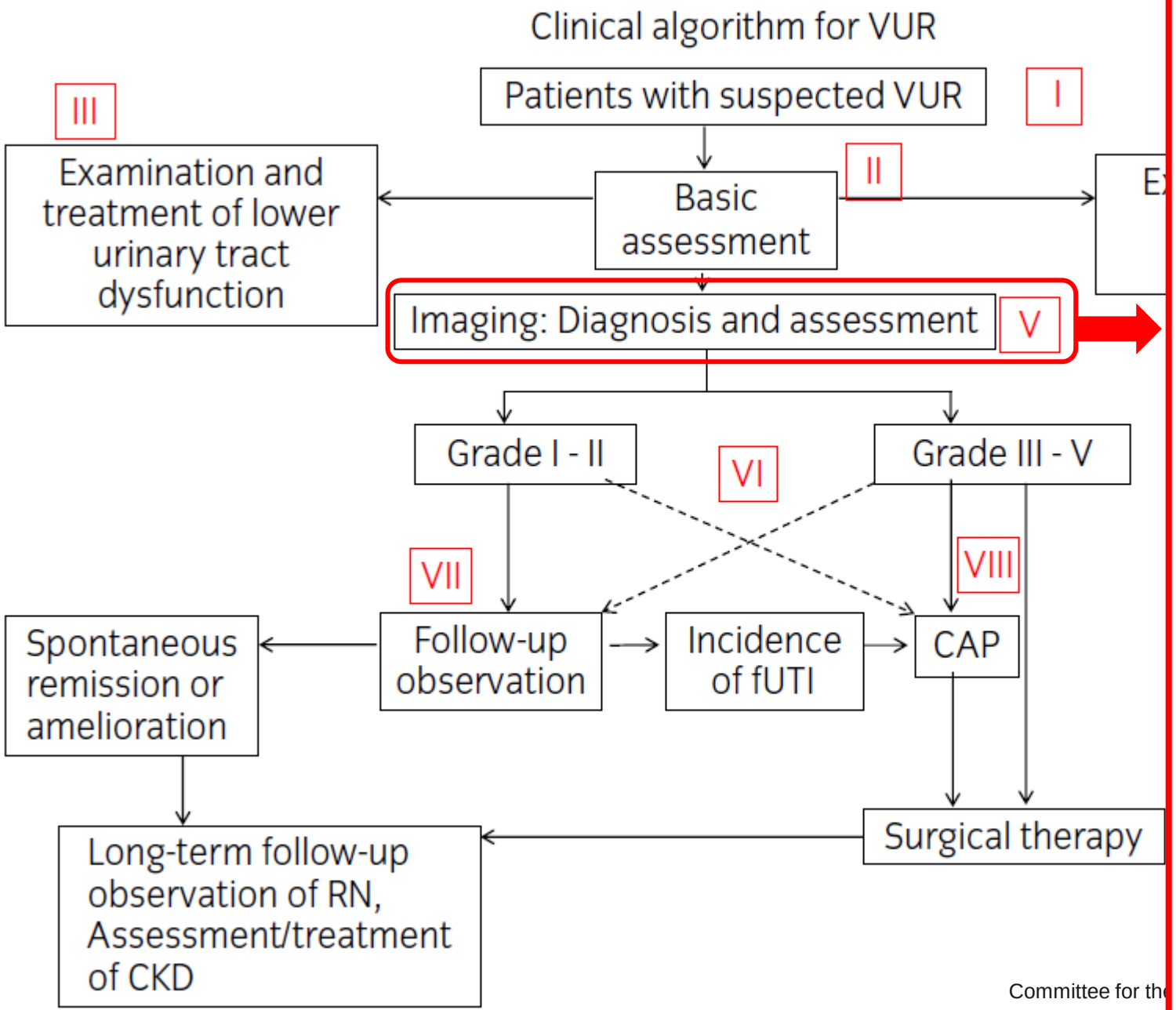

V. Imaging: Diagnosis and assessment

Renal and bladder ultrasound, VCUG, and ^{99m}Tc-DMSA renal scintigraphy are used.

1 Renal and bladder ultrasound: Urinary tract malformation, such as hydronephrosis, hypoplastic kidney, duplicated ureter, megaloureter and ureterocele, can be accurately diagnosed. This modality is useful because of its low invasiveness and ease of repeated use. Ultrasound findings, such as pyelectasis, abnormal echogenicity, differences in renal dimensions between the right and left kidney, irregular contour, ureterocele, and dilatation of the lower ureters at the dorsal aspect of the bladder, are important, because they are possible risk factors for UTI. Ultrasound screening did not detect any abnormalities in 46–60% of patients with VUR detected by VCUG.[33–35] The accuracy of diagnosis of VUR based on the presence/absence of ultrasound abnormalities is low, with a sensitivity of 18–46%, specificity of 76–88%, positive predictive value of 24–66% and negative predictive value of 71–83%.[33–35]

2 VCUG: VCUG is a standard imaging test used for the diagnosis of VUR. It offers detailed anatomical information, enabling determining the presence/absence of VUR, and also the severity grade according to the international classification.[36–38] VCUG is required for assessment of the lower urinary tract, as well as diagnosis of VUR.[20,23,28,39]

3 ^{99m}Tc-DMSA renal scintigraphy: ^{99m}Tc-DMSA renal scintigraphy is a standard imaging test used for diagnosis of renal parenchymal damage, and is suited for assessment of split renal function and renal scarring in patients with VUR.

Committee for the

ux,
gy
ux
90

Screening of infants with fetal hydronephrosis diagnosed antenatally using fetal ultrasound

Renal and bladder ultrasound is the standard test for newborns with fetal hydronephrosis diagnosed antenatally.[40–42] VCUG is necessary to confirm the presence/absence of VUR in patients with SFU grade 3 or 4 hydronephrosis with ureteral dilatation.

Screening after fUTI

First episodes of fUTI: Approximately 30–50% of young children with fUTI have VUR, and thus there is no clear evidence to rule out the fact that all patients with a first episode of fUTI should undergo VCUG. VCUG is also useful for assessment of functional and organic abnormalities of the lower urinary tract, and some patients with the first episode of fUTI need to be examined with VCUG.[20,23,28,43]

1er episodio de ITU-f:

CUMS para
- detectar RVU
  30-50% de los casos

- Detectar anomalías congénitas
  (valvas uretrales, vejiga, etc)

Committee for the Formulation of Medical Management Guidelines for Pediatric Vesicoureteral Reflux, Japanese Society of Pediatric Urology
Guidelines for the medical management of pediatric vesicoureteral reflux
International Journal of Urology (2020) 27, 480--490

Screening of infants with fetal hydronephrosis diagnosed antenatally using fetal ultrasound

Renal and bladder ultrasound is the standard test for newborns with fetal hydronephrosis diagnosed antenatally.[40–42] VCUG is necessary to confirm the presence/absence of VUR in patients with SFU grade 3 or 4 hydronephrosis with ureteral dilatation.

Screening after fUTI

Recurrent episodes of fUTI: VCUG should be carried out in patients with recurrent episodes of fUTI, because they are highly likely to have VUR. Also, given that fUTI is a precondition for renal scarring, fUTI recurrence is a risk factor. Thus, patients with recurrent episodes of fUTI need to be examined for renal scarring using ^{99m}Tc-DMSA renal scintigraphy, as well as for VUR using VCUG.

ITU-f recurrentes:
= Factor de riesgo para desarrollar cicatrices renales

CUMS para
- detectar RVU

Gammagrafia renal DMSA
- detectar lesiones corticales

Committee for the Formulation of Medical Management Guidelines for Pediatric Vesicoureteral Reflux, Japanese Society of Pediatric Urology
Guidelines for the medical management of pediatric vesicoureteral reflux
International Journal of Urology (2020) 27, 480--490

Screening of infants with fetal hydronephrosis diagnosed antenatally using fetal ultrasound

Renal and bladder ultrasound is the standard test for newborns with fetal hydronephrosis diagnosed antenatally.[40–42] VCUG is necessary to confirm the presence/absence of VUR in patients with SFU grade 3 or 4 hydronephrosis with ureteral dilatation.

Screening after fUTI

Screening with a focus on renal parenchymal lesions rather than the presence/absence of VUR: Changes in fUTI management strategies in young children are based on the viewpoint that the presence/absence of renal parenchymal lesions, rather than VUR, determines renal functional outcomes. Inevitably, VUR is more likely to be missed, but the most undetected cases were reportedly of mild VUR that did not cause renal scarring.[44–47] Also, in high-grade VUR (international VUR classification grade III–V), the frequency of breakthrough UTI is overwhelmingly higher in patients with renal scarring (60%) than in those without scarring (6%), and thus assessment of renal scarring by ^{99m}Tc-DMSA renal scintigraphy is useful.[48]

The level of usefulness of each test for diagnosis of pediatric VUR is shown in Table 1.

Detección del daño renal:
Las lesiones parenquimatosas son más importantes que la existencia de RVU para la predicción de enfermedad renal crónica.

Gammagrafia renal DMSA
- detectar lesiones corticales

Committee for the Formulation of Medical Management Guidelines for Pediatric Vesicoureteral Reflux, Japanese Society of Pediatric Urology
Guidelines for the medical management of pediatric vesicoureteral reflux
International Journal of Urology (2020) 27, 480--490

Table 1 Diagnosis of pediatric VUR: level of usefulness of each test

		Ultrasound	VCUG	DMSA renal scintigraphy
Hydronephrosis detected using fetal ultrasound	Medical history of fUTI (–)	★★★	▲ (★★; SFU grade 3–4, with ureteral dilatation)	▲
	Medical history of fUTI (+)		★★★	★
After fUTI	First episode	★★★	★★	★
	Recurrent episodes		★★★	★★★
Lower urinary tract abnormalities (suspected)	Medical history of fUTI (+)	★★★	★★★	★

★★★, Considered as standard; ★★, considered as standard depending on the condition; ★, considered as optional; ▲, not recommended.

COMENTARIOS - RESUMEN

- No existe ningún algoritmo único de diagnóstico que se pueda utilizar en una primera ITU febril.

- Hay un consenso creciente que los lactantes y niños con ITU no necesitan imagen invasiva, al menos inicialmente.

- Los protocolos más interencionistas tienen una alta sensibilidad para detector RVU y cicatrices renales, pero implican un coste financiero y dosimétrico, con beneficio cuestionable.

- **De todas maneras, con esta aproximación existe el peligro de dejar de diagnosticar un pequeño subgrupo de niños con tendencia a desarrollar daño renal secundario a las PNA, y en los cuales sería beneficioso realizar pruebas diagnósticas.**

- Gammagrafía cortical renal con ^{99m}Tc-DMSA
- Cistogammagrafía
- ITU y RVU
- Guias Clínicas – Indicaciones actuales
- Qué hay de nuevo? – Líneas de futuro

▸Qué hay de nuevo? – Líneas de futuro

TÉCNICA

- Nuevas gammacamaras y PET con detectores de estado sólido:
  - Mejor resolución volumétrica
  - Mejor resolución espacial
  - Mayor resolución en energía
  - Mitad de la dosis o mitad del tiempo de detección
  - Mayor detectabilidad de lesiones pequeñas
  - Detectabilidad simultania multitrazador

- SPECT y SPECT-CT:
  - SPECT con baja dosis
  - CT con reducción de dosis

- Nuevos software:
  - Artificial intelligence
  - Mejoría y estandarización de la interpretación de la imagen

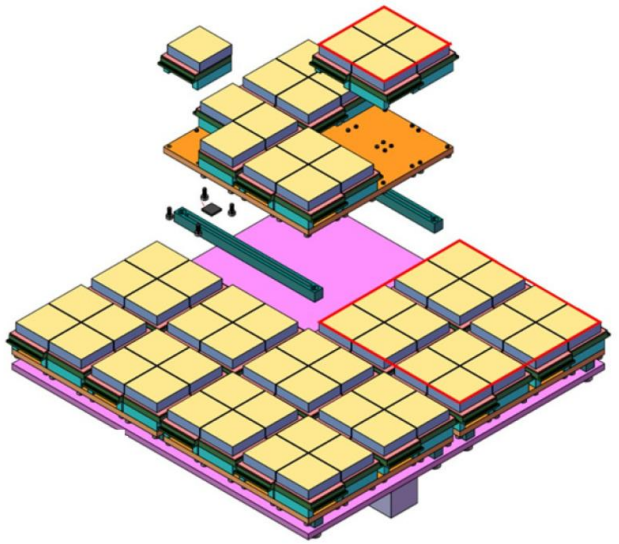

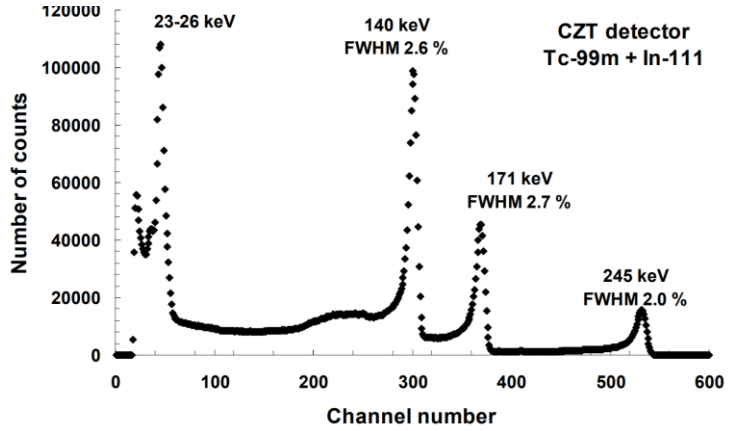

▸Qué hay de nuevo? – Líneas de futuro

NUEVAS GUÍAS

- DMSA: guia conjunta SNMMI – EANMMI 2021

SNMMI Procedure Standard/EANM Practice Guideline on Pediatric ^{99m}Tc-DMSA Renal Cortical Scintigraphy: An Update

Reza Vali 1, Ian Armstrong 2, Zvi Bar-Sever 3, Lorenzo Biassoni 4, Lise Borgwardt 5, Justin Brown 6, Frederick D. Grant 7, Gerald A. Mandell 8, Massoud Majd 9, Helen R. Nadel 10, Arnoldo Piccardo 11, Isabel Roca-Bielsa 12, Taryn J. Rohringer 13, Ana Isabel Santos 14,Victor Seghers 15, Nader Shaikh 16, S. Ted Treves 17, Teresa Zaffino-Nevrotski 18, Pietro Zucchetta 19 ,Ruth Lim (chair) 20

- VUR Medical management (Japanese Society Urology) 2020

- ITU-F: EAU ESPU Guidelines 2015, AAP 2011
- VUR: EAU Guideline 2012, AUA 2010

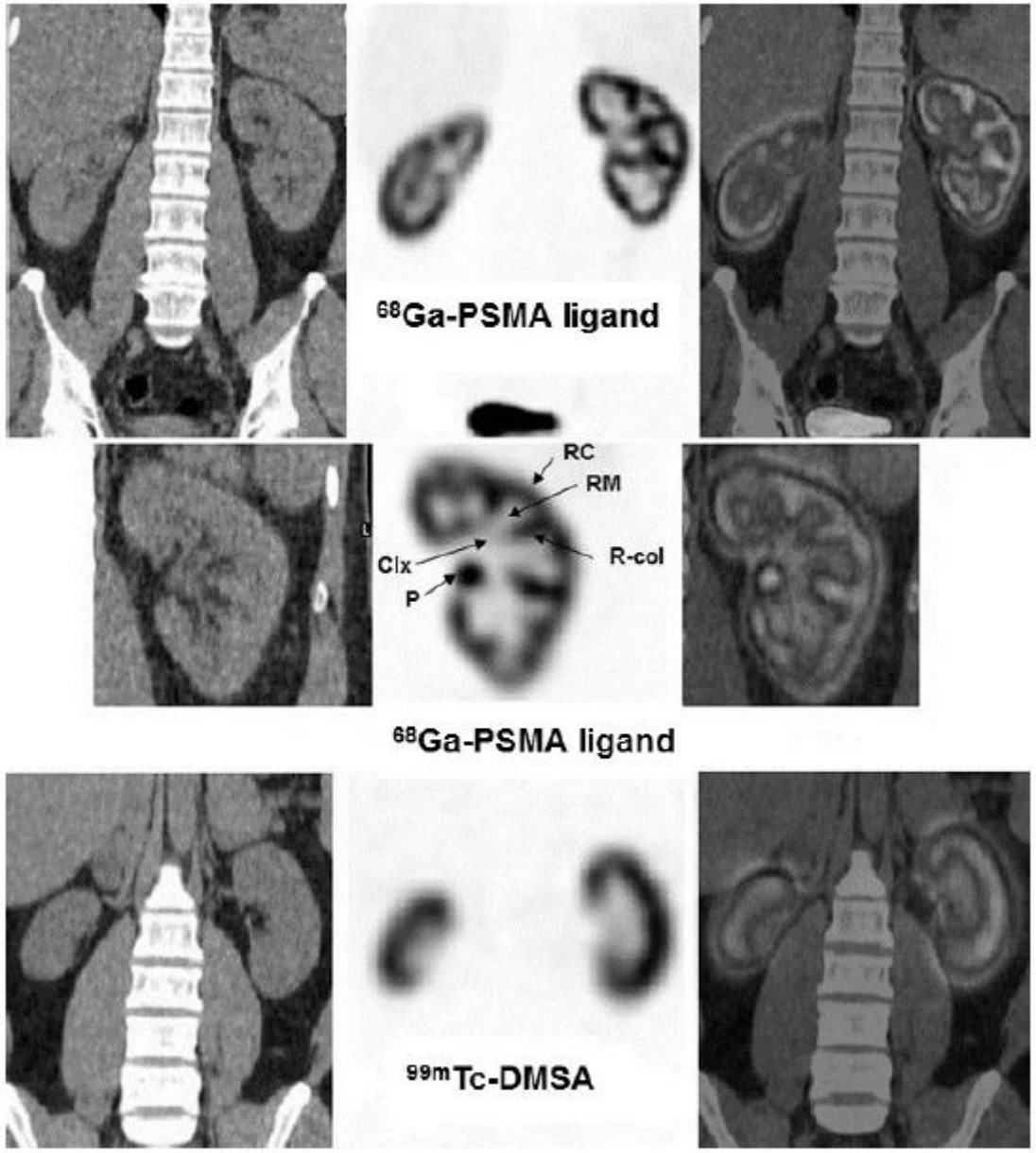

Nuevo trazador?

^{68}Ga-PSMA

Sarikaya I, Alqallaf A, Sarikaya A.
Renal Cortical 68Ga-PSMA PET and 99mTc-DMSA Images.
J Nucl Med Technol. 2020 Sep 4:jnmt. 120.248922.
doi: 10.2967/jnmt.120.248922. Epub ahead of print. PMID: 32887764.

Sarikaya I, Sarikaya A.
Current Status of Radionuclide Renal Cortical Imaging in Pyelonephritis.
J Nucl Med Technol. 2019 Dec;47(4):309-312.
doi: 10.2967/jnmt.119.227942. Epub 2019 Jun 10. PMID: 31182659.

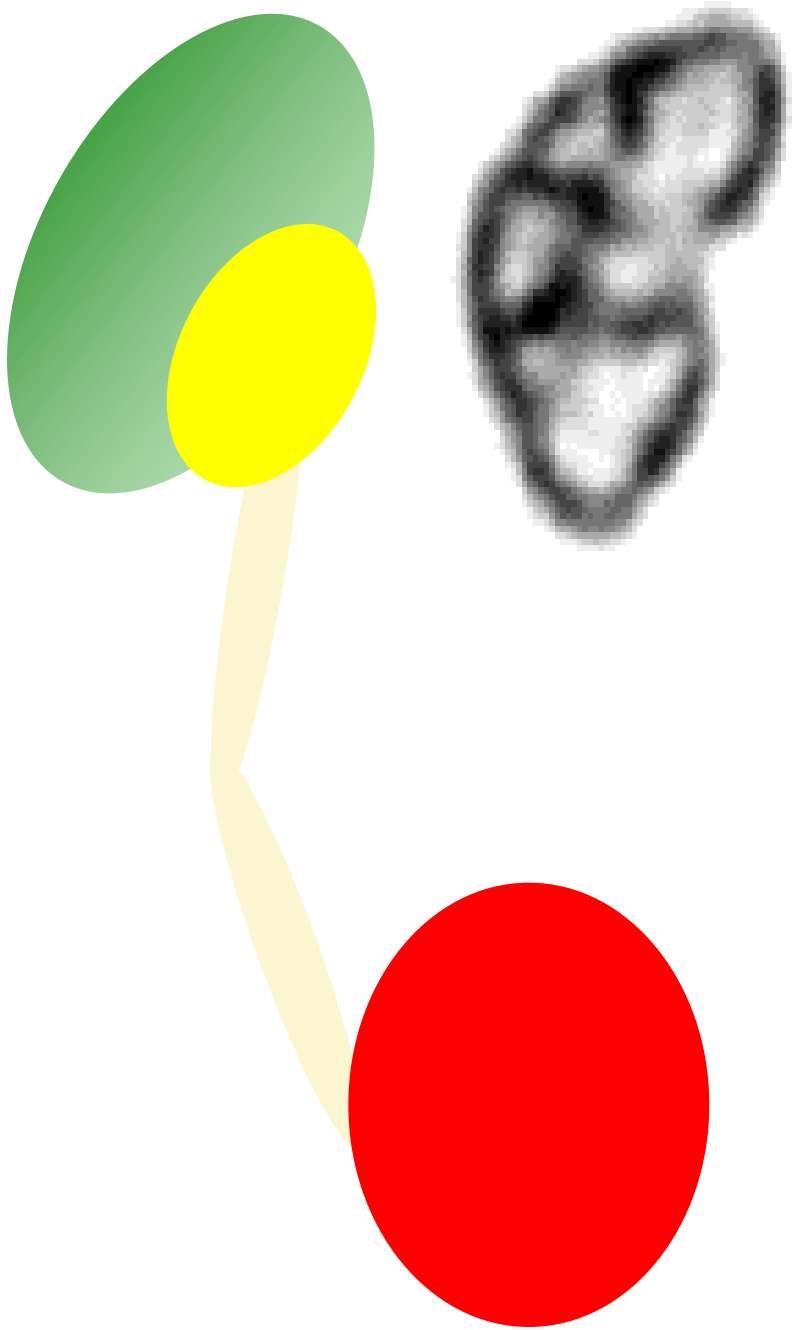

- Gammagrafía cortical renal con ^{99m}Tc-DMSA
- Cistogammagrafía
- ITU y RVU
- Guias Clínicas – Indicaciones actuales
- Qué hay de nuevo? – Líneas de futuro