Formación Sant Joan de Déu

International Advanced Course on Paediatric Orthopaedics. Tricks and pitfalls.

Trucos y trampas en la Ortopedia Pediátrica. Curso Avanzado Internacional.

30 Noviembre 2019, 9:40

Sant Joan de Déu Barcelona · Hospital

Incorporemos el PET al estudiar la extensión de tumor/ infección

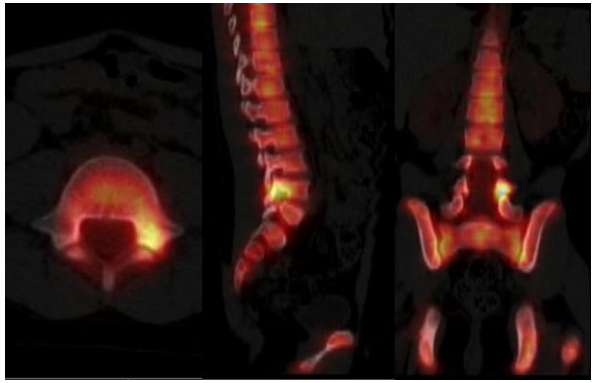

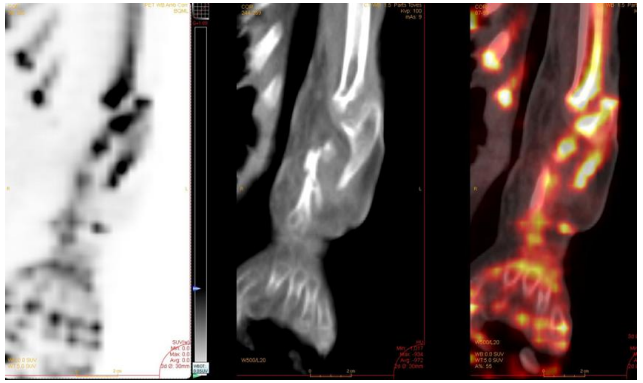

SIMM Imatge Mèdica

Isabel Roca
Medicina Nuclear Pediatrica - SIMM
UAB - Barcelona

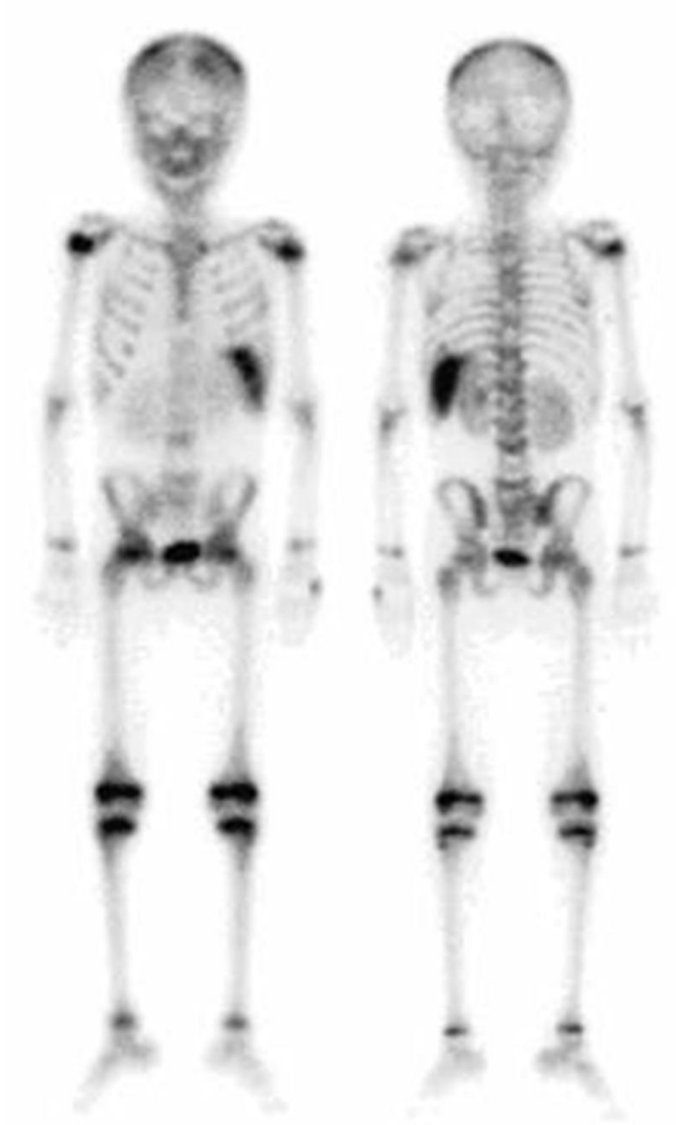

Bone scintigraphy
and
Bone ^{18}F-PET
are excellent tools to assess
bone metabolism

BONE GROWING DURING CHILDHOOD requires:

- blood supply

and

- osteoblastic / osteoclastic activity

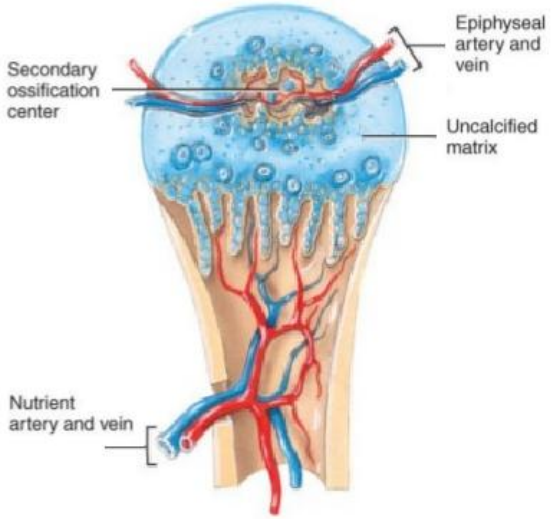

- **OSTEOBLASTS:** bone forming cells
  - mesenchymal origin
  - produce bone tissue:
    - organic bone matrix
    - collagen fibres

- **OSTEOCYTES**
  - produce the inorganic matrix
  - no longer secrete bone matrix
  - derived from osteoblasts that have secreted bone around themselves

- **OSTEOCLASTS**
  - extremely large cells
  - derived from haematopoietic system (fused monocytes)
  - bone resorption
    = destruction of bone matrix

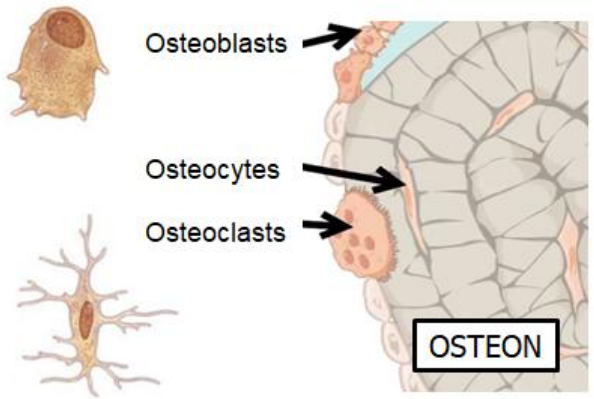

http://slideplayer.com

Bone Physiology

Matrix of bone

BONE'S FLEXIBILITY:

- collagen fibres

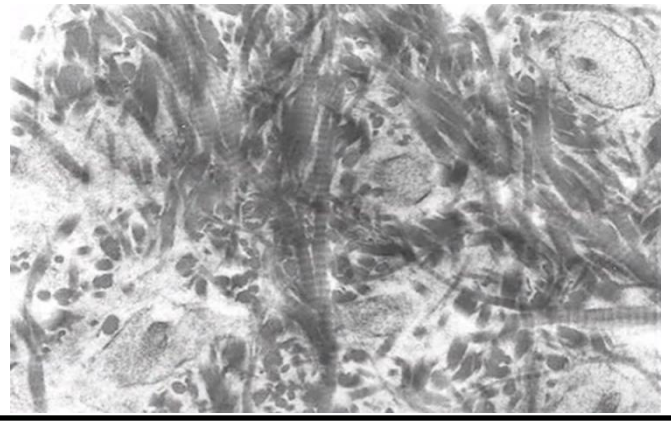

CALCIFICATION:

- mineral crystals deposit around collagen fibres

BONE'S HARDNESS: inorganic salts

- calcium phosphate
- hydroxide
- hydroxyapatite

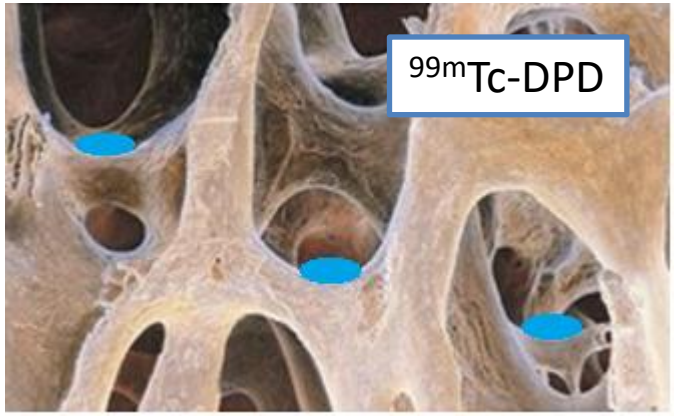

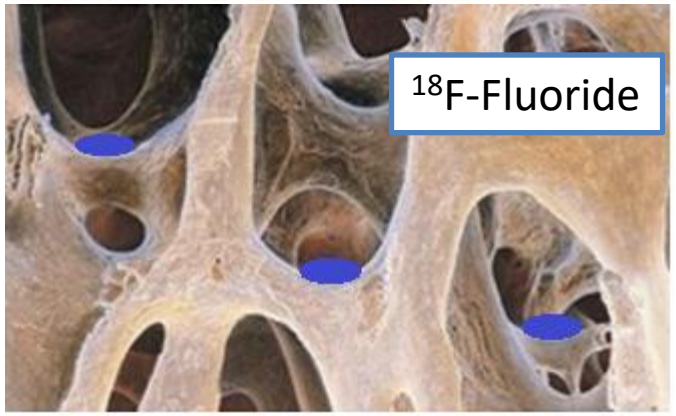

MOLECULAR BONE IMAGING: MECHANISMS

^{99m}Tc-diphosphonates BS and ^{18}F-Fluorine PET

- The imaging basis of bone imaging is the high affinity between ^{99m}Tc labeled phosphonates or fluorine and hydroxiapatite crystals
- These radiopharmaceuticals label viable bones, on the basis of a good vascular supply and osteoblast activity

- ^{18}F-Fluoride is an old and new tracer

Jones AG, Francis MD, Davis MA. Bone scanning: Radionuclidic reaction mechanisms. Semin Nucl Med 1976, Jan;6(1):3-18.
Grant FD, Fahey FH, Packard AB, Davis RT, Alavi A, Treves ST. Skeletal PET with 18F-fluoride: applying new technology to an old tracer. J. Nucl. Med. 2008 Jan;49(1):68–78.
Blau M, Nagler W, Bender MA. Fluorine-18: A new isotope for bone scanning. J Nucl Med 1962, Jul;3:332-4.
French RJ, McCready VR. The use of 18-F for bone scanning. Br J Radiol 1967, Sep;40(477):655-61.
Stansfield EC, Sheehy N, Zurakowski D, Vija AH, Fahey FH, Treves ST. Pediatric 99mTc-MDP bone SPECT with ordered subset expectation. Radiology 2010, 257:793–801
Segall G, Delbeke D, Stabin MG, Even-Sapir E, Fair J, Sajdak R, et al. SNM practice guideline for sodium 18f-fluoride PET/CT bone scans 1.0. J Nucl Med 2010, Nov;51(11):1813-20.

Adapted, http://slideplayer.com

Bone scintigraphy - Bone PET

- performed after injecting ^{99m}Tc-diphosphonates or ^{18}F-fluoride

with

- vascular, blood pool, planar, pin-hole,
- SPECT, SPECT-CT or PET-CT images

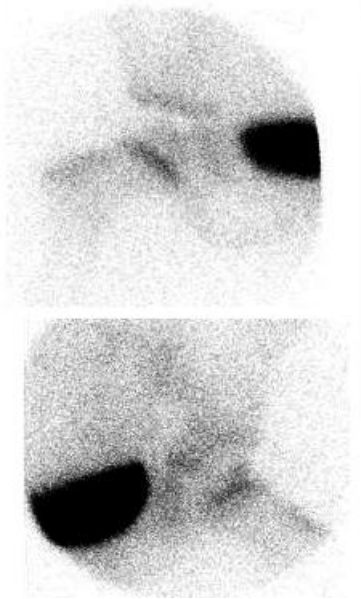

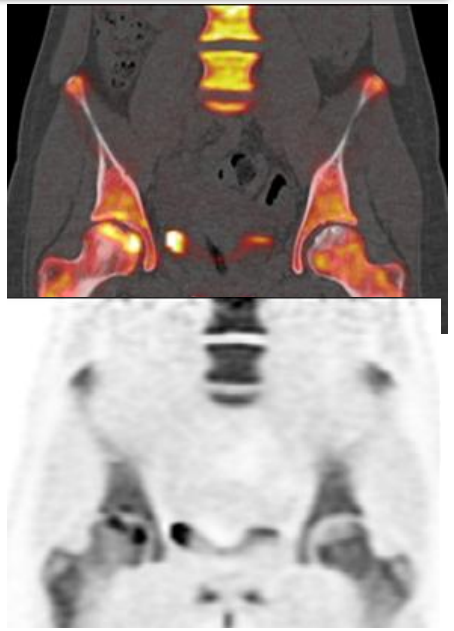

Stansfield EC, Sheehy N, Zurakowski D, Vija AH, Fahey FH, Treves ST. Pediatric 99mTc-MDP bone SPECT with ordered subset expectation. Radiology 2010, 257:793–801
Sarikaya I, Sarikaya A, Holder LE. The role of single photon emission computed tomography in bone imaging. Semin Nucl Med 2001, Jan;31(1):3-16.

3 PHASE BONE SCAN

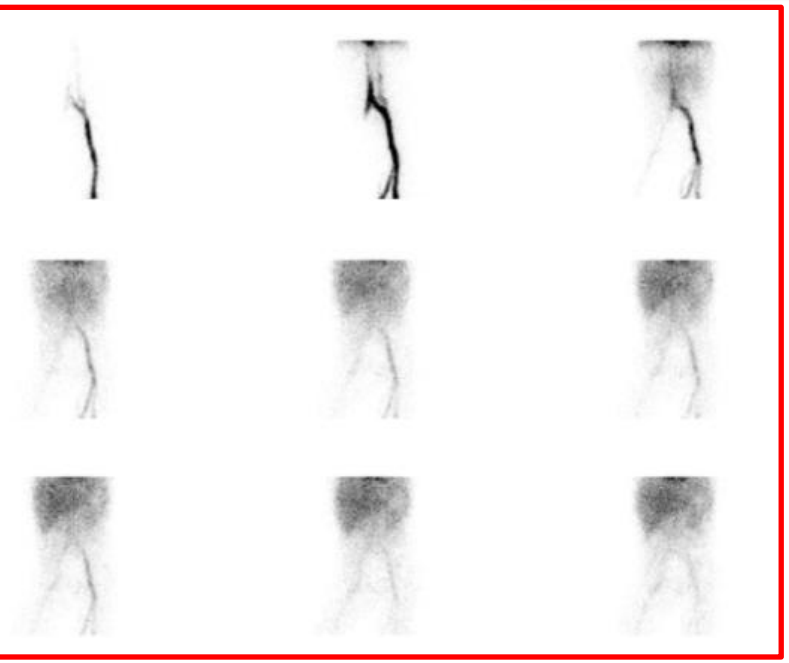

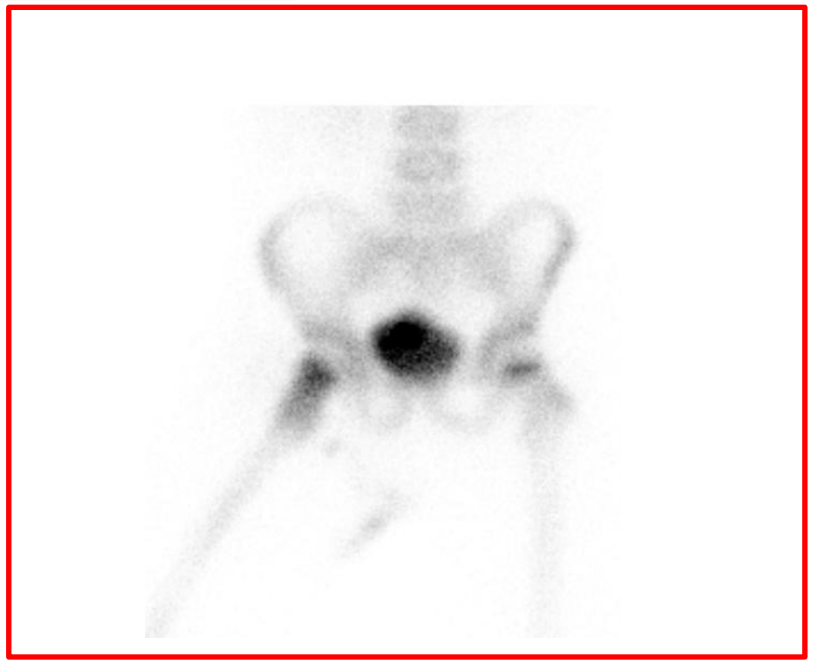

VASCULAR IMAGES

the vascular phase should be obtained 30-60 seconds after the IV tracer injection.

This phase will help us to detect focal or diffuse hyperemia, differentiating between arterial and venous compounds.

BLOOD POOL IMAGES

Should be obtained as soon as possible after the IV injection, and always before the first 3 or 4 minutes after injection of the tracer.

Bone uptake due to rapid bone metabolism in children promptly masks the blood pool activity.

PLANAR BONE IMAGES

Standard of reference. Image resolution is cornerstone in children:

- Higher resolution:
  spot frames > whole body
- Positioning the child **close to the collimator:** ↑resolution and ↓adquisition time.

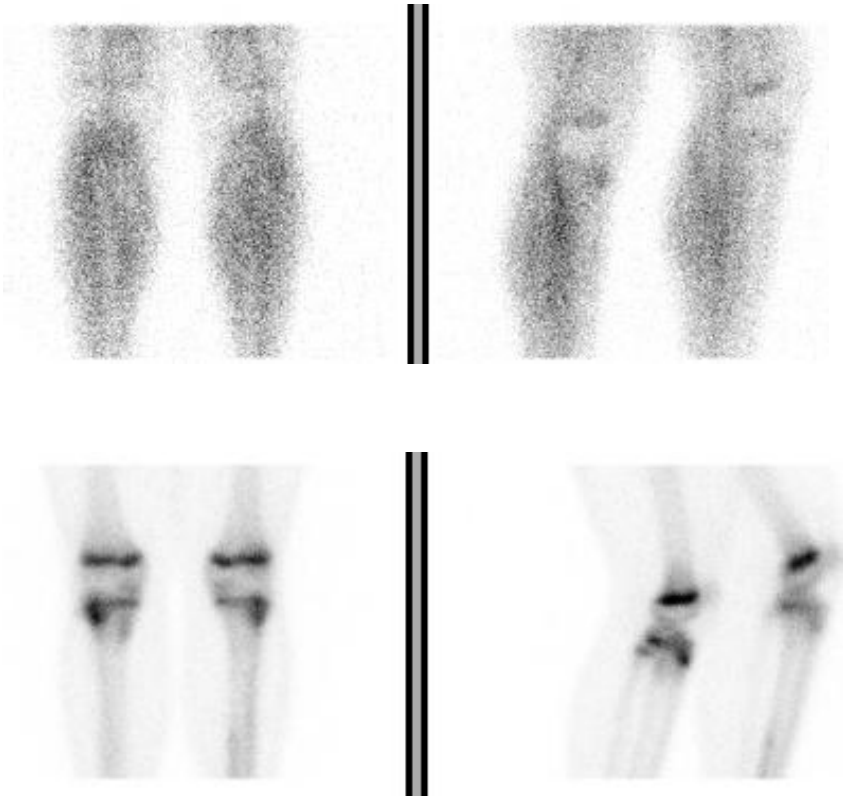

SPECT and SPECT-CT increase diagnostic accuracy and permit a more precise anatomic localization of the lesion

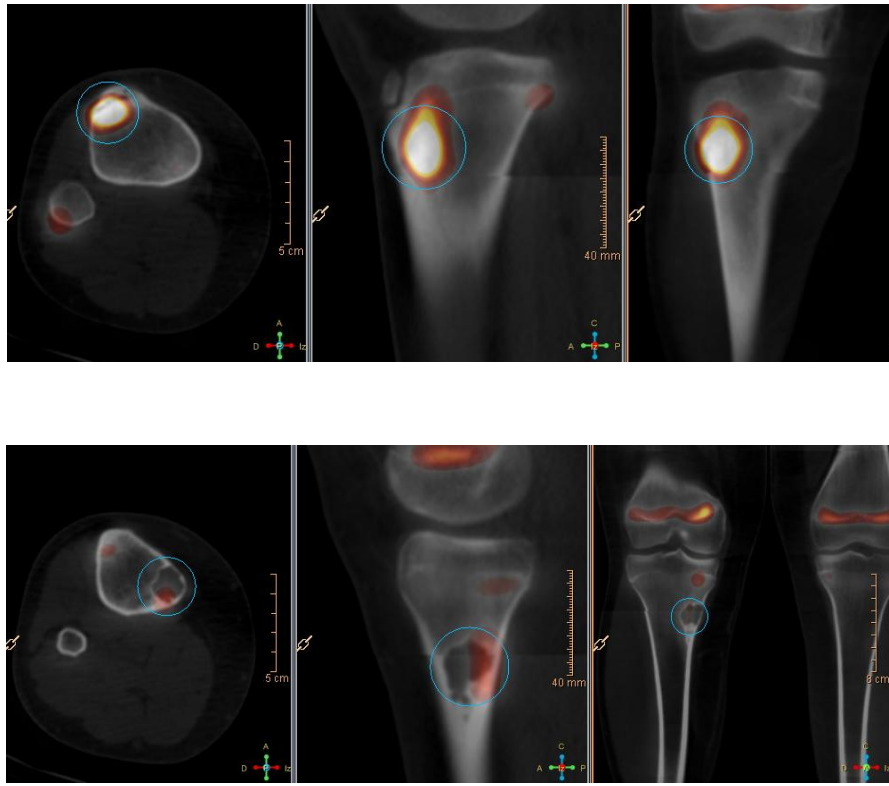

Severe Osgood-Slatter with bony pulling and separate bone cyst

Blood pool

Planar bone image

Pin-hole images

PIN-HOLE

Pin-hole images are the **highest resolution** images that can be produced with a gammacamera.
By magnification the area of interest with a pinhole collimator we can reach even higher resolution than with conventional planar or SPECT images.

The limitations are:

- the unavailability of this kind of collimator
- the time consuming and the immobilization required obtaining high resolution images (5-10 min).

Positioning of the patient, evaluation of small size lesions or lesions located in small peripheral joints are also limitations for the use of pinhole imaging.

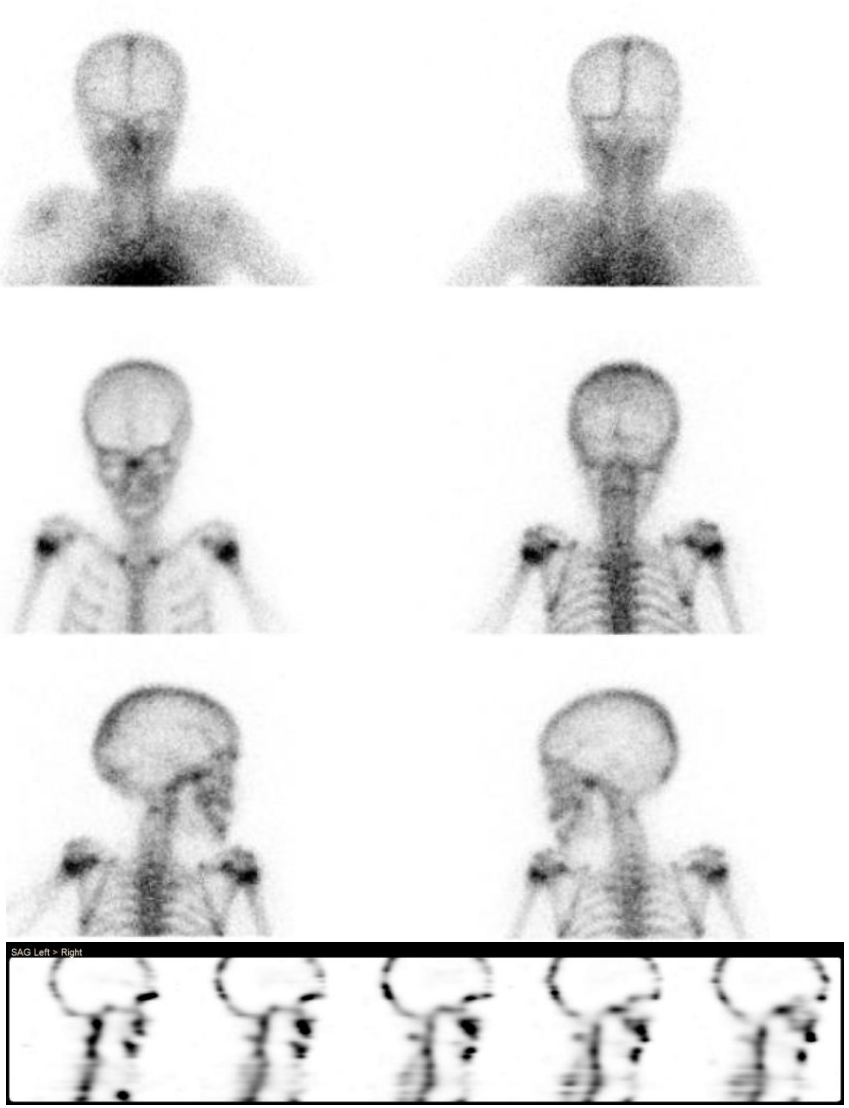

SPECT and SPECT-CT

- SPECT is complementary to planar images
- SPECT and SPECT-CT are replacing pin-hole images in most depts

- Higher sensitivity in detecting vertebral lesions: mandatory in cases of back pain even when the planar images show no abnormal uptake

- Low dose CT is mandatory
- SPECT-CT in Pediatrics should be strictly limited given its radiation burden

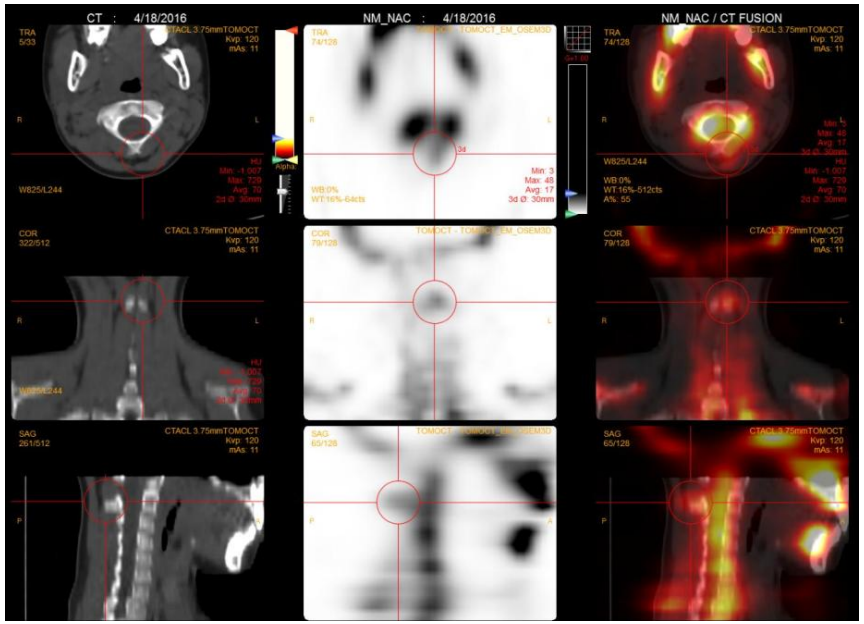

Cervical Vertebra Fracture

Stansfield EC, Sheehy N, Zurakowski D, Vija AH, Fahey FH, Treves ST. Pediatric 99mTc-MDP bone SPECT with ordered subset expectation. Radiology 2010, 257:793–801

TUMOR

TRAUMA

INFECTION

PET/CT and SARCOMA

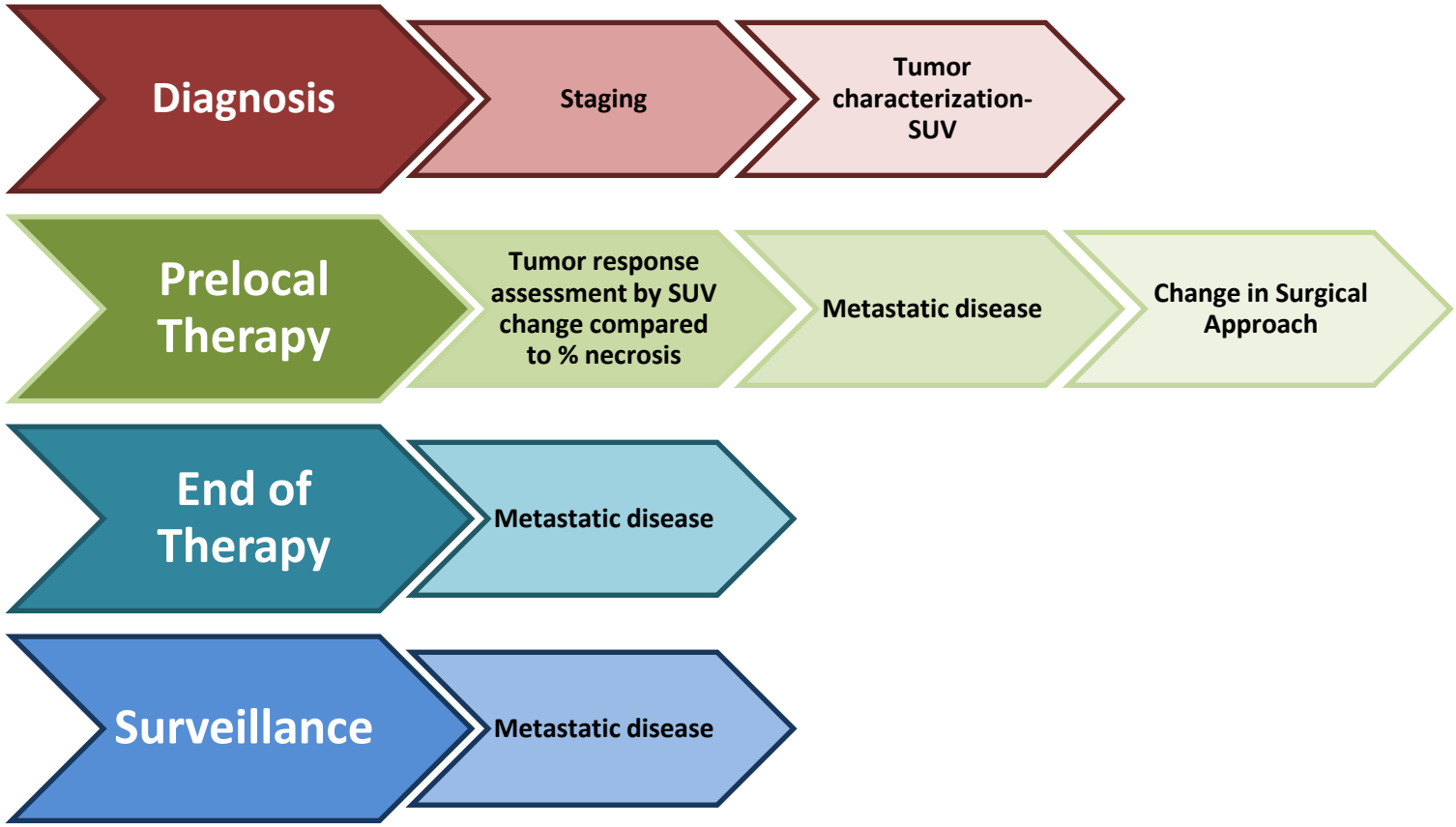

Meyer JS, Nadel HR, et al.
Imaging guidelines for children with Ewing sarcoma and osteosarcoma: a report from the Children's Oncology Group Bone Tumor Committee.
Pediatr Blood Cancer. 2008 Aug;51(2):163-70.

MRI vs. FDG PET:
Response in Ewing Tumors
Good Responder

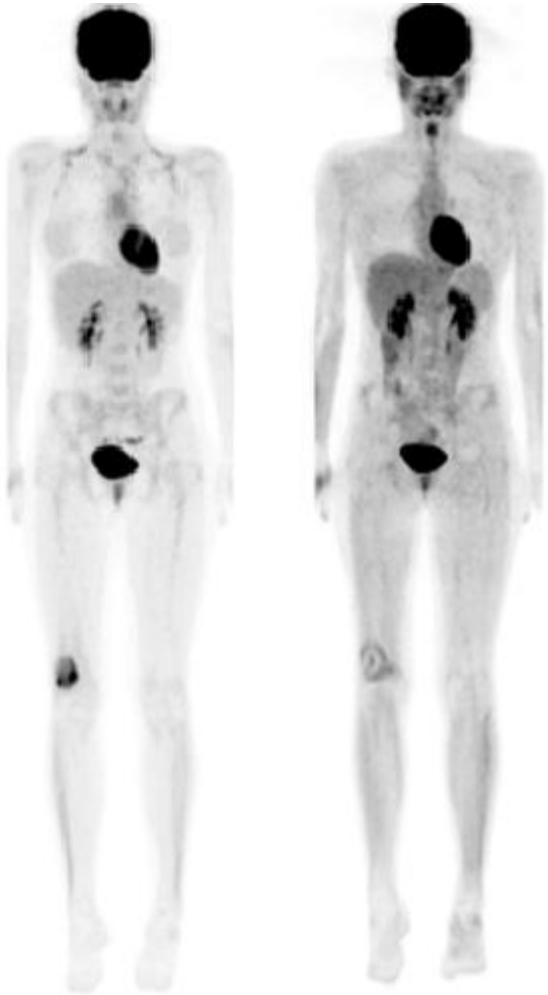

SUVmax
8.3

SUVmax
1.8

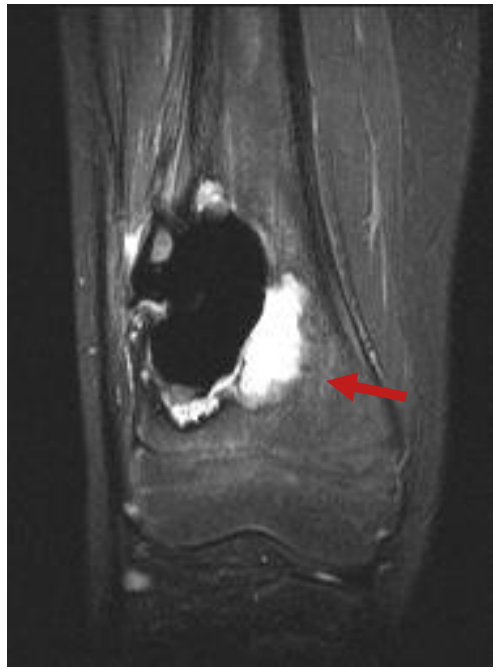

Post chemo pre surgery

Denecke T et al.
Assessment of histological response of paediatric bone sarcomas using FDG PET in comparison to morphological volume measurement and standardized MRI parameters.
Eur J Nucl Med Mol Imaging. 2010 Oct;37(10):1842-53

Metabolic Response in Ewing Sarcoma

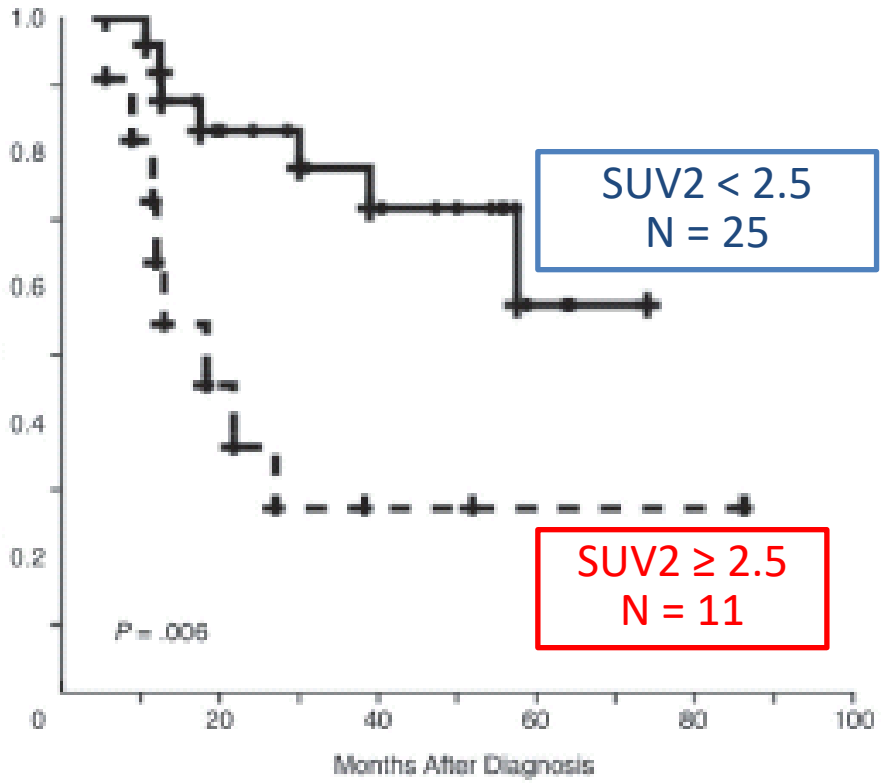

Hawkins DS, Schuetze SM, Butrynski JE, Rajendran JG, Vernon CB, Conrad EU 3rd, Eary JF.
[18F]Fluorodeoxyglucose positron emission tomography predicts outcome for Ewing sarcoma family of tumors.
J Clin Oncol. 2005 Dec 1;23(34):8828-34

Unexpected Focal ES Metastatic Disease Progression

MDP Bone Scan

FDG-PET

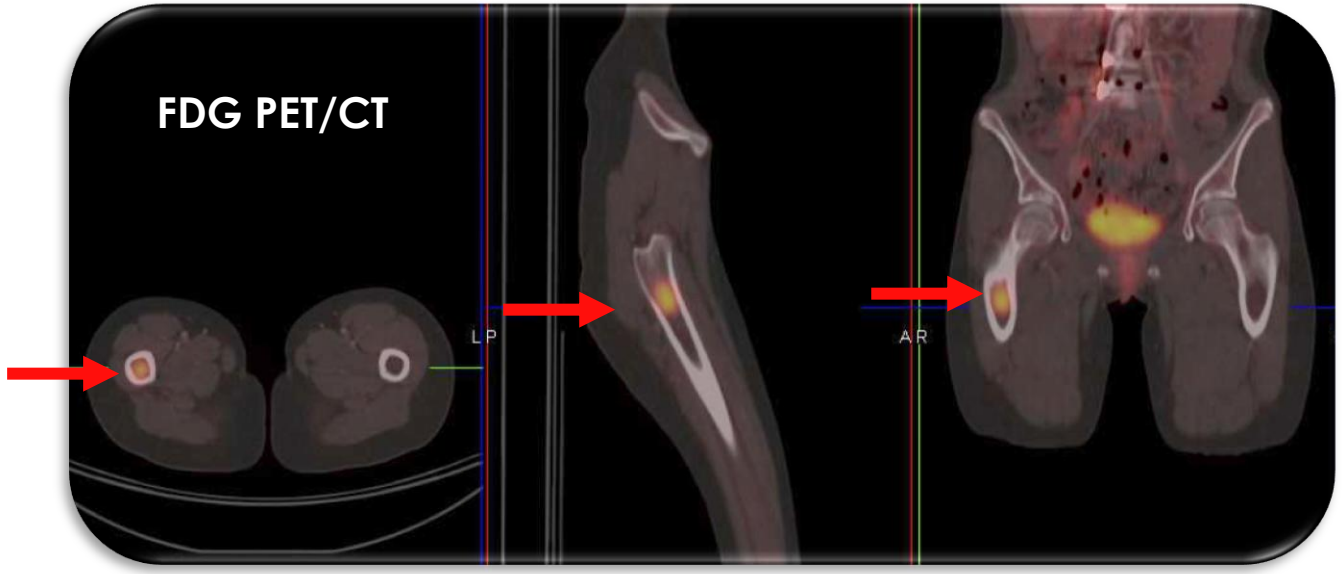

Incorporemos el PET al estudiar la extensión de tumor/ infección

Unexpected Focal RMS Metastatic Disease Progression

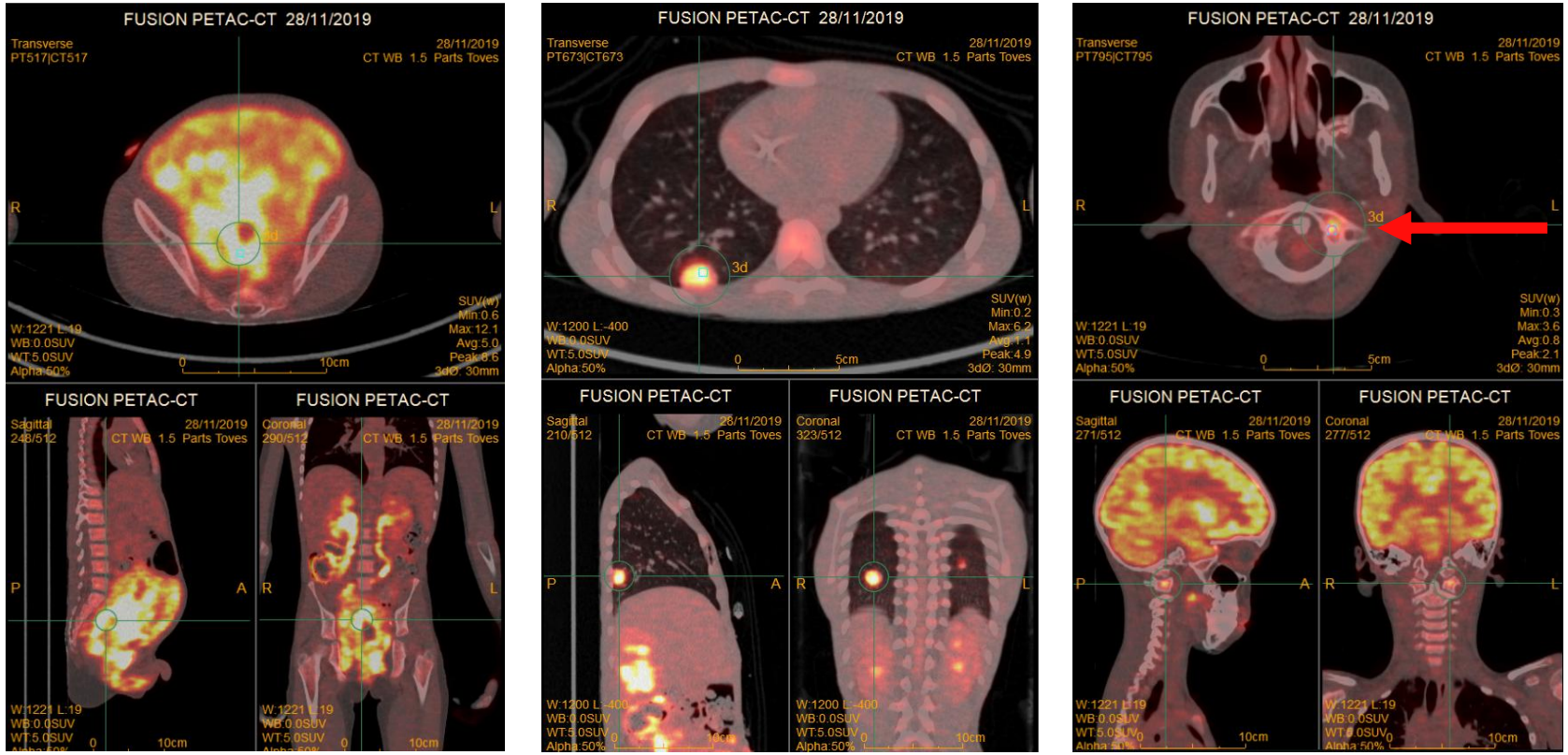

SARCOMA - OSTEOSARCOMA

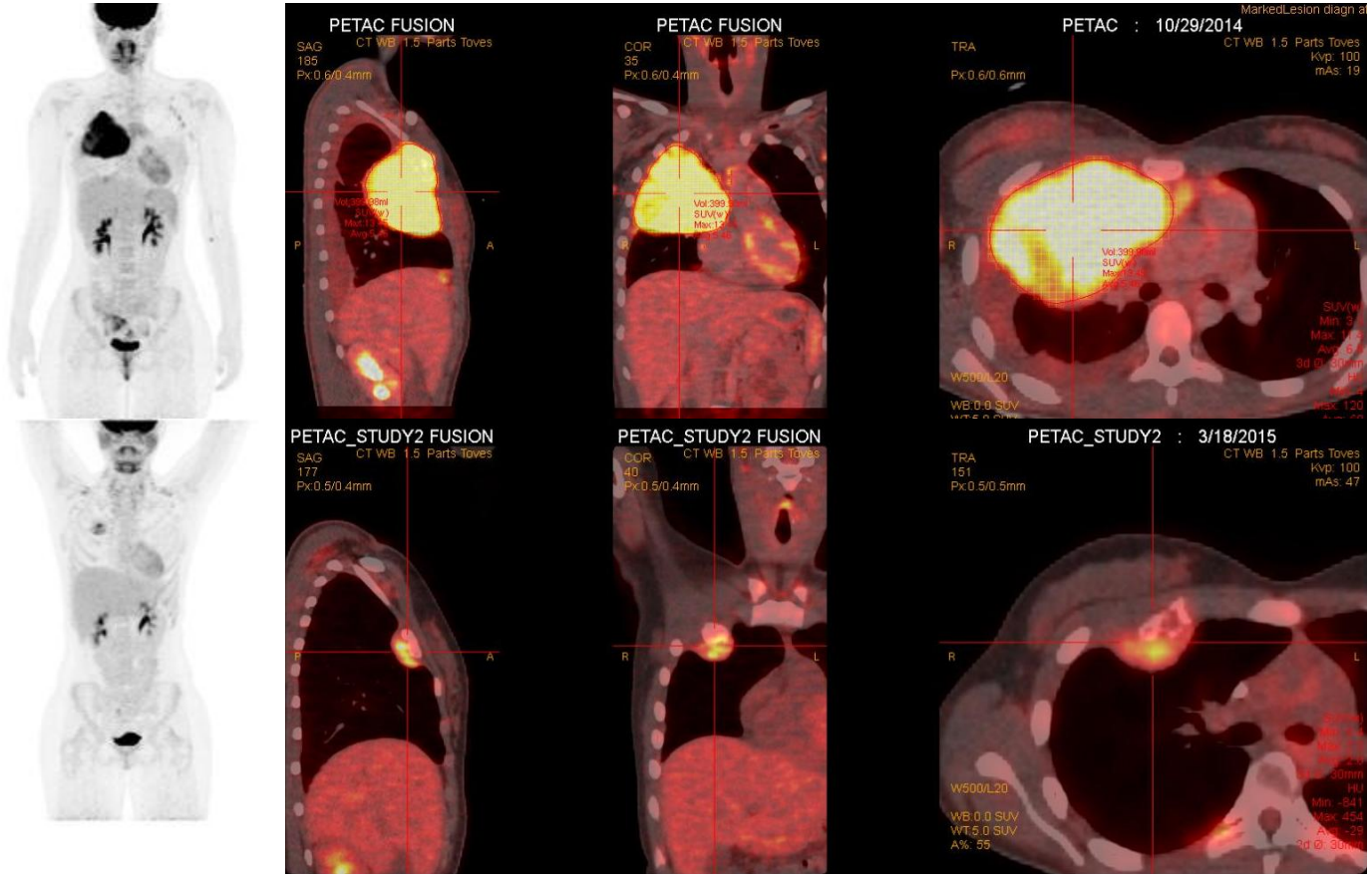

Incorporemos el PET al estudiar la extensión de tumor/ infección

CHEMOTHERAPY RESPONSE - QUANTIFICATION

^{18}F-FDG

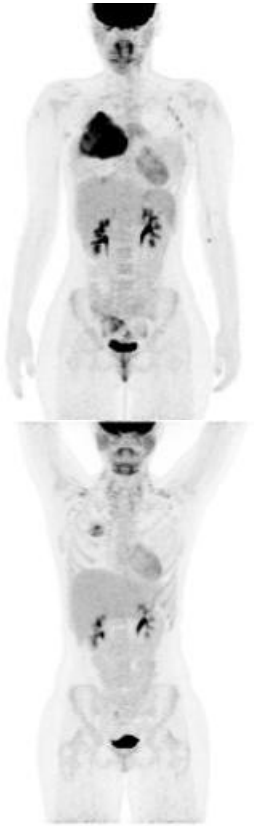

Lesion Volume:

Study Date	Lesion Volume (ml)	
29/10/2014	399,98	1,7%
18/03/2015	6,67	

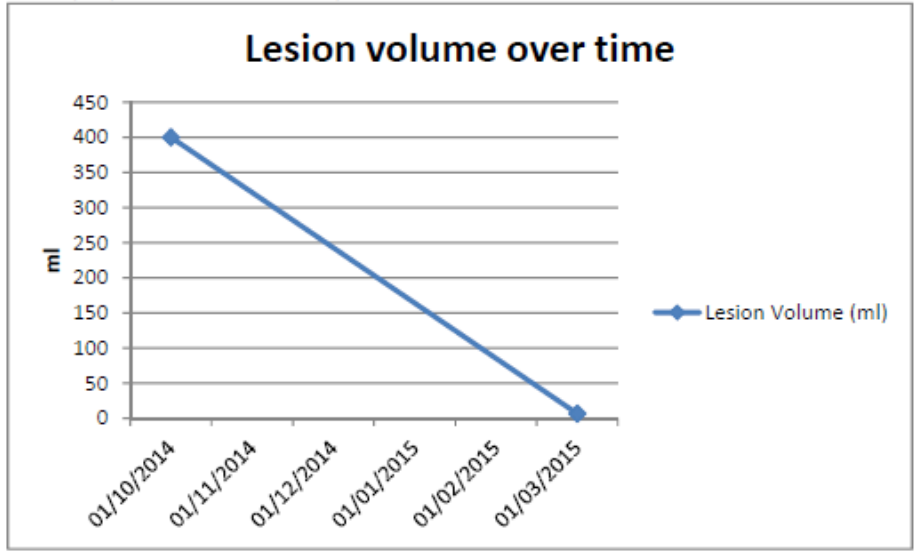

Functional Statistics:

Study Date	Mininum	Maximum	Average	Total
29/10/2014	2	13,45	5,46	2.184,97
18/03/2015	2	7,2	2,97	19,81

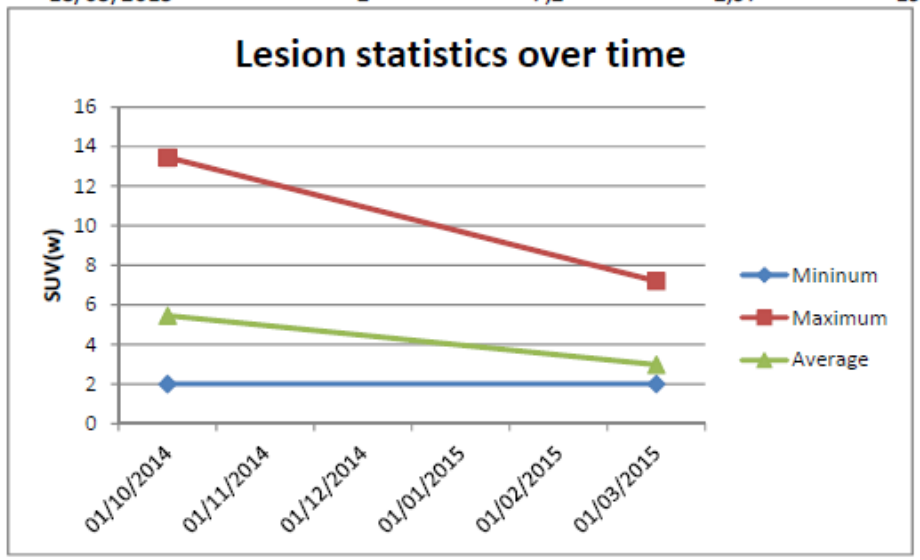

Incorporemos el PET al estudiar la extensión de tumor/ infección

THYMUS CARCINOMA

- DIAGNOSTIC
- PROGRESSION

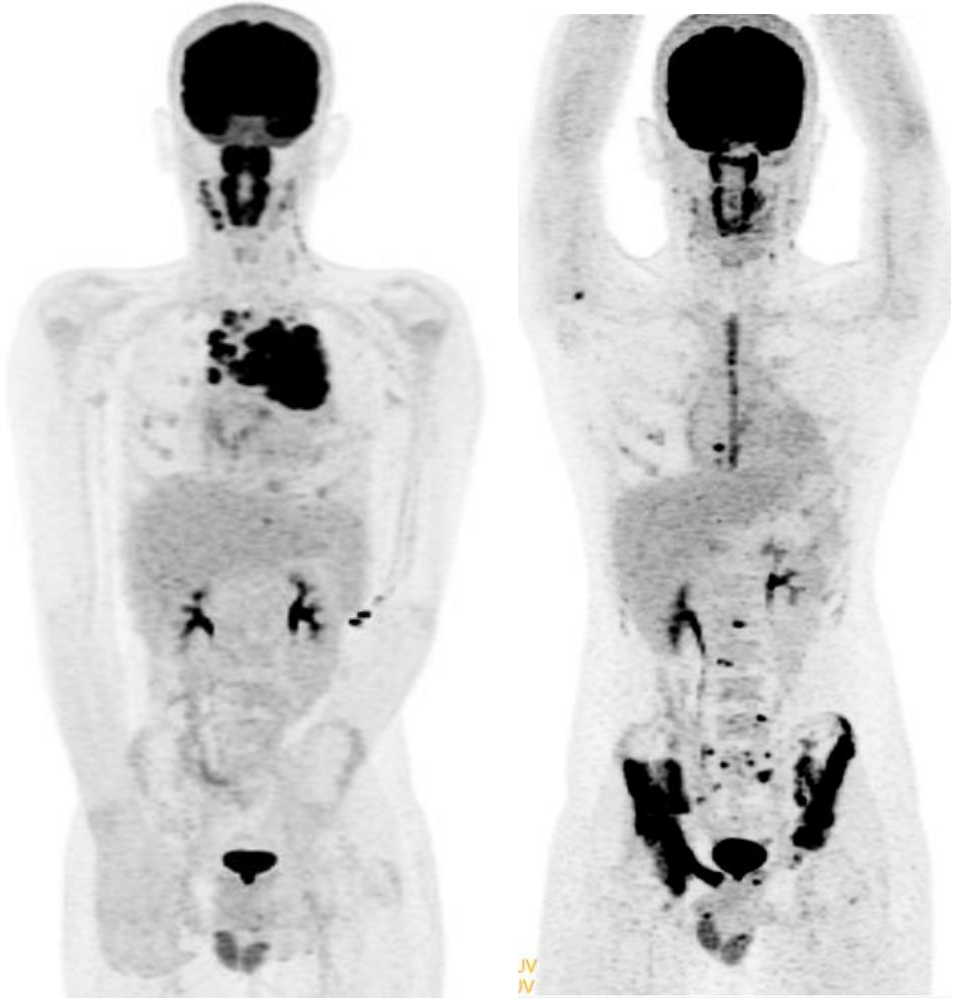

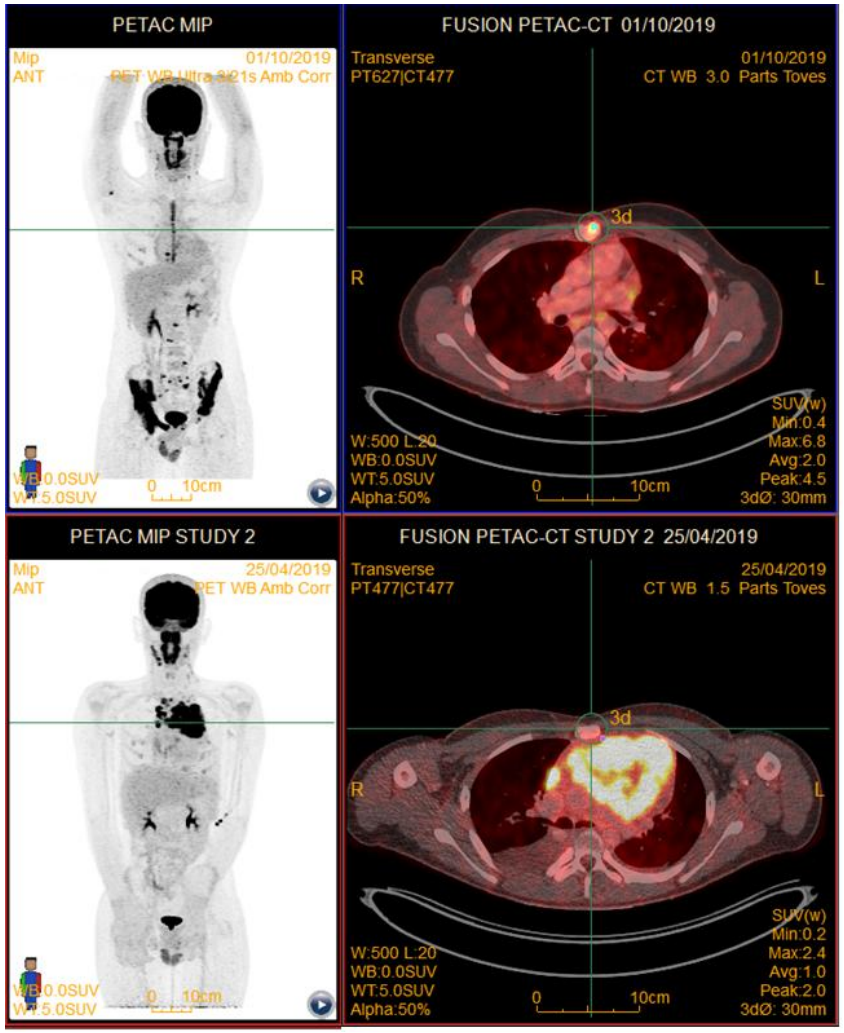

Incorporemos el PET al estudiar la extensión de tumor/ infección

THYMUS CARCINOMA

- DIAGNOSTIC
- PROGRESSION

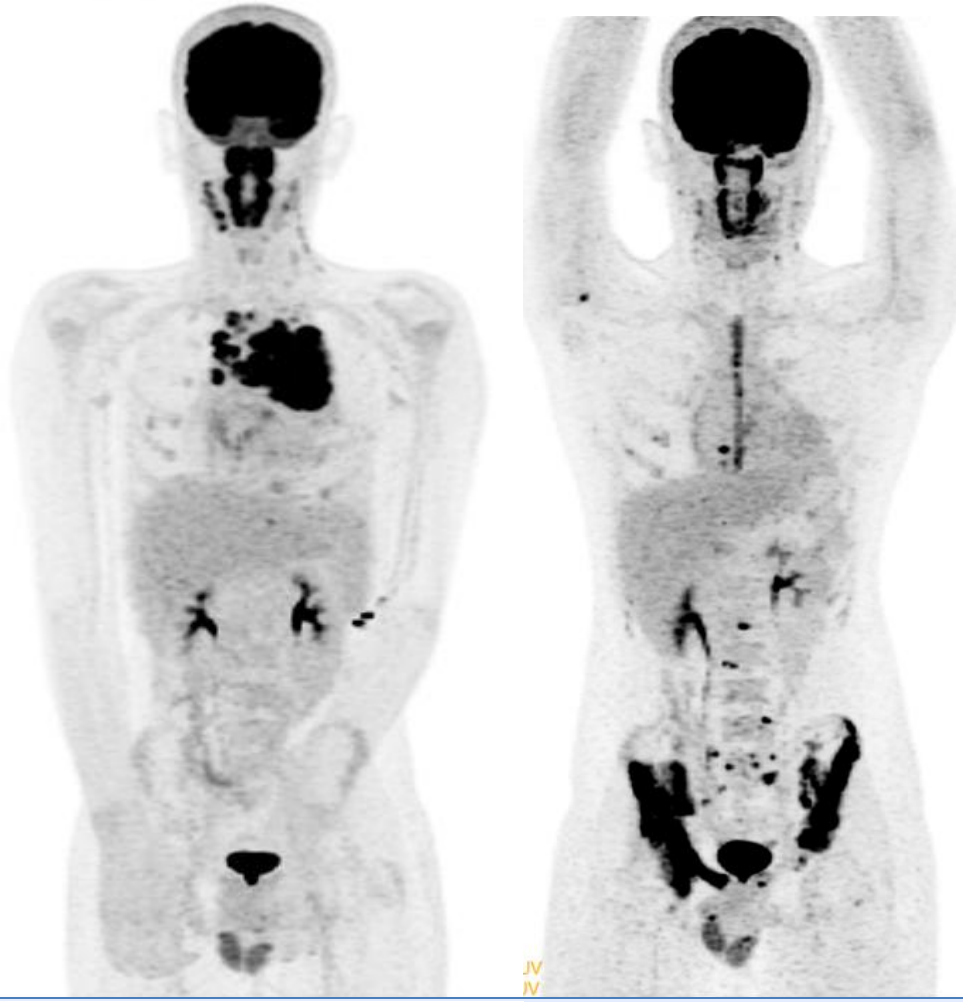

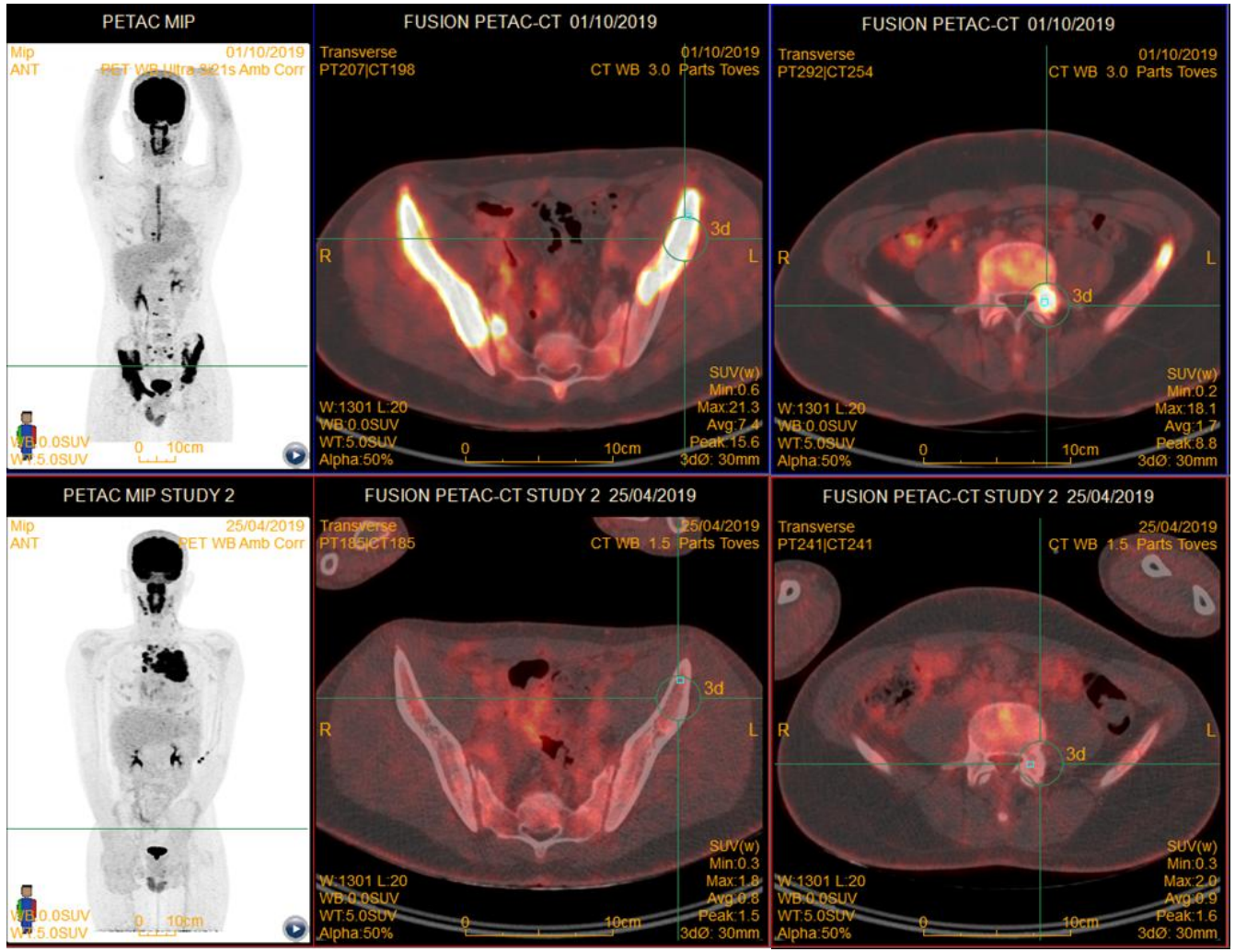

Incorporemos el PET al estudiar la extensión de tumor/ infección

PROTHESIS
Osteosarcoma

- BP image
- SPECT-CT is crucial

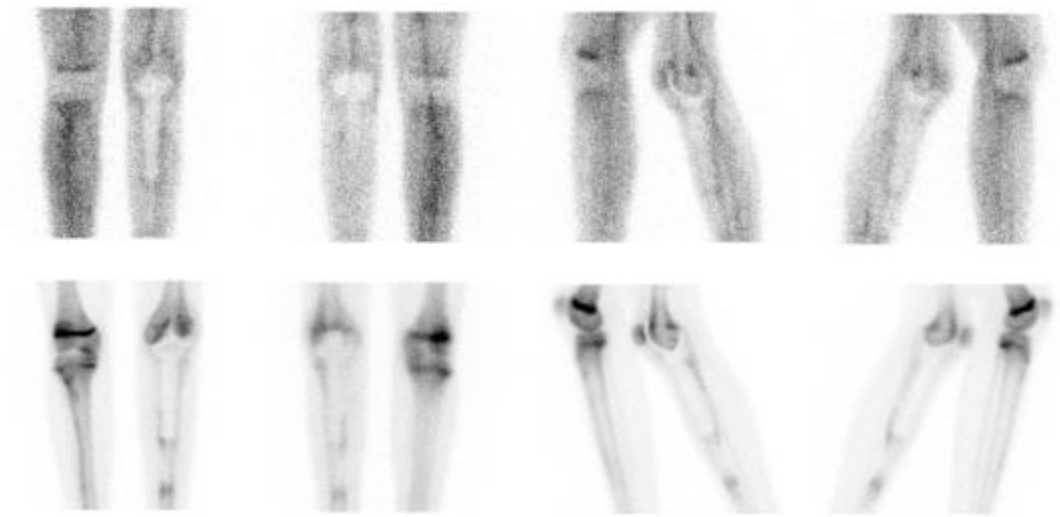

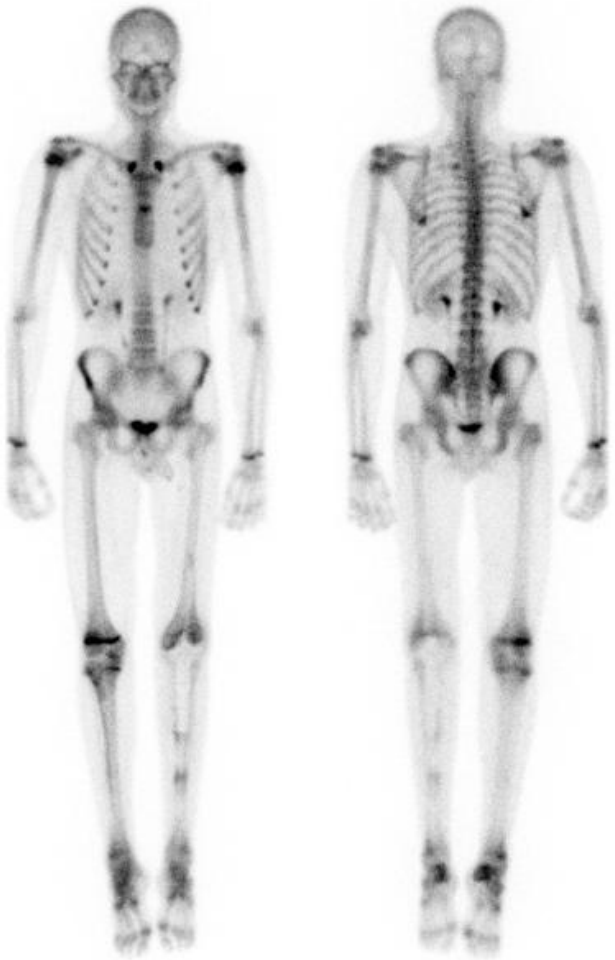

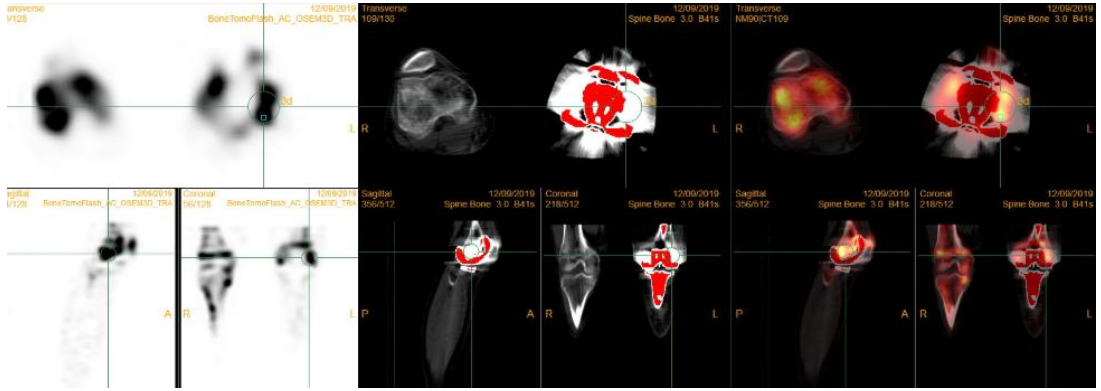

Male, 6 months, Soft tissue swelling on head and skin lesions.
Skin lesions: pink maculo-papules 3mm, grouped in both iliac fossae.
Erythematous plaques in inguinal folds, perianal and intergluteal regions.

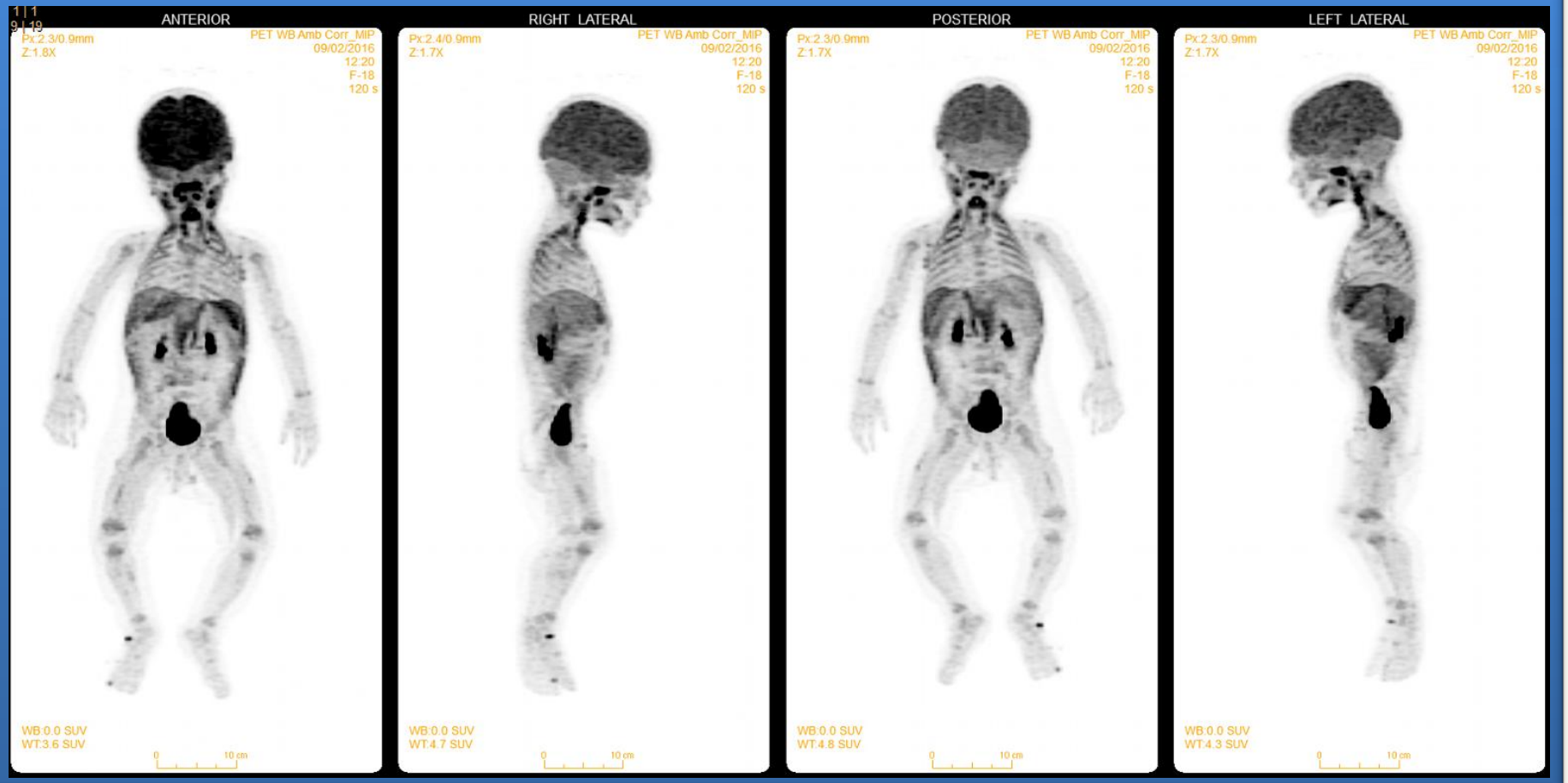

Incorporemos el PET al estudiar la extensión de tumor/ infección

Male, 6 months, Soft tissue swelling on head of about 2-3 cm diameter.

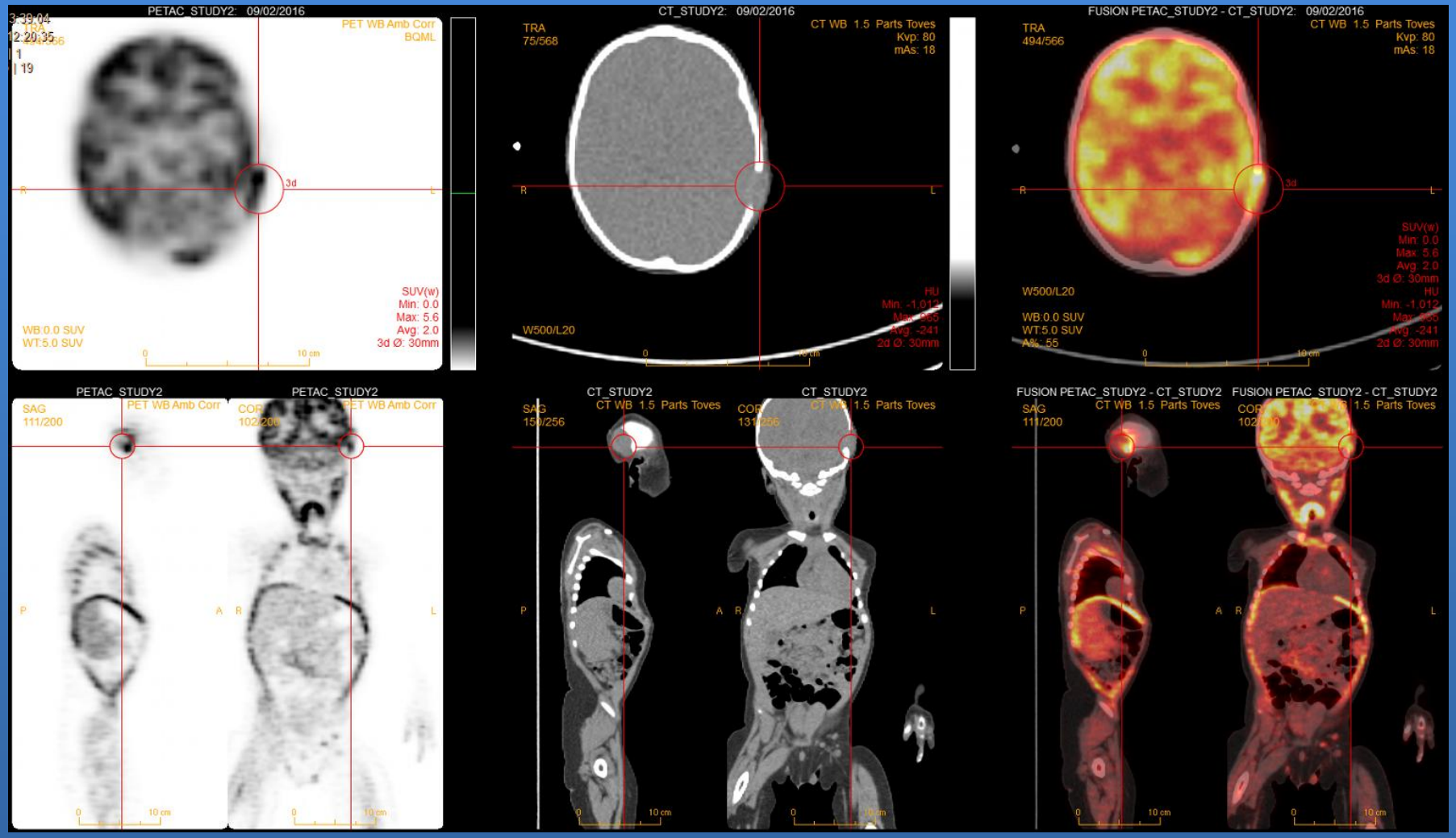

Incorporemos el PET al estudiar la extensión de tumor/ infección

Male, 6 months, Soft tissue swelling on head of about 2-3 cm diameter.

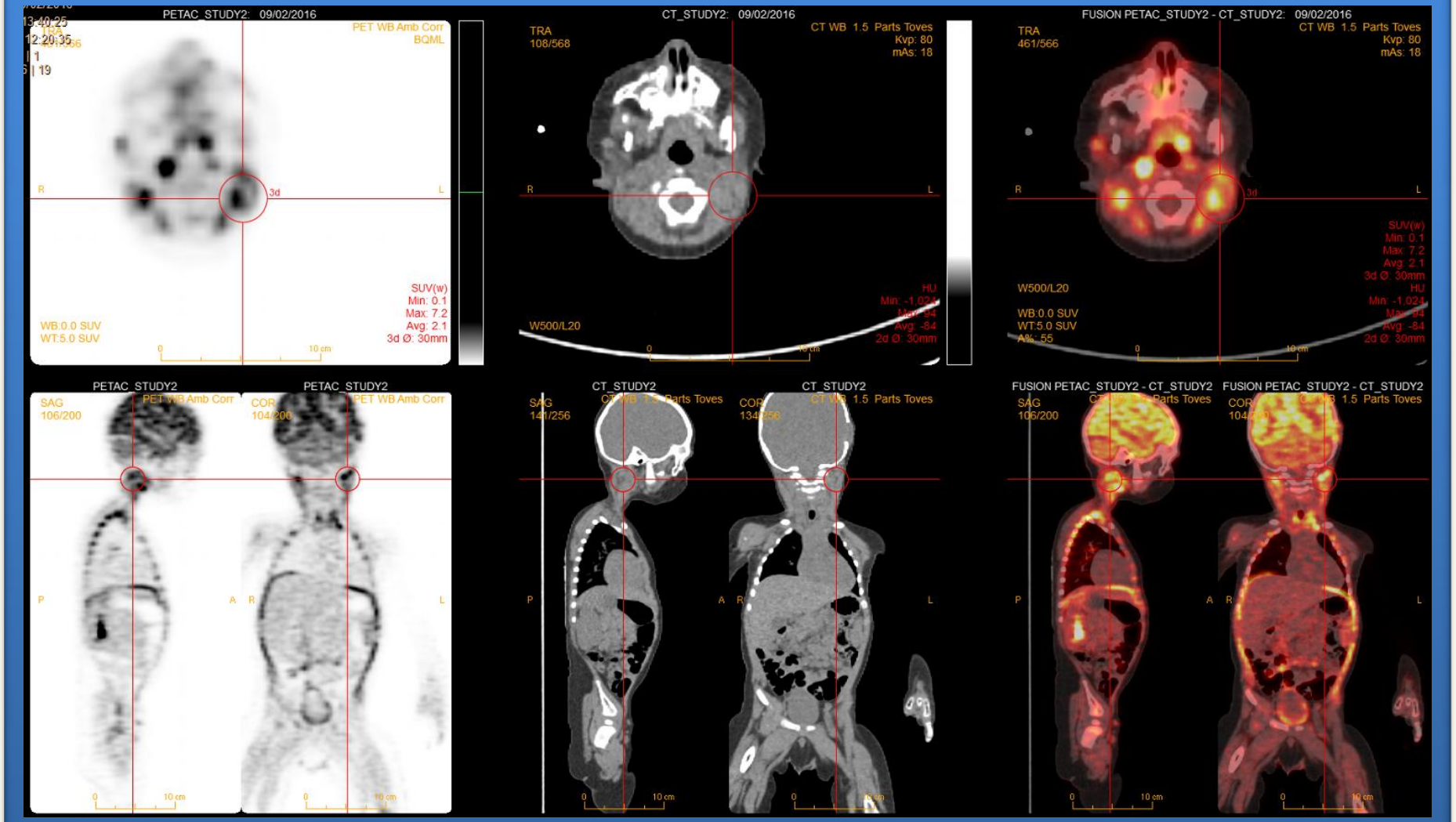

LCH multisystem

- Bone
- Lymph nodes

Incorporemos el PET al estudiar la extensión de tumor/ infección

TRAUMA

DORSAL / LUMBAR PAIN: SPONDYLOLYSIS?

Bone SPECT has higher SENSITIVITY to detect lesions than planar images ....

NORMAL

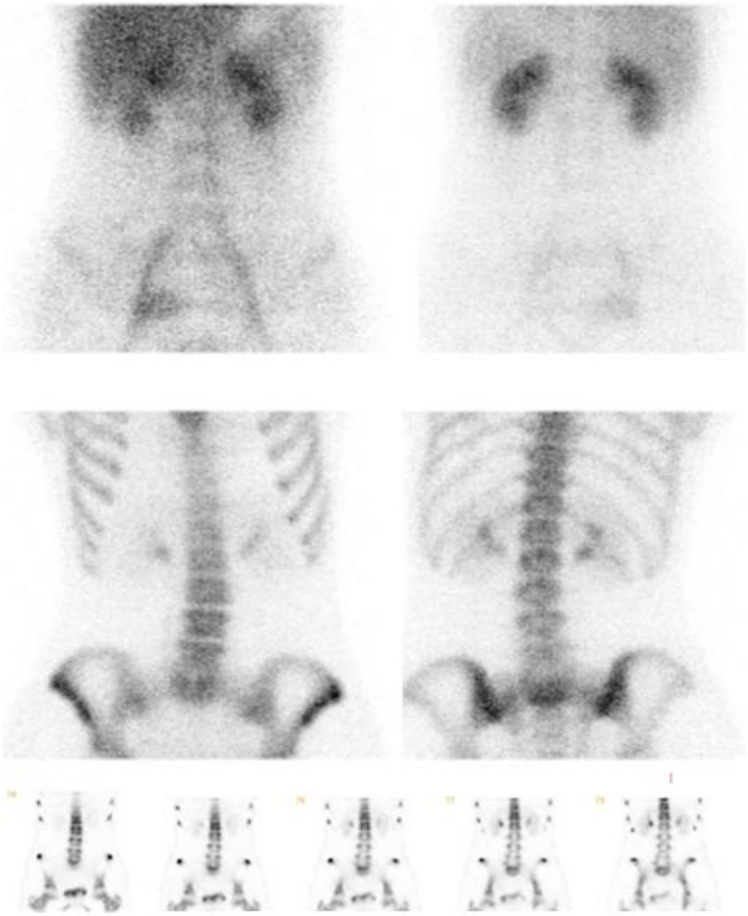

UNILATERAL SPONDYLOLYSIS

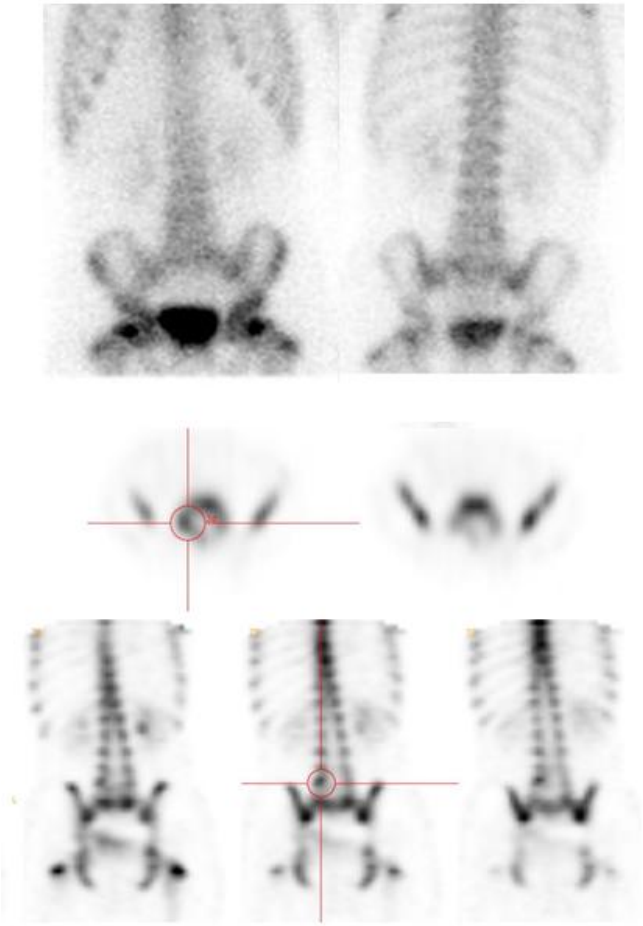

BILATERAL SPONDYLOLYSIS

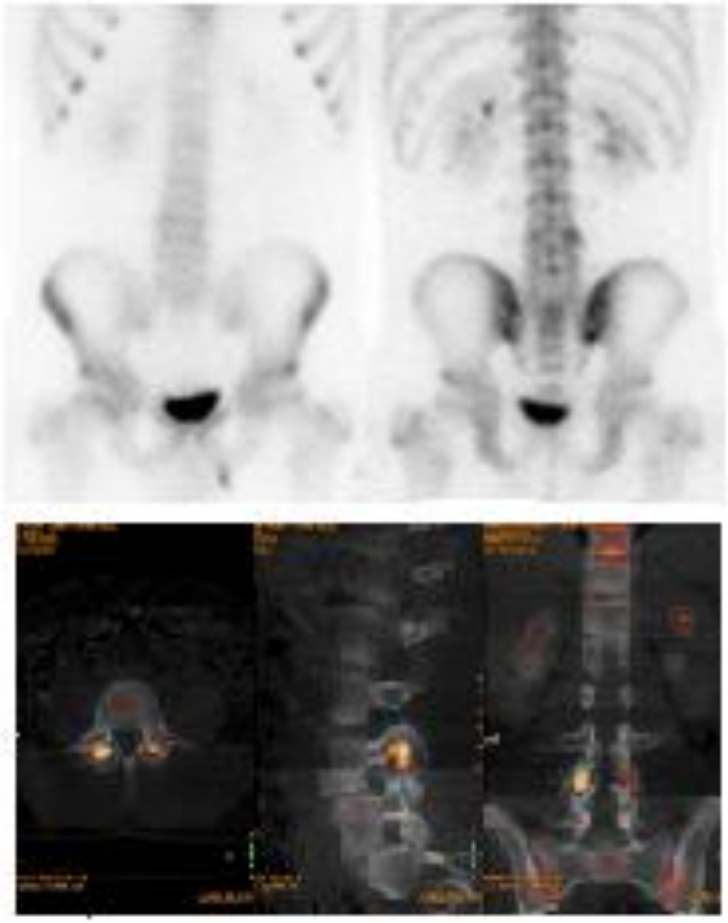

Incorporemos el PET al estudiar la extensión de tumor/ infección

BILATERAL SPONDYLOLYSIS

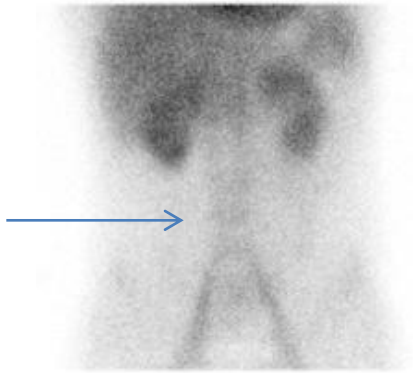

LUMBAR PAIN

17 y, football player. Back pain.

- BP: doubtfull
- BS: hyperactivity right area L4
- SPECT-CT: BILATERAL SPONDYLOLYSYS

BILATERAL SPONDYLOLYSIS - BONE PET

12 year old female

April 2017:
Basketball player
Lumbar right back pain, since 1 months ago
Mechanic pain.
No fever, no trauma.
Pain stops with rest and antiinflamatory drugs

No other medical records of interest

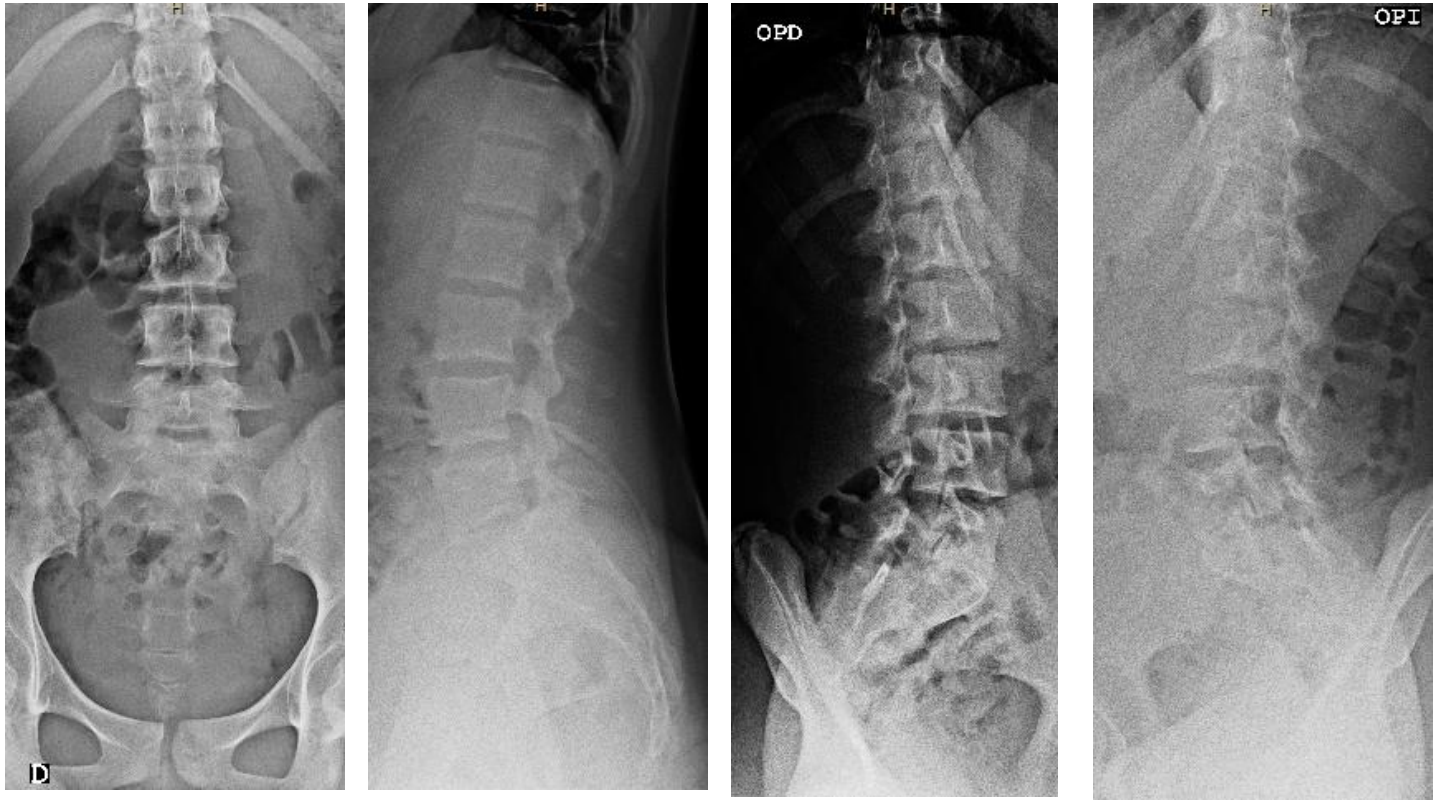

XR: 12.04.2017
Pelvic and lumbar images without significant abnormalities

BILATERAL SPONDYLOLYSIS - BONE PET

Bone PET images:
-3-min/bed
-Whole body
-45 min after 18F injection

Increased fluorine bone uptake in:

-Pars articularis of L4-L5, BILATERAL

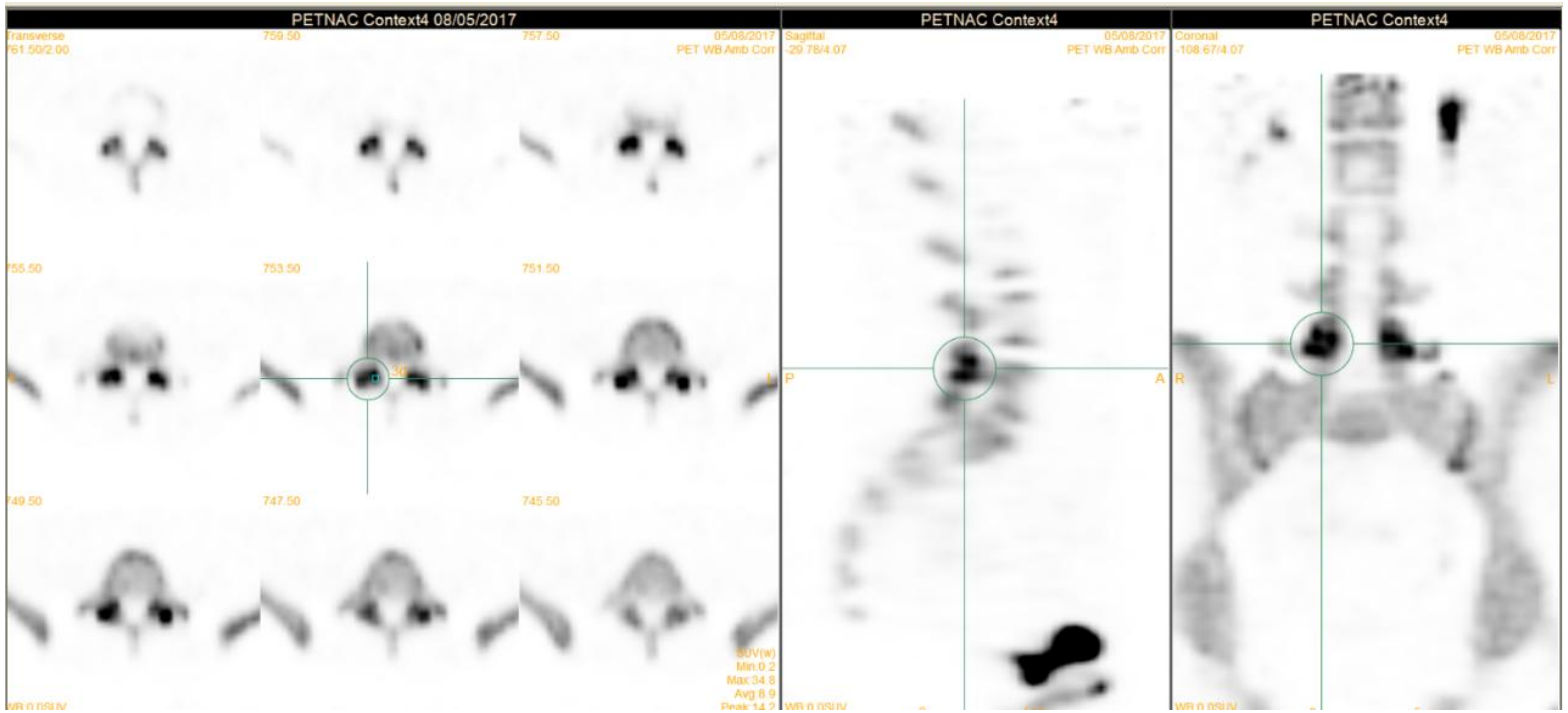

BILATERAL SPONDYLOLYSIS - BONE PET

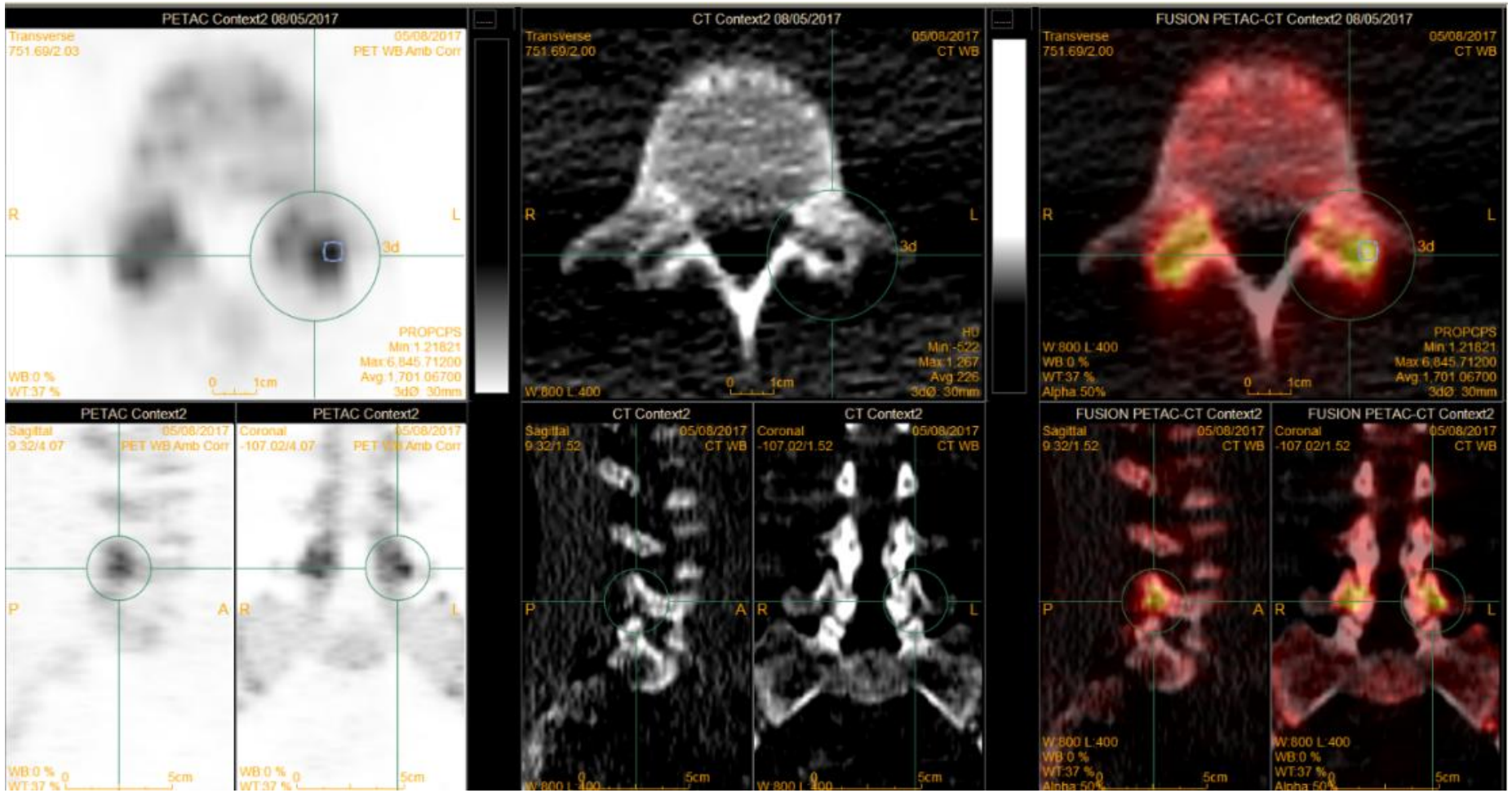

Low dose CT only in the region of interest to avoid unnecessary irradiation

Incorporemos el PET al estudiar la extensión de tumor/ infección

BONE PET - more findings…

SHIN SPLINTS

uptake in the cortical of both shins, specially in the right one

stress fractures

Which are the advantages and limitations of NaF PET/CT in comparasion to Tc-99m MDP?

ADVANTATGES

- The radiation is less than bone scintigraphy
- Has better image quality
- The duration of the study is less

LIMITATIONS

- Has a higher cost
- Less availability

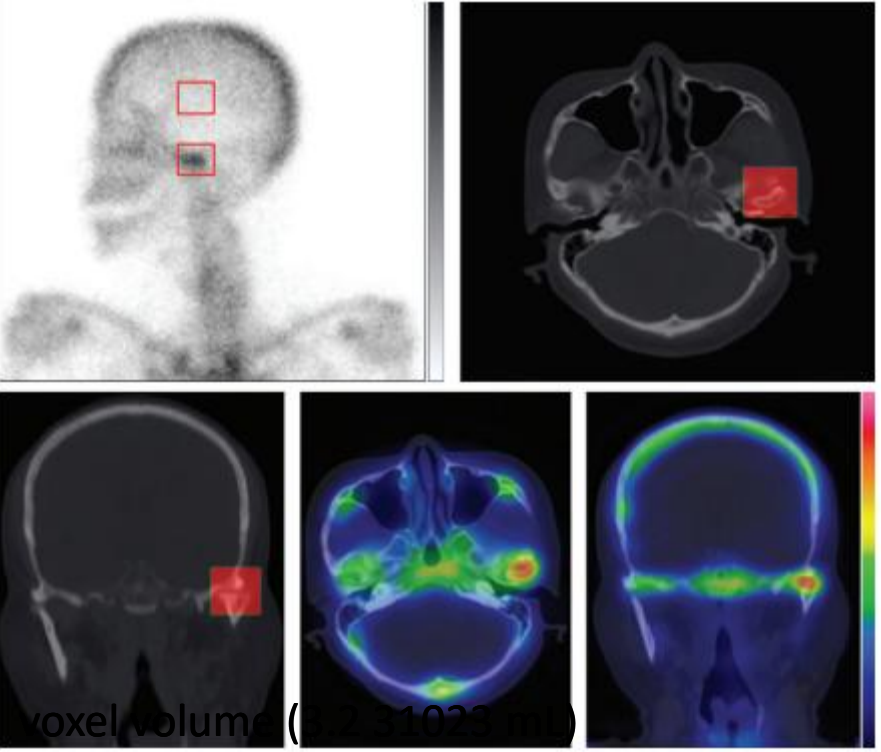

TEMPOROMANDIBULAR JOINT DISORDER

Visual assessment

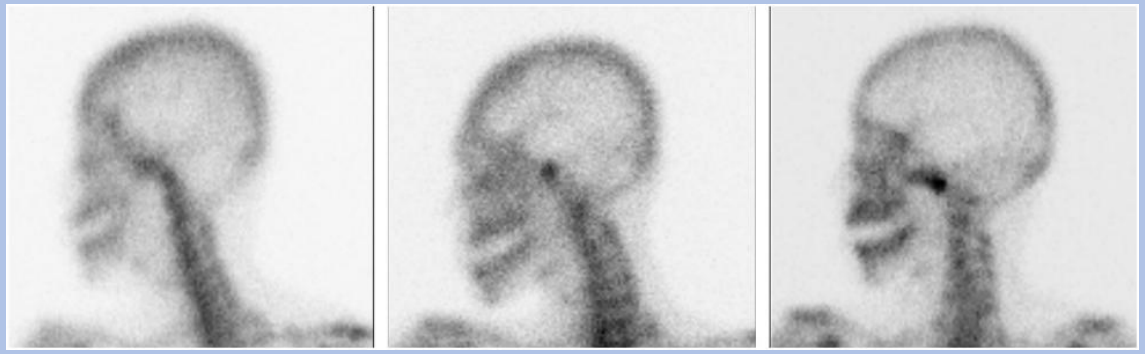

Normal | Mild-Moderate | Severe

Quantitative assessment

$$RR = \frac{\text{TMJ counts}}{\text{background counts}}$$

$$SUVmean = \frac{\text{total radioactivity / VOI volume}}{\text{injected radioactivity / body weight}}$$

$$SUVmax = \frac{\text{maximum radioactivity / voxel volume}}{\text{injected radioactivity / body weight}}$$

Voxel volume 3,2x10-3 mL

Suh MS, Lee WW, Kim YK, Yun PY, Kim SE. Maximum Standardized Uptake Value of (99m)Tc Hydroxymethylene Diphosphonate SPECT/CT for the Evaluation of Temporomandibular Joint Disorder. Radiology. 2016 Sep;280(3):890-6.

TEMPOROMANDIBULAR JOINT DISORDER

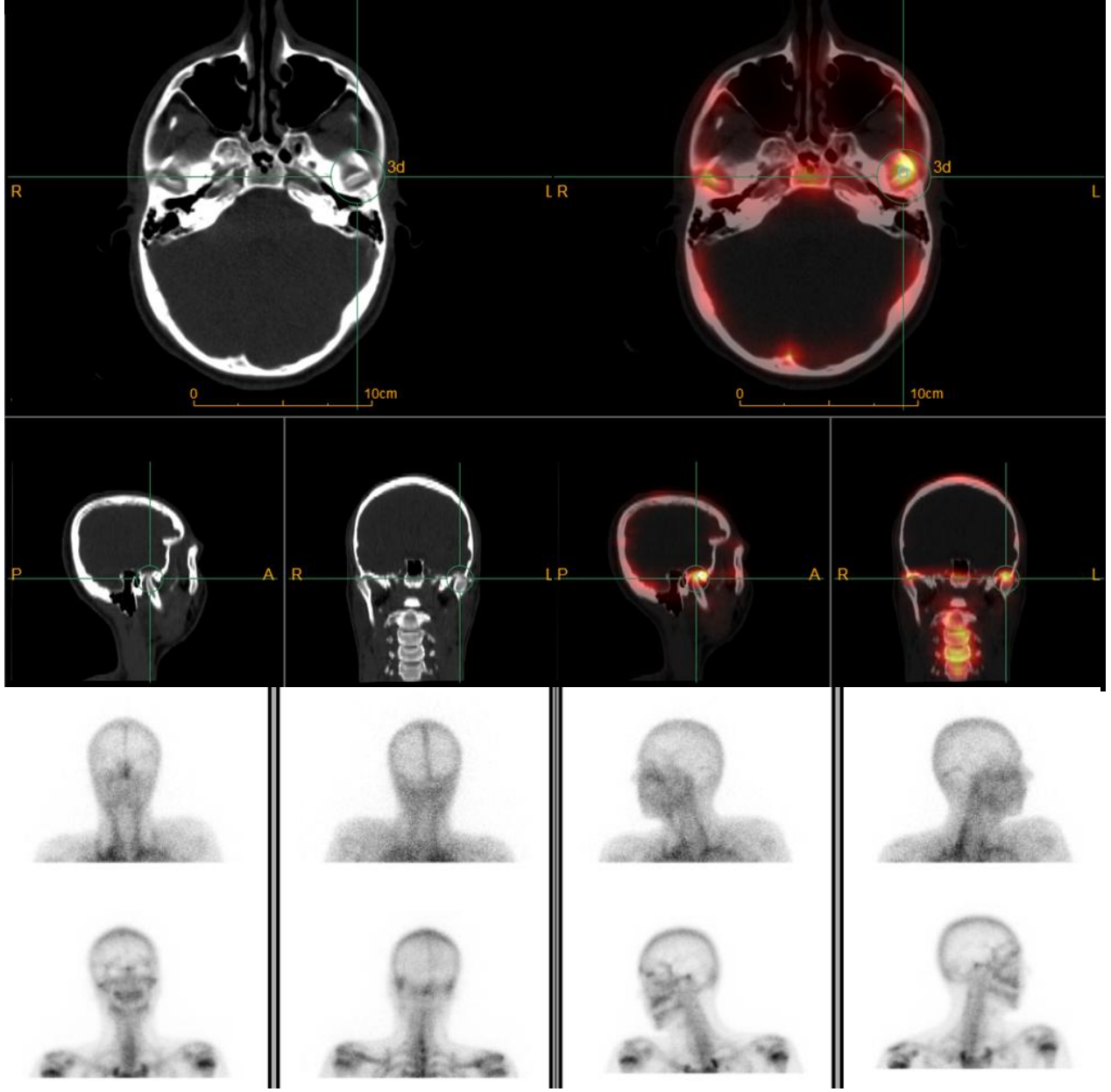

Suh MS, Lee WW, Kim YK, Yun PY, Kim SE. Maximum Standardized Uptake Value of (99m)Tc Hydroxymethylene Diphosphonate SPECT/CT for the Evaluation of Temporomandibular Joint Disorder. Radiology. 2016 Sep;280(3):890-6.

OSTEONECROSIS

Osteonecrosis is a pathological process in which the compromise of bone vasculature leads to the death of bone cells, and ultimate mechanical failure.

Non traumatic avascular osteonecrosis is a well-reported complication of corticosteroid treatment for immunologic and malignant diseases in children.

In epiphyseal areas, where there is a terminal vascular supply, the extent of the necrotic area is related to the evolution to joint collapse and further degenerative changes.

In cases of avascular necrosis and osteochondrosis, like Perthes disease, BS has a relevant role and a definite impact on the clinical management, providing early detection and prognostic information

BONE VIABILITY

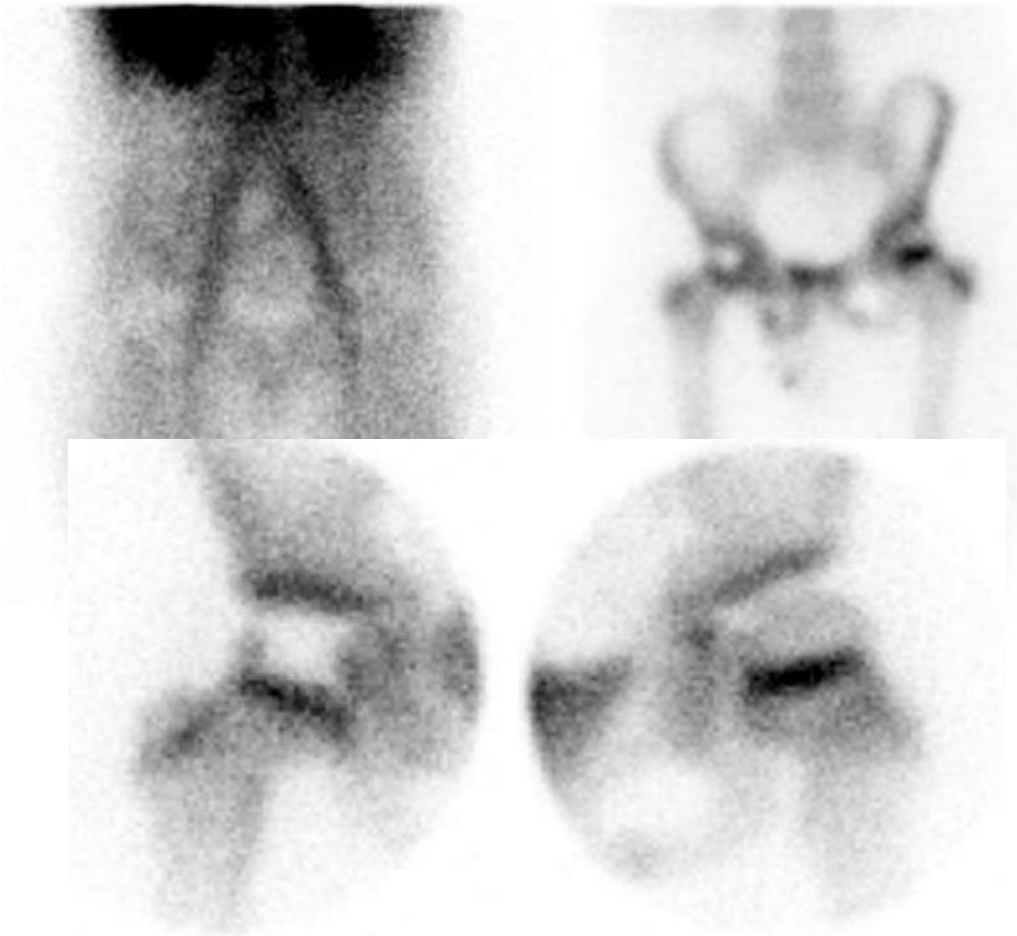

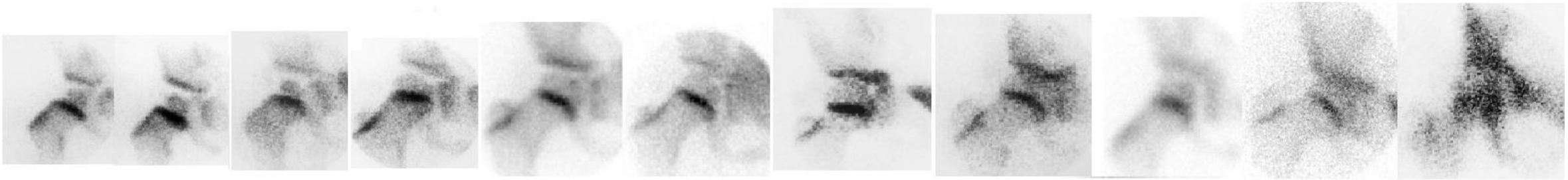

Conway JJ. A scintigraphic classification of legg-calvé-perthes disease. Semin Nucl Med 1993, Oct;23(4):274-95.

Lack of femoral head activity:

- Perthes disease
- Osteonechrosis

BONE VIABILITY

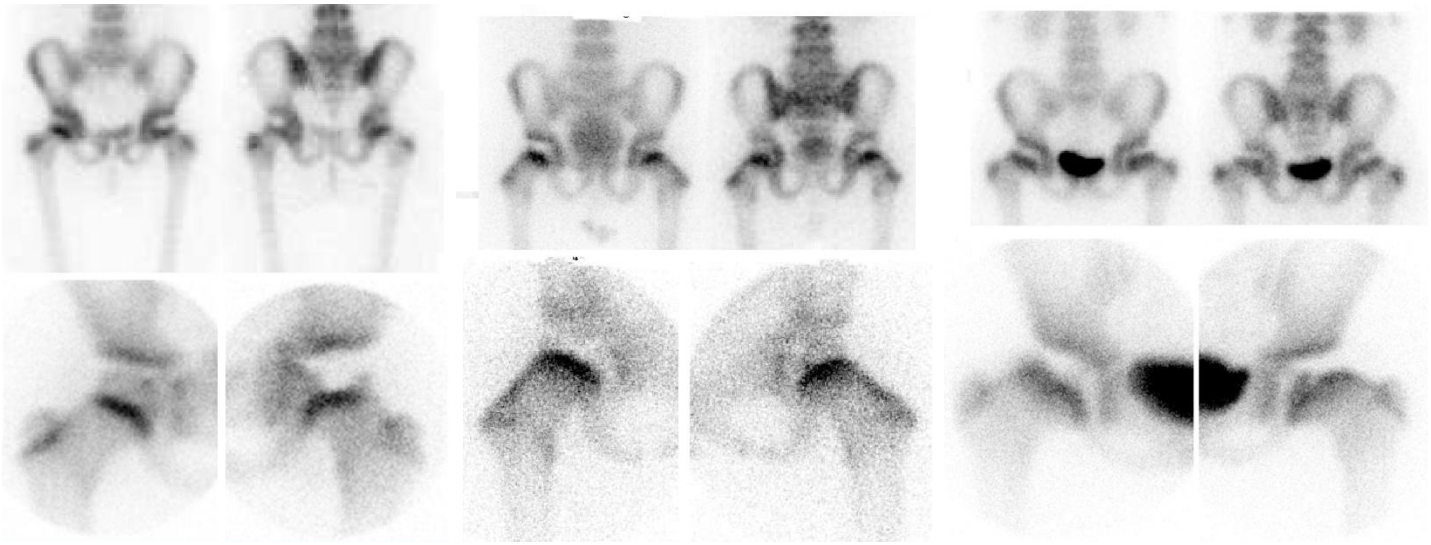

LEGG-CALVE-PERTHES DISEASE

- Pin-hole: best image to value the head perfusion
- The extent of the necrosis is a prognostic factor
- Complete epiphysis involvement or involvement of the lateral pillar are worrisome signs

Bone scan:

- Initial diagnosis
- Head perfusion follow-up

Revascularization of the necrotic femoral head after traumatic open anterior hip dislocation

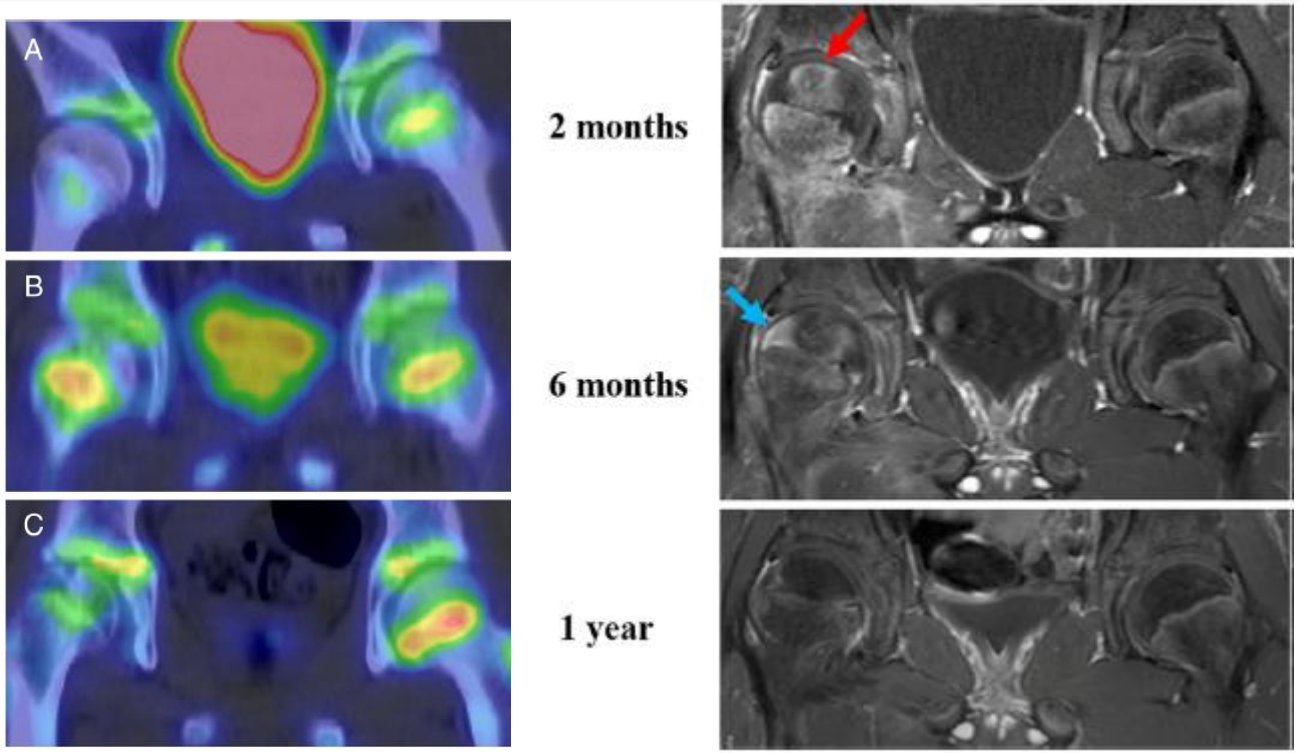

SPECT-CT provides physiological information about the growth activity

MR offers high anatomical evaluation

Momii K et al. Revascularization of the necrotic femoral head after traumatic open anterior hip dislocation in a child: a case report. Journal of Medical Case Reports 2019;13:254

Meningococcal septicaemia
-cause of septic bone infarct

BONE PET
- existence of necrotic areas within the bone
- change the therapeutic management

BONE VIABILITY

Treharne LJ, Banwell P, Cadier M. Mandatory bone scans for the assessment of extremity loss in meningococcal septicaemia? Br J Plast Surg 2003, Jan;56(1):55-7.

Rosovsky M, Goldfarb CR, Finestone H, Ongseng F. "Cold spots" in pediatric bone imaging. Semin Nucl Med 1994, Apr;24(2):184-6.

Meningococcal septicaemia
-cause of septic bone infarct

BONE PET
- existence of necrotic areas within the bone
- change the therapeutic management

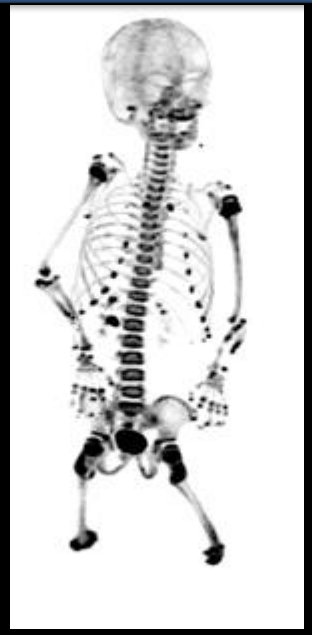

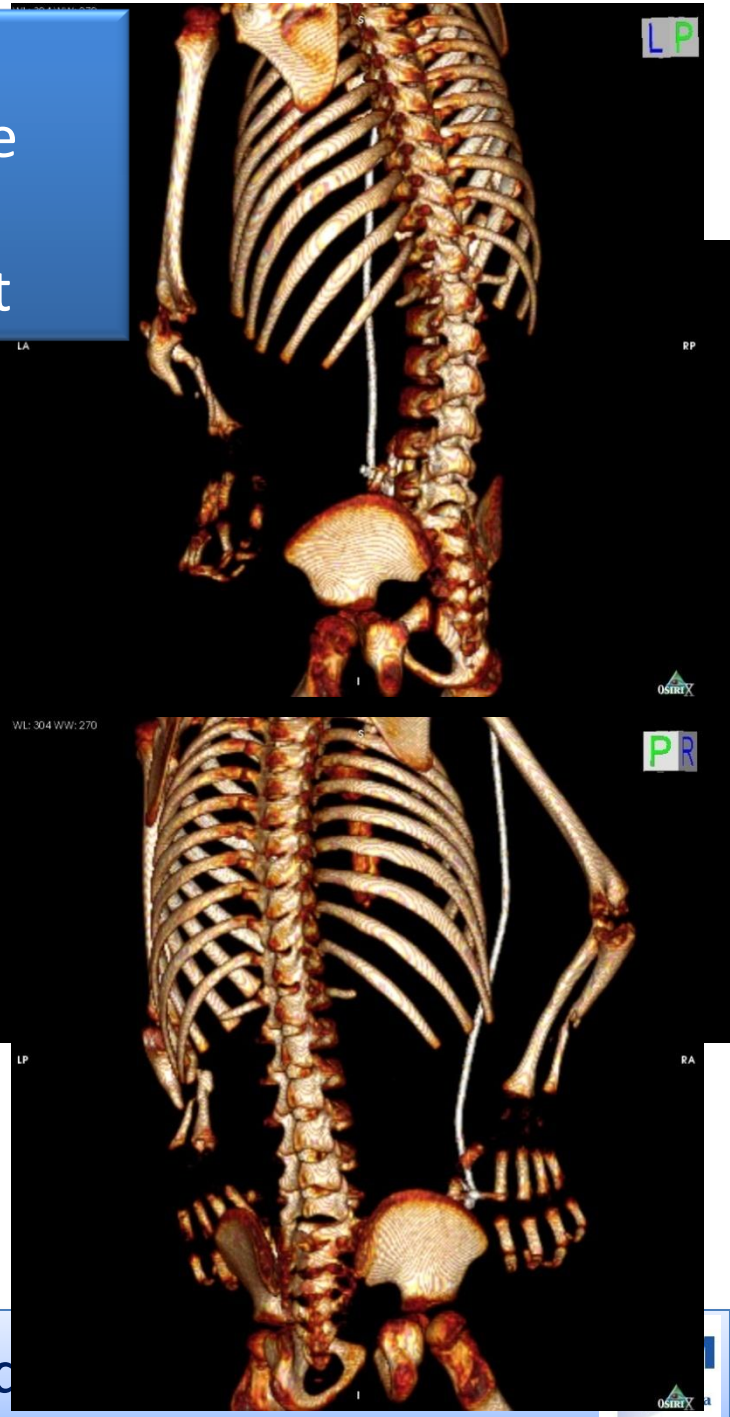

Min 1-2
Blood Pool phase

Min 45
Bone uptake phase

Incorporemos el PET al estudiar la extensión d

BONE VIABILITY

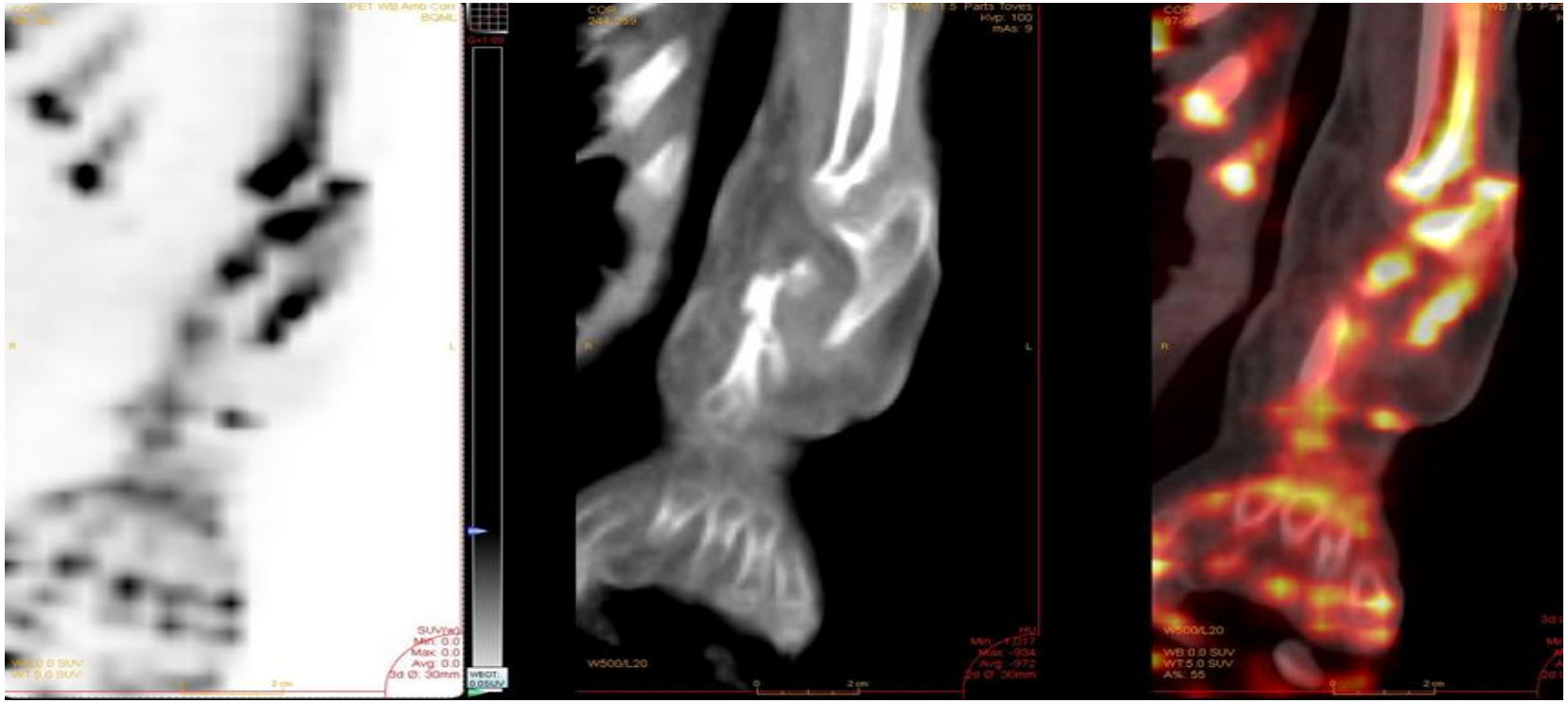

PSEUDOARTHROSIS but VIABLE BONES !

Roca I, Barber I, Fontecha CG. Evaluation of bone viability. Pediatr Radiol 2013, 43:393-405

BONE PET

^{18}F-Fluoride

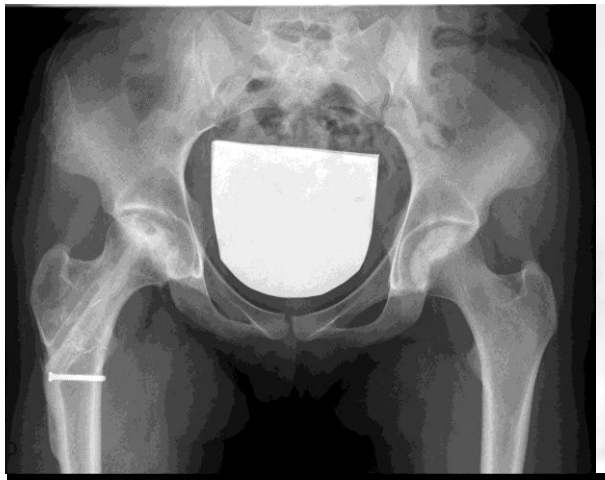

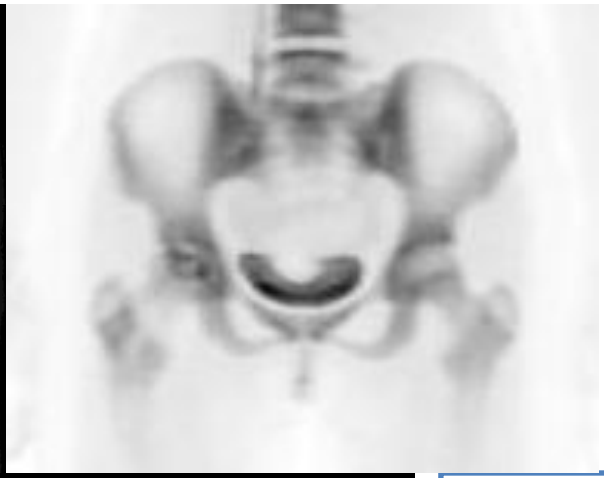

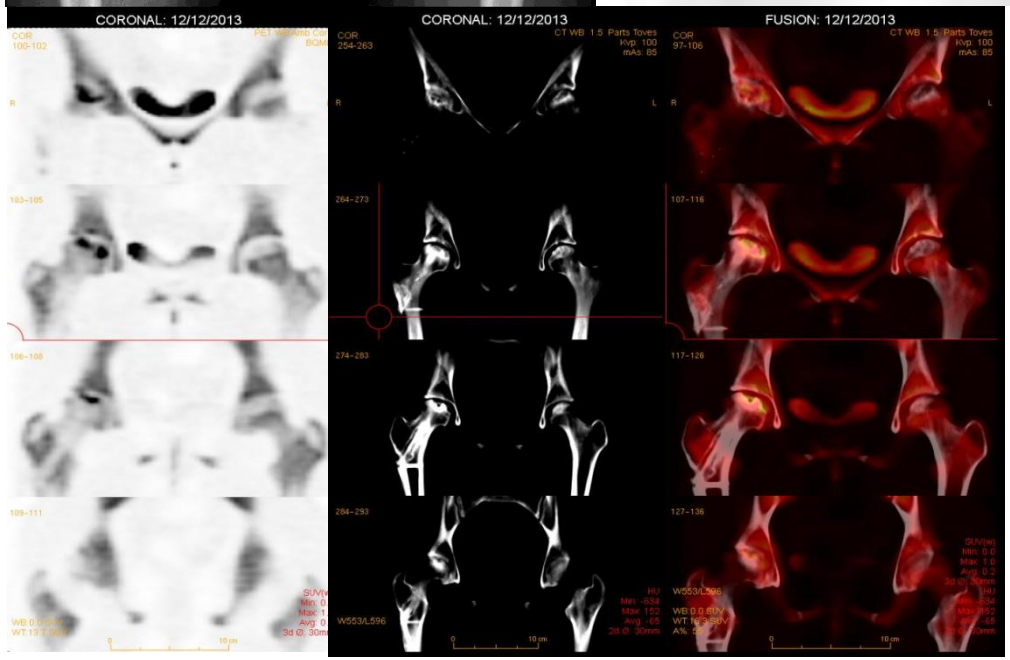

BONE VIABILITY

17 y

- 13 y: Ebstein Barr Virus
- Haemophagocitic syndrome

- Femoral head avascular nechrosis
- Vascularized fibular graft

Incorporemos el PET al estudiar la extensión de tumor/ infección

PET-CT ^{18}F

BONE SCAN
SPECT-CT

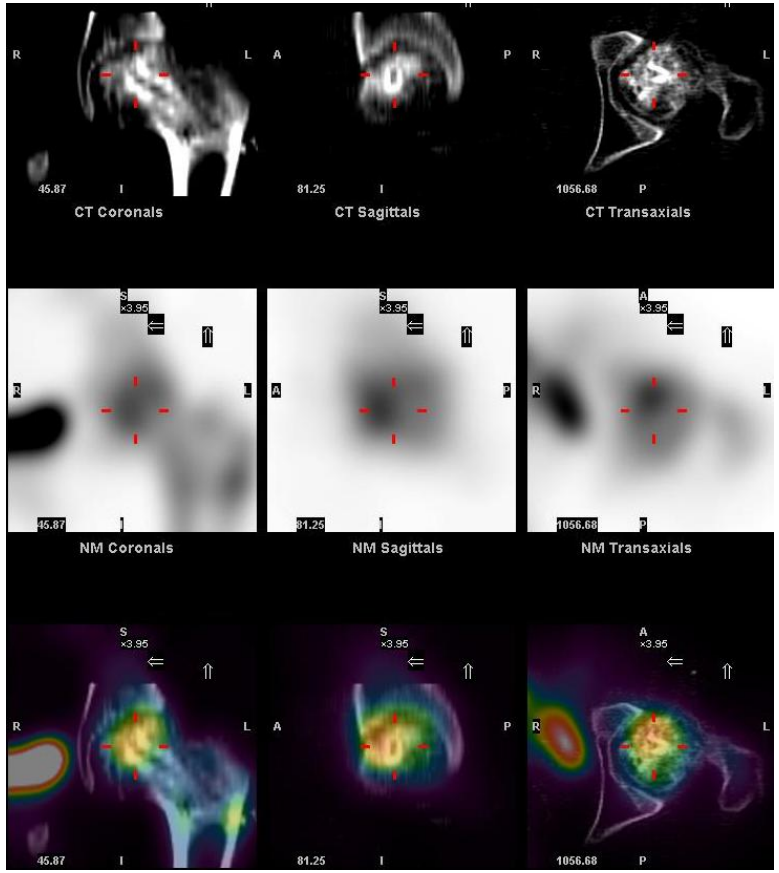

COMPARE THE QUALITY OF BOTH TECHNIQUES…

In this indication for bone viability

PLATELET-RICH PLASMA TREATMENT FOR OSTEONECROSIS

^{18}F-Fluoride PET: Increased bone revascularization

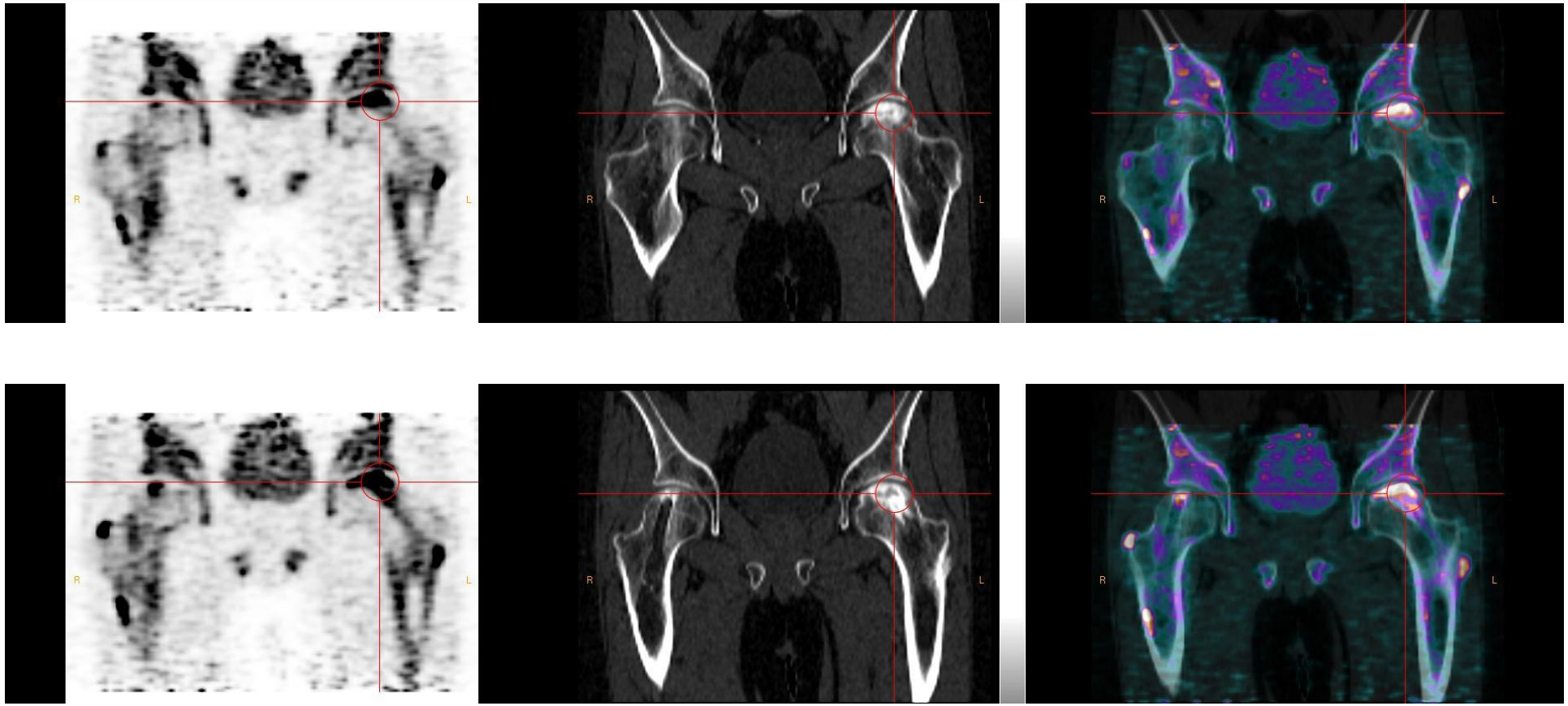

NON ACCIDENTAL TRAUMA

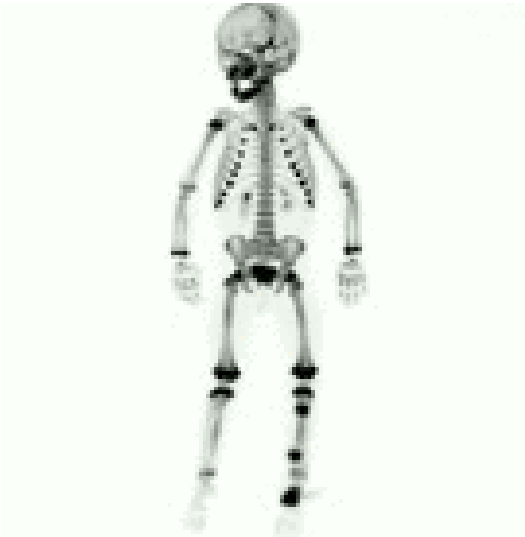

PET with ^{18}F- Fluorine

- Without CT
- Without AC

Which are the advantages and limitations of NaF PET/CT in comparasion to Tc-99m MDP?

ADVANTATGES

- The radiation is less than bone scintigraphy
- Has better image quality
- The duration of the study is less

LIMITATIONS

- Has a higher cost
- Less availability

INFECTION

Bone involvement in Sickle Cell Disease:

- Bone Scan with blood pool images
- WBC Scintigraphy

- Bone infarcts
  - Acute
  - Previous
- Acute Osteomyelitis

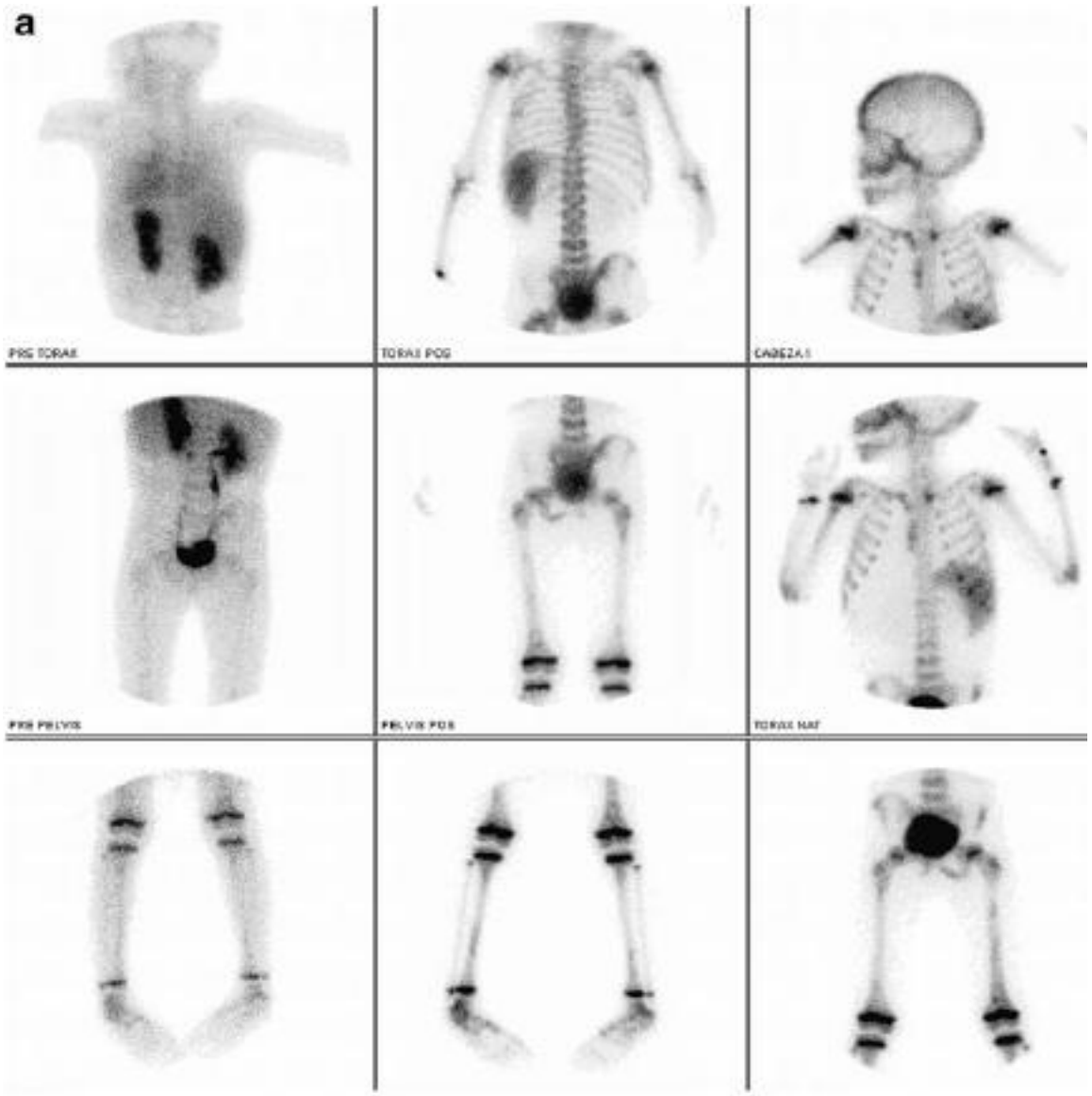

Roca I, Barber I, Fontecha CG. Evaluation of bone viability. Pediatr Radiol 2013, 43:393-405

Bone involvement in Sickle Cell Disease:

- Bone Scan with blood pool images
- WBC Scintigraphy

- Bone infarcts
  - Acute
  - Previous
- Acute Osteomyelitis

		BONE INFARCT		OSTEOMYELITIS
		ACUTE	OLD	
BONE SCAN	BLOOD POOL	+	+	+
	BONE	+	+	+
WBC SCAN		-	-	+

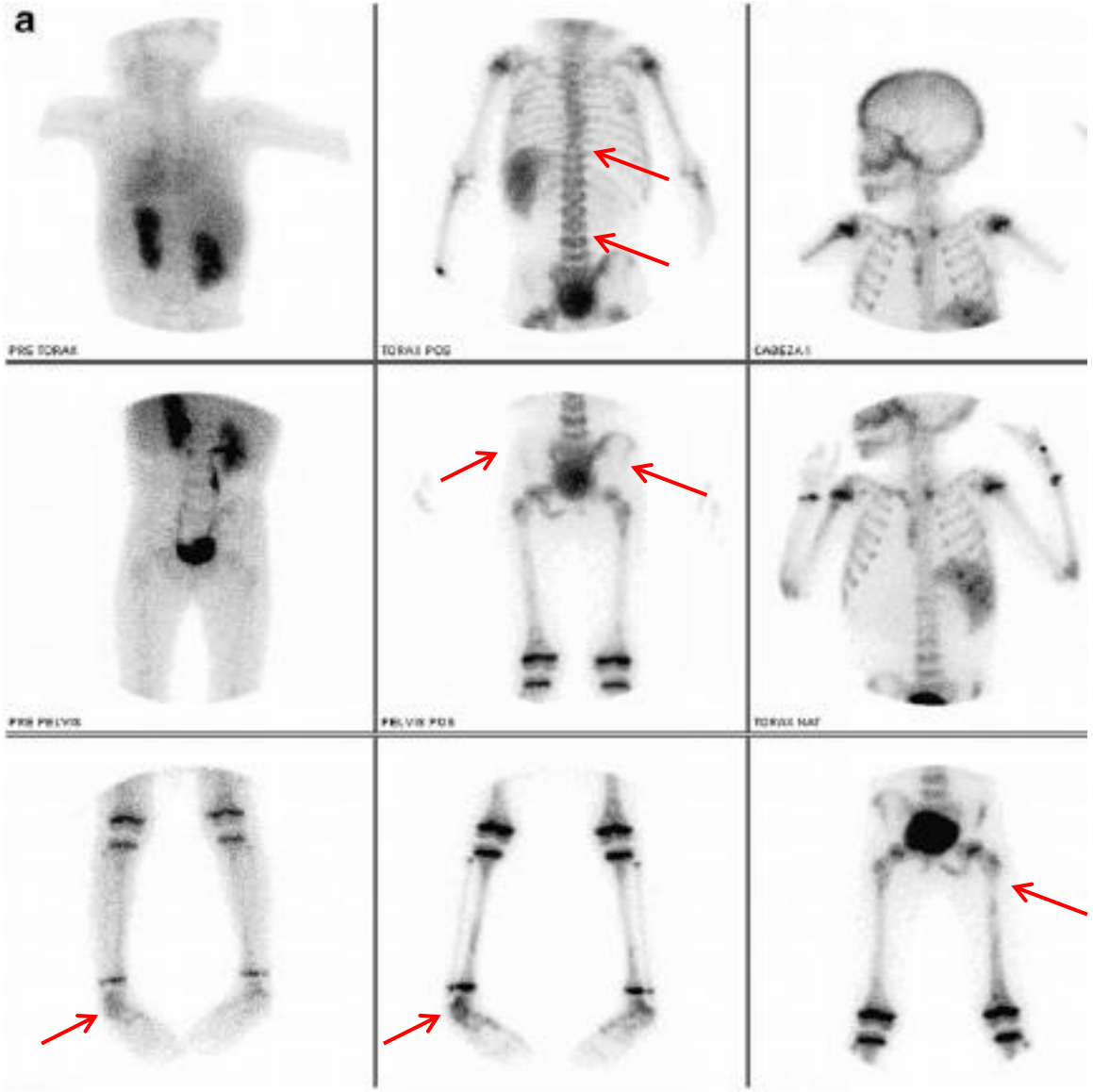

Roca I, Barber I, Fontecha CG. Evaluation of bone viability. Pediatr Radiol 2013, 43:393-405

Bone involvement in Sickle Cell Disease:

- Bone Scan with blood pool images
- WBC Scintigraphy

- Bone infarcts
  - Acute
  - Previous
- Acute Osteomyelitis

		BONE INFARCT		OSTEOMYELITIS
		ACUTE	OLD	
BONE SCAN	BLOOD POOL	+	+	+
	BONE	+	+	+
WBC SCAN		-	-	+

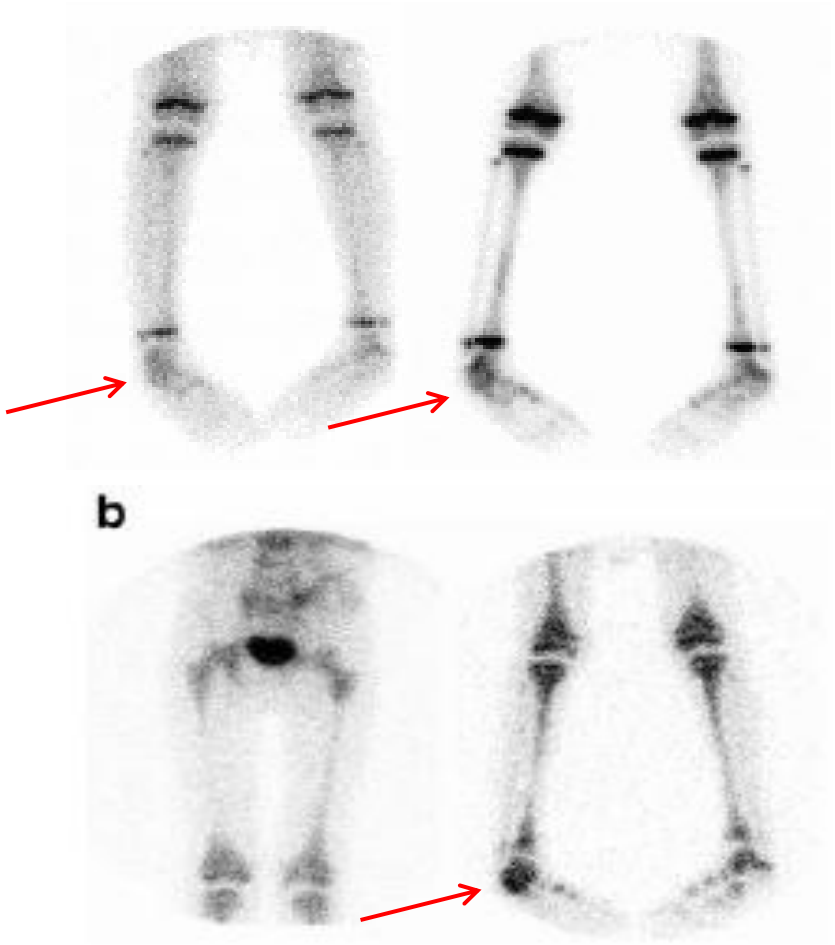

Blood Pool

Bone Scan

WBC Scan

Roca I, Barber I, Fontecha CG. Evaluation of bone viability. Pediatr Radiol 2013, 43:393-405

Follow-up: new infarts in vertebrae and recovery of the pelvic infarcts

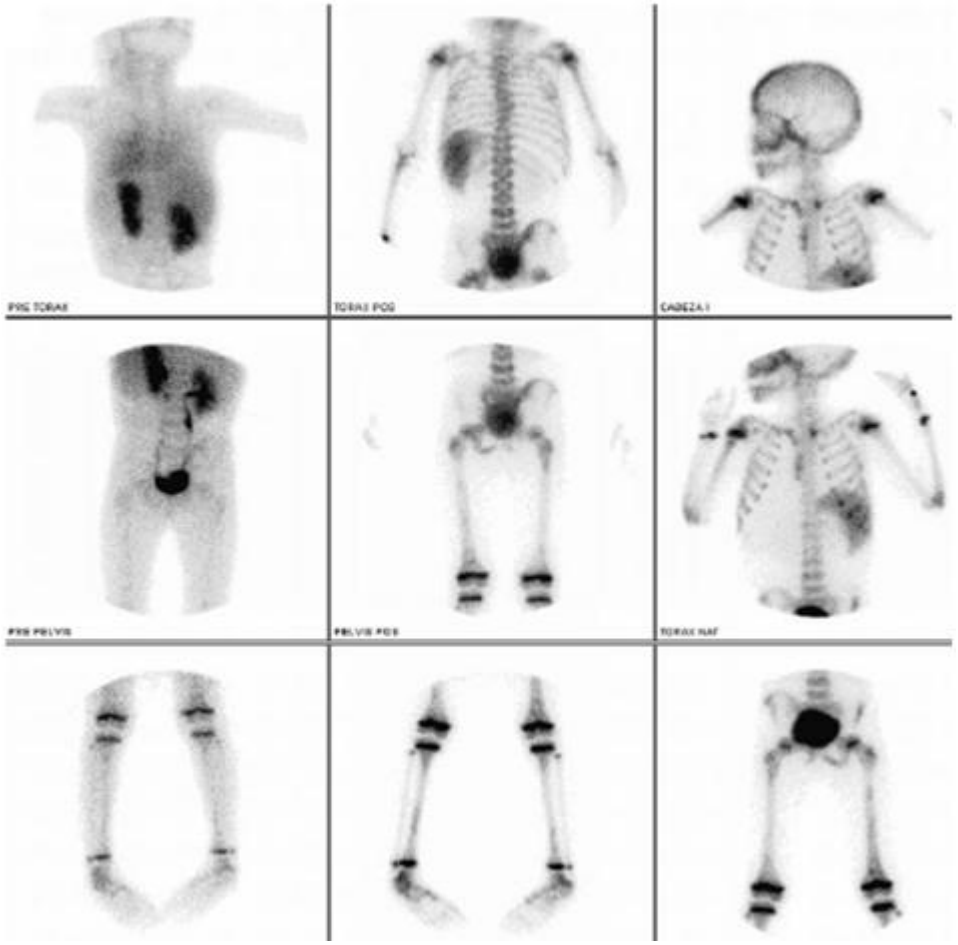

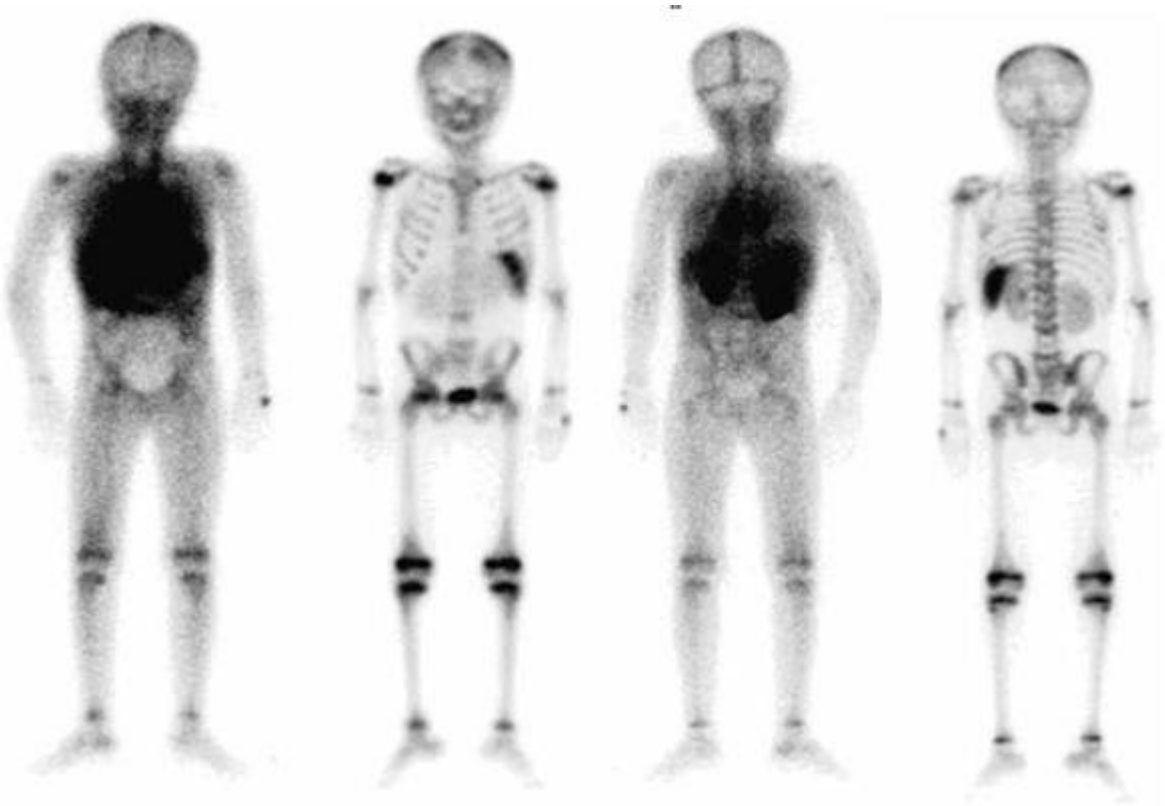

Roca I, Barber I, Fontecha CG. Evaluation of bone viability. Pediatr Radiol 2013, 43:393-405

^{18}F-FDG PET

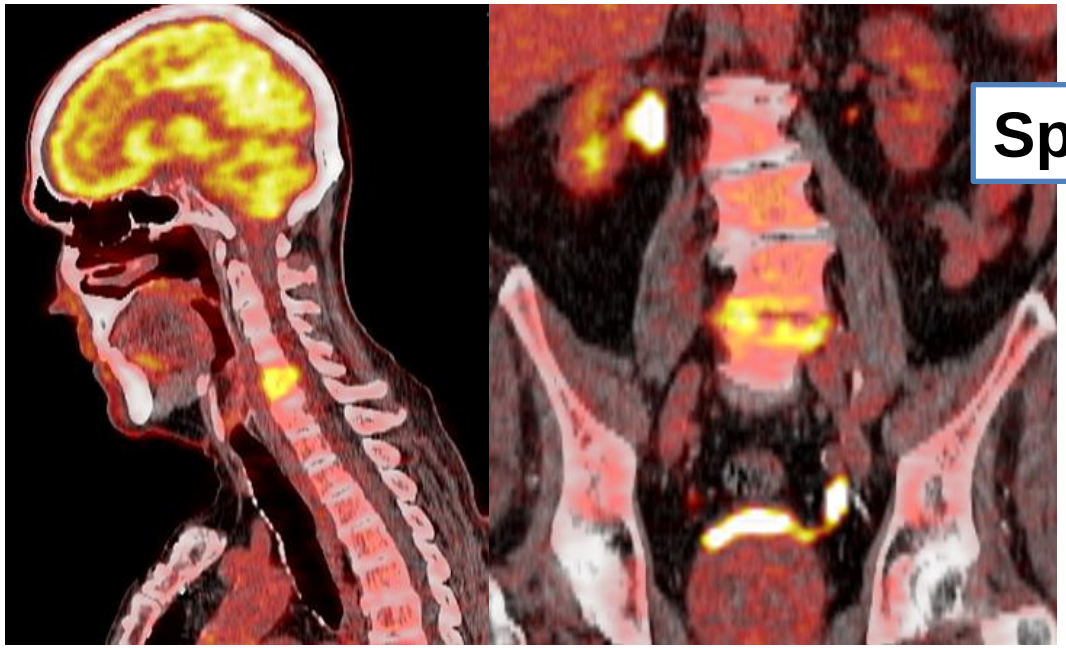

Spondylodiscitis

- uptake in inflammatory cellular infiltrates
- increased glycolytic activity in acute or chronic inflammation
- low physiological bone marrow uptake:
  - FDG interesting tracer for imaging the spine.

- Several investigations suggest that FDG-PET accurately diagnoses SPINAL INFECTION

Radionuclide imaging of spinal infections
Eur J Nucl Med Mol Imaging (2006) 33:1226–1237

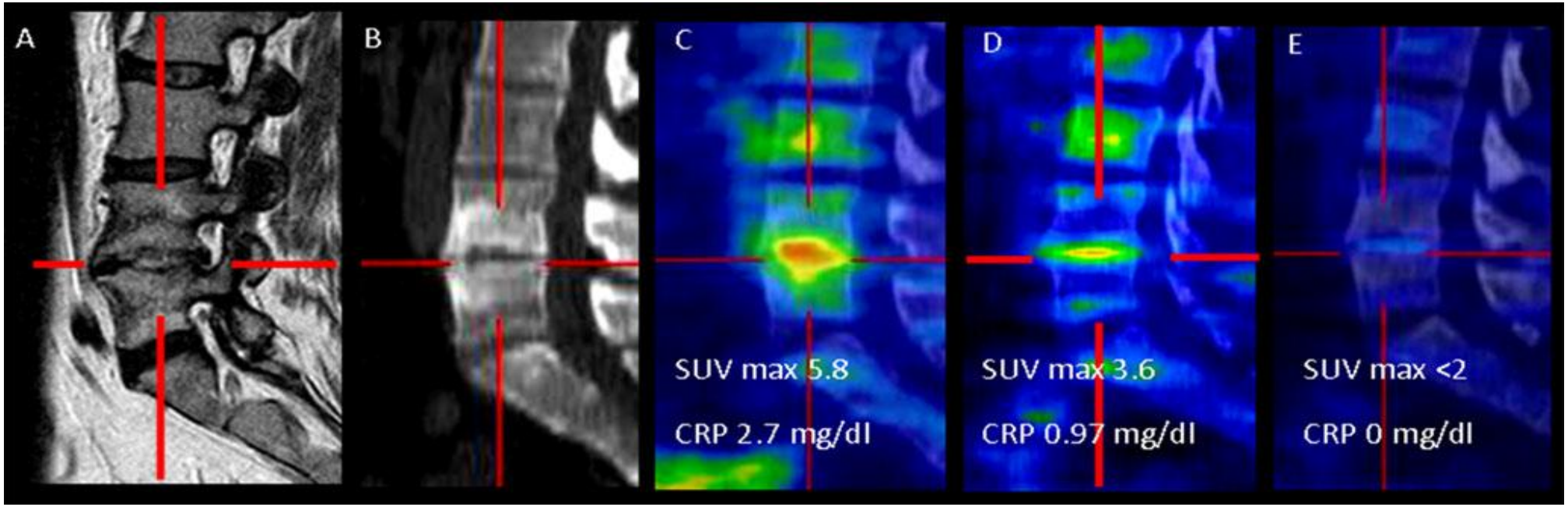

Responder patient

Acute haematogenous pyogenic L4–L5 spondylodiscitis.
MR and CT: pathological signal in L4–L5
FDG PET/CT at diagnosis: increased uptake in L4–L5
FDG PET/CT after 3 weeks of therapy: significant reduction in the infected site
FDG PET/CT image after therapy: negative

FDG PET/CT is useful for the interim evaluation of response to therapy in patients affected by haematogenous Spondylodiscitis
Eur J Nucl Med Mol Imaging (2012) 39:1538–1544

Discitis

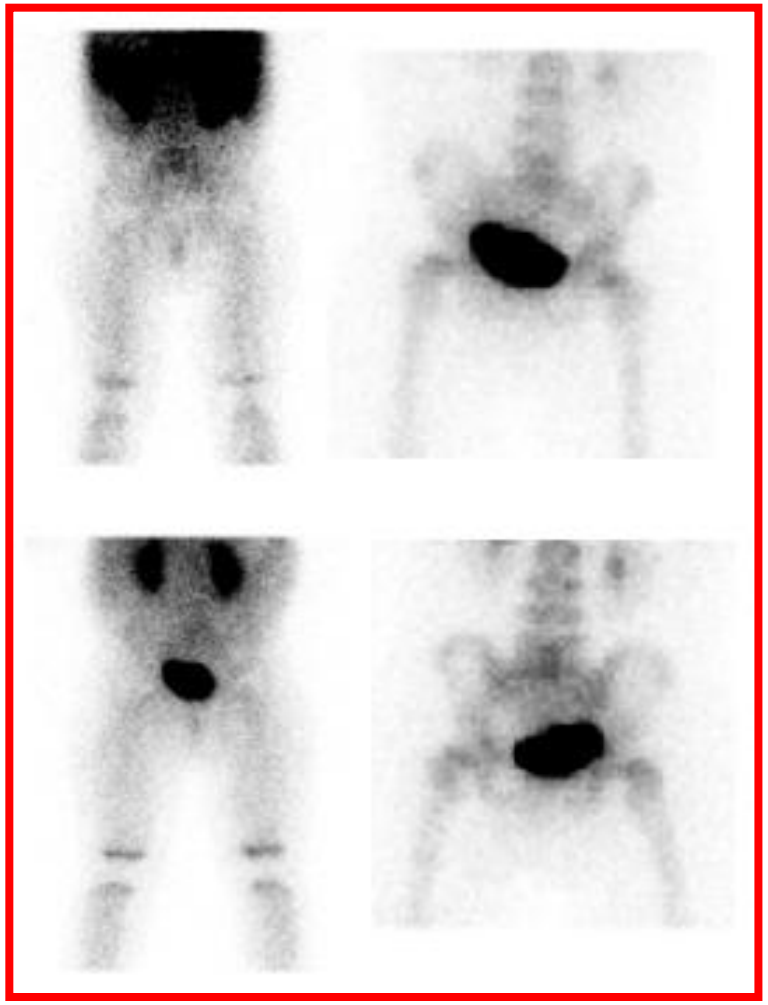

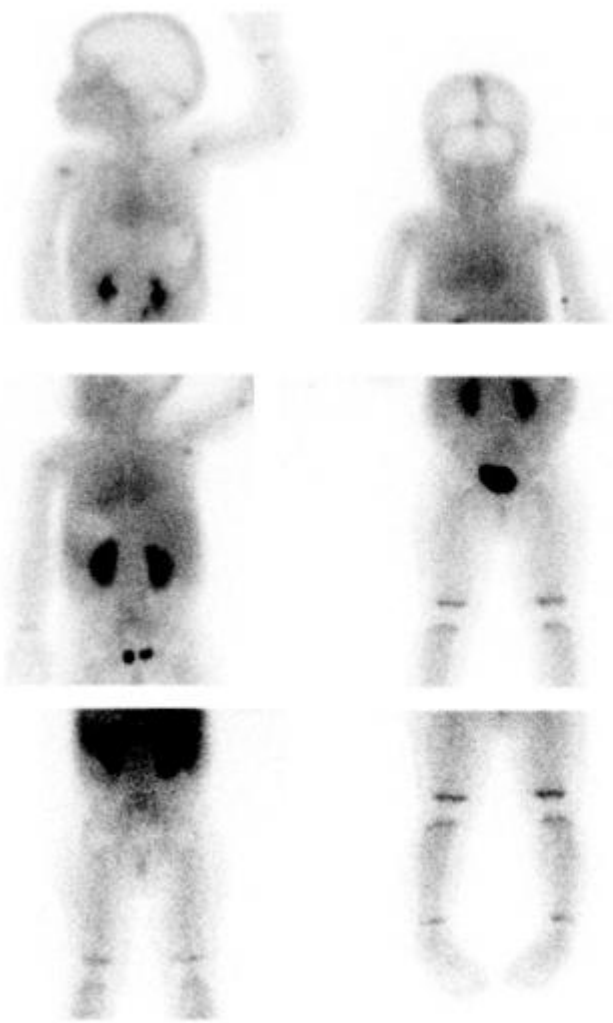

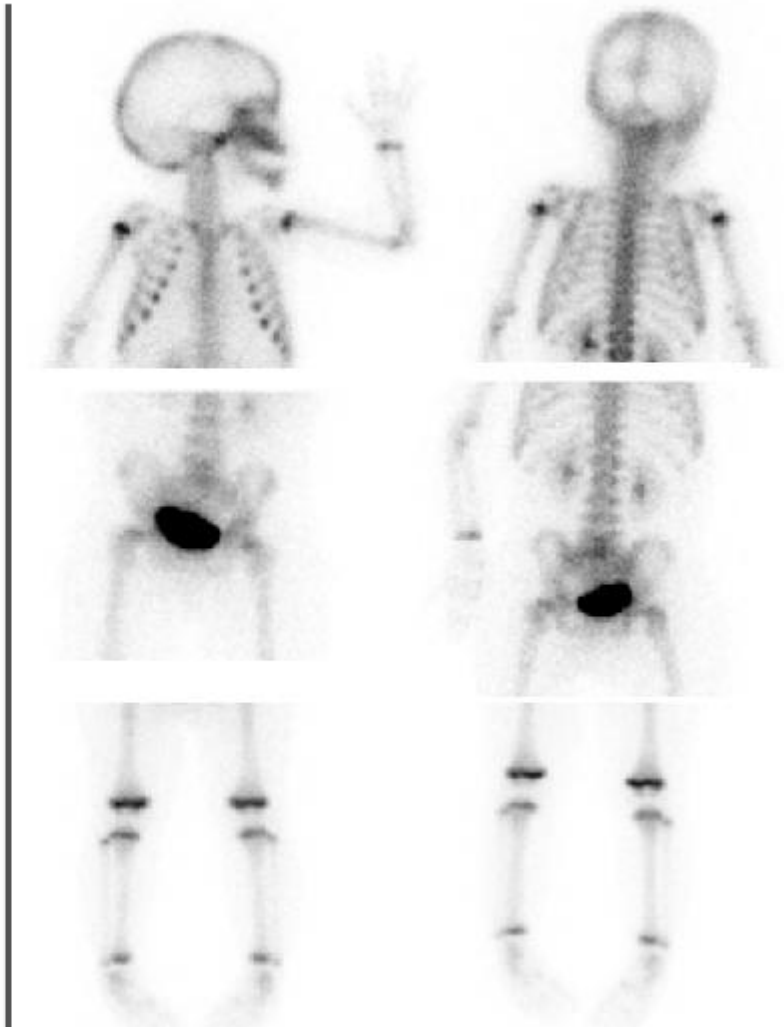

Sacroileitis

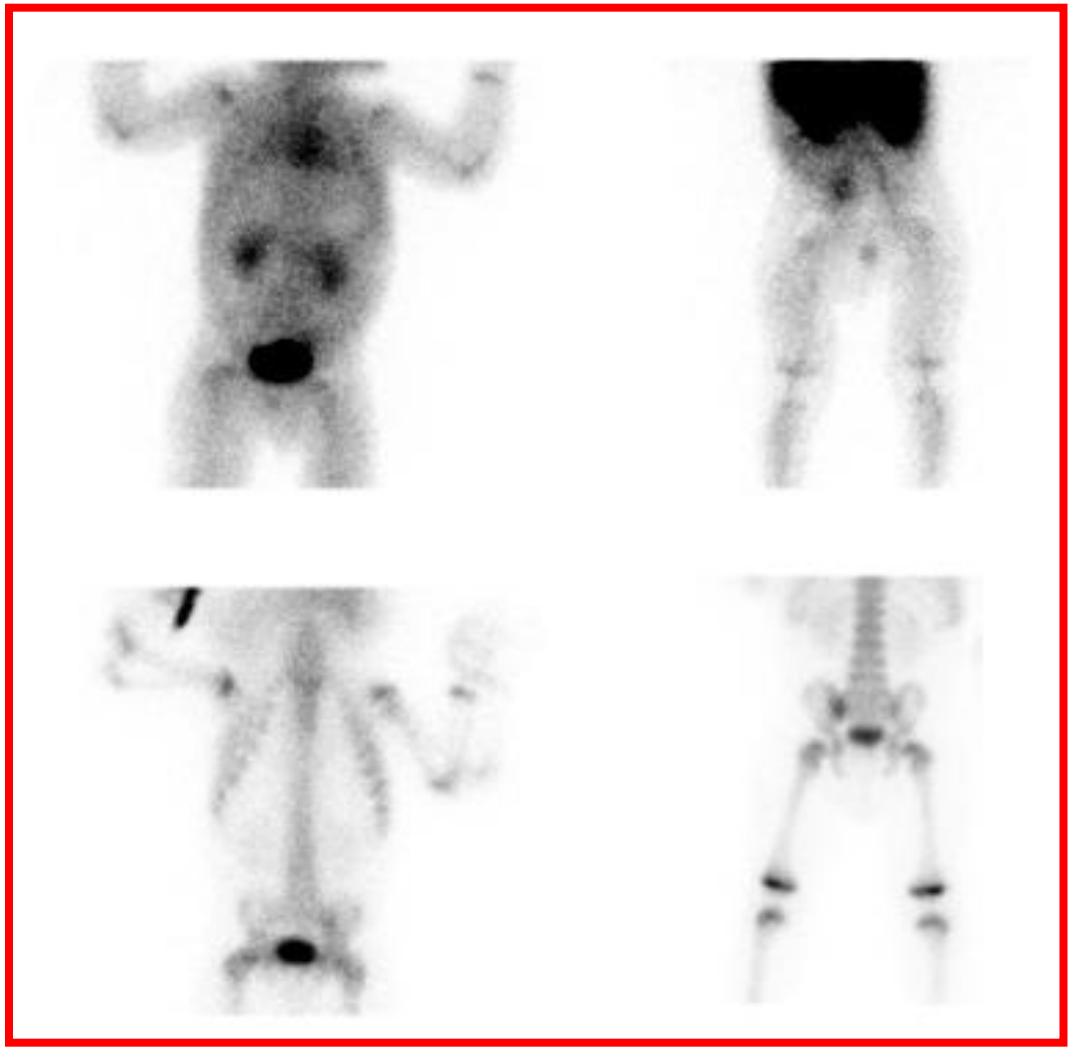

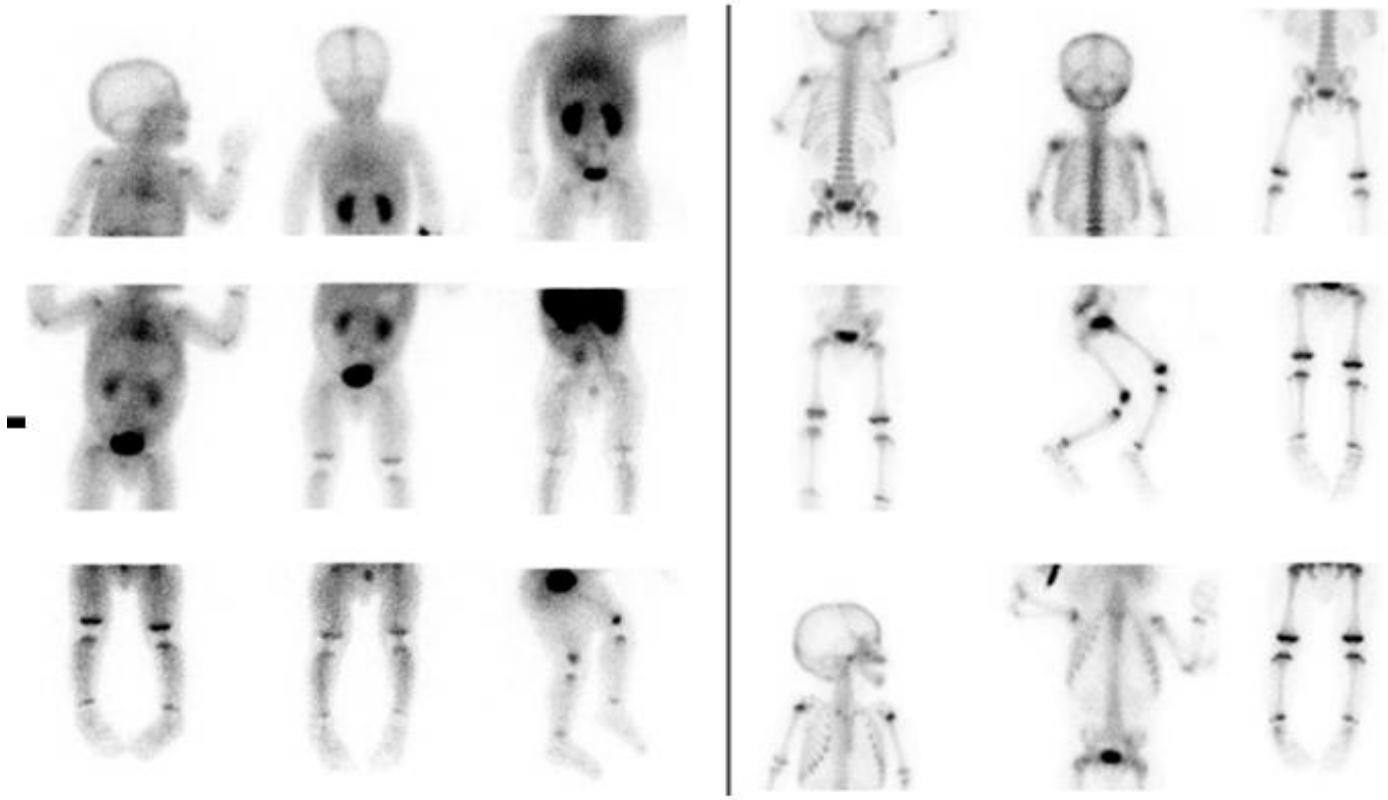

Bone PET in septic shock

4 years old boy

September 2015:
Septic arthritis in right knee with secondary septic shock
Severe rabdomyolisis
Acute renal insufficiency
Tibial osteomyelitis with foci of osteonechrosis
Multiple cutaneous scars

MRI
generalized myositis

Bone PET in septic shock

Blood pool images:
- 1-min/bed
- Whole body
- Immediately after ^{18}F injection

Blood pool images
- increased BP
  - Muscles
  - Right knee
  - Skin ulcers

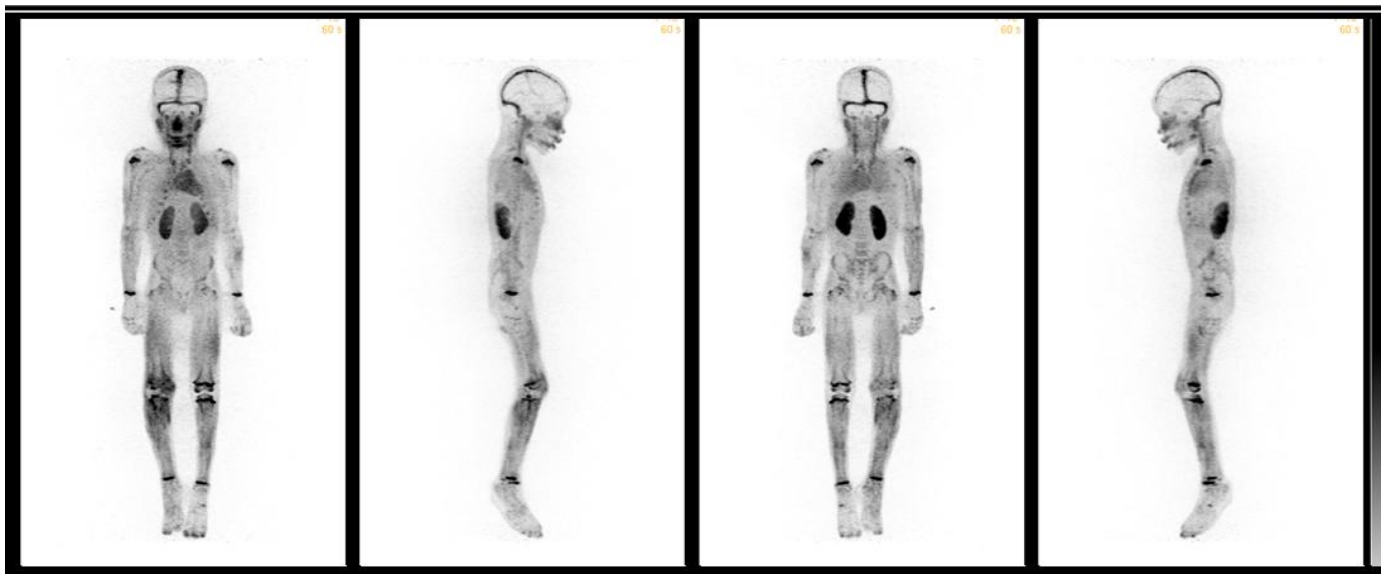

Bone PET in septic shock

Blood pool images:
- 1-min/bed
- Whole body
- Immediately after ^{18}F injection

Blood pool images
- increased BP
  - Muscles
  - Right knee
  - Skin ulcers

Bone images:
- 3-min/bed
- Whole body
- 45 min after ^{18}F injection

Bone images
- increased fluorine bone uptake
  - several muscles of arms and legs
  - right knee: increased uptake in right tibial metaphysis, with a central cold area

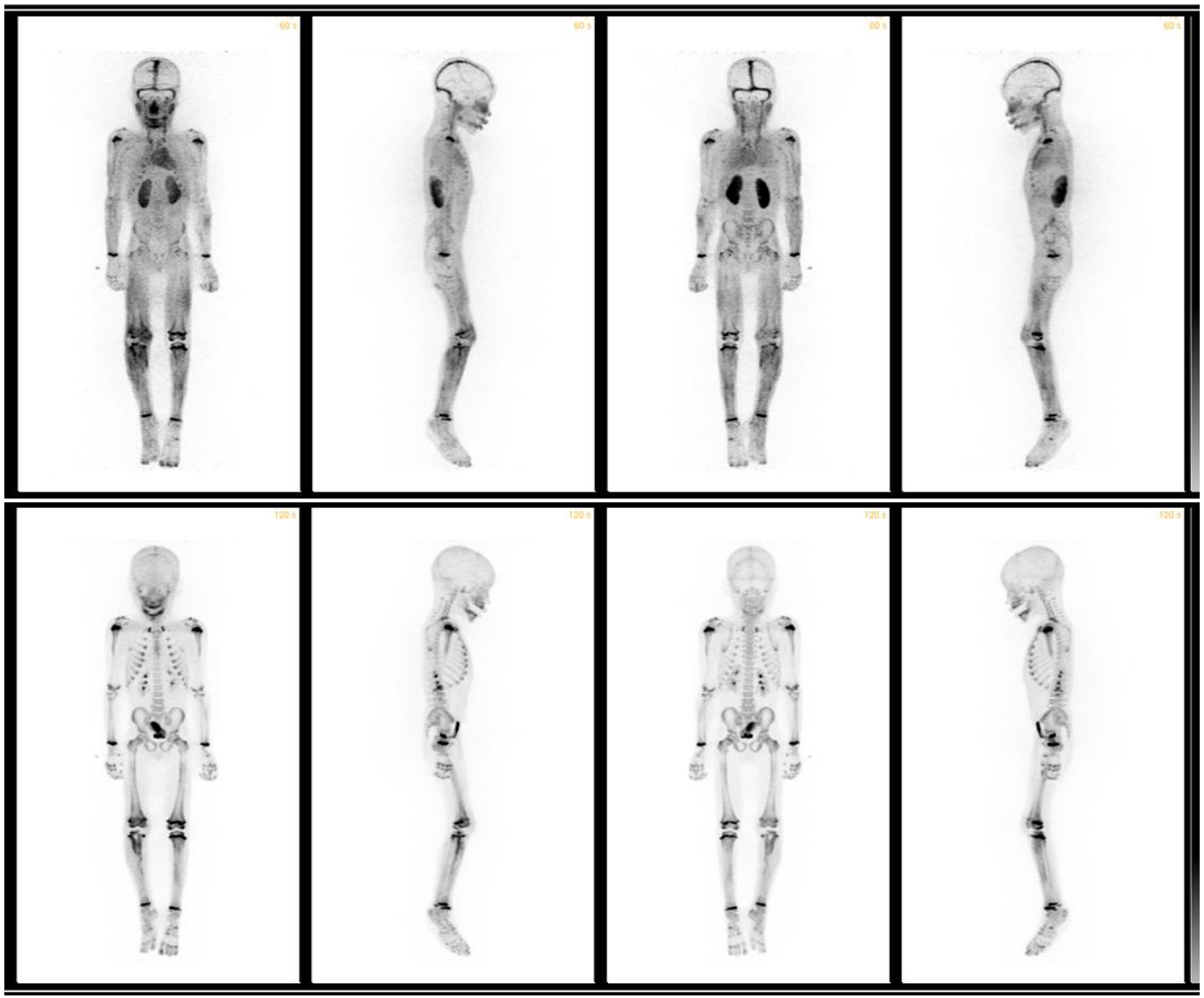

Bone PET in septic shock

Localized knee PET-CT images:
Increased bone uptake in tibial metaphysis and proximal diaphysis, with a cold bone area located between the metaphysis and physis (osteonechrosis or Brodie abscess?)

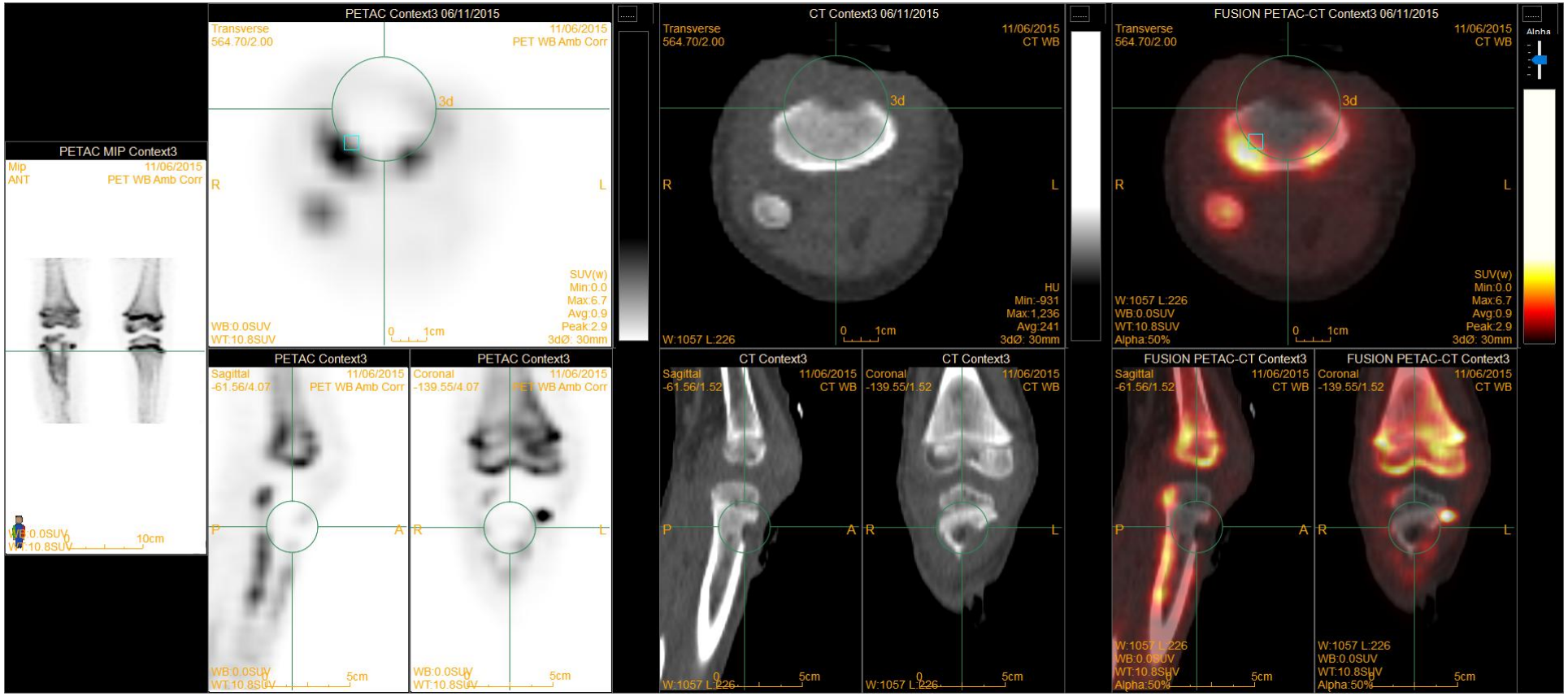

Low dose CT only in the region of interest to avoid unnecessary irradiation

Incorporemos el PET al estudiar la extensión de tumor/ infección

OSTEOMYELITIS

- increased blood pool
- increased bone uptake
- submetaphyseal

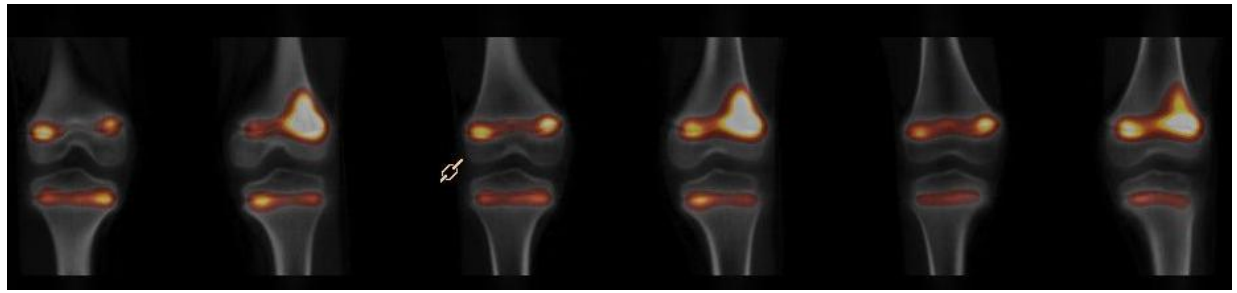

7 Y, LEFT FEMUR OSTEOMYELITIS

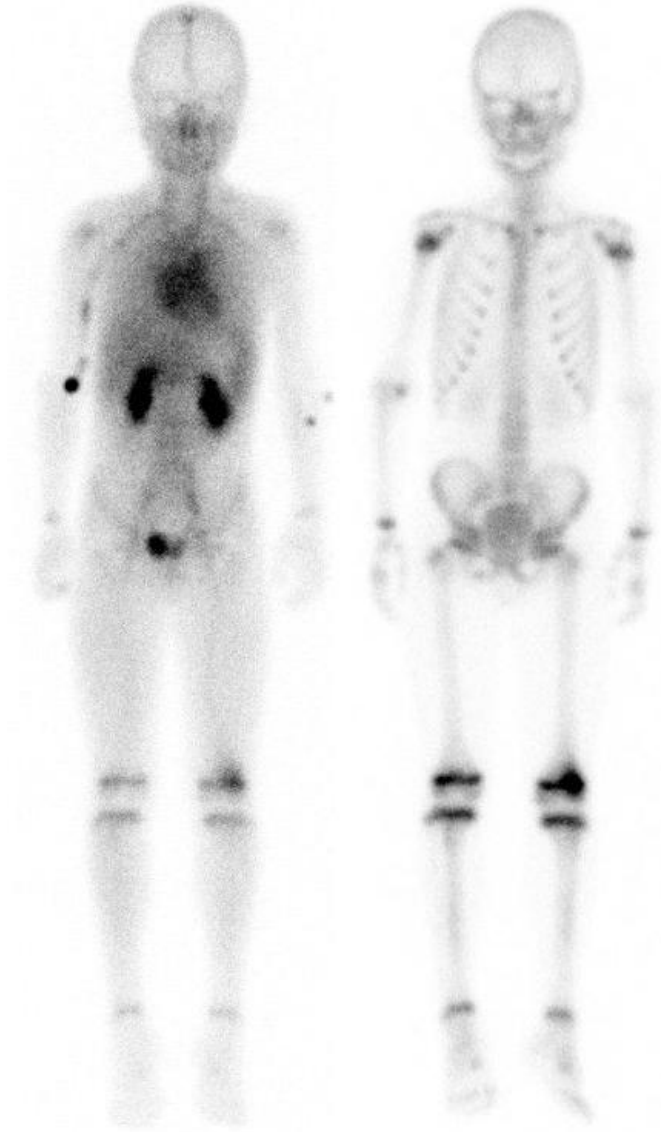

ARTHRITIS

HIP ARTHRITIS, uncomplicated,

- increased blood pool
- Bone uptake nearly normal

- Pin-hole images are crucial to value the femoral head perfusion

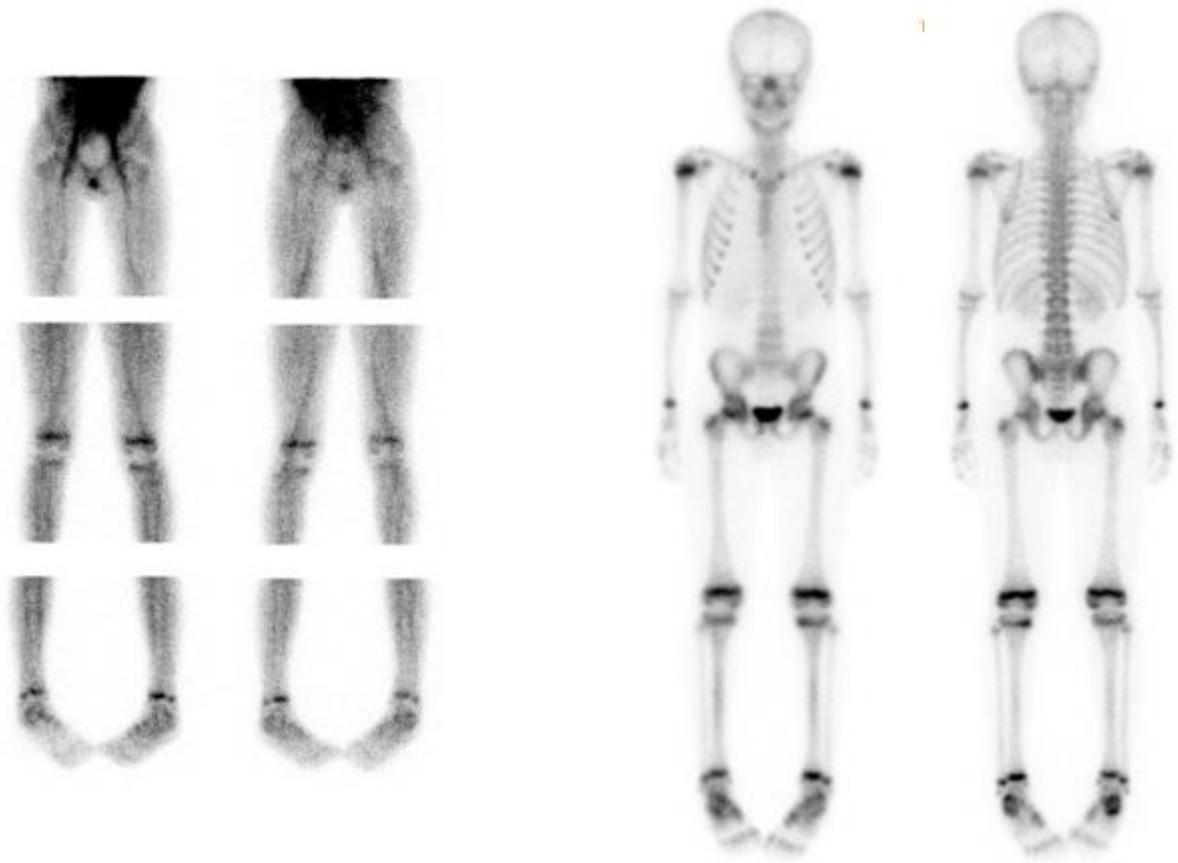

7 Y, LEFT HIP ARTHRITIS

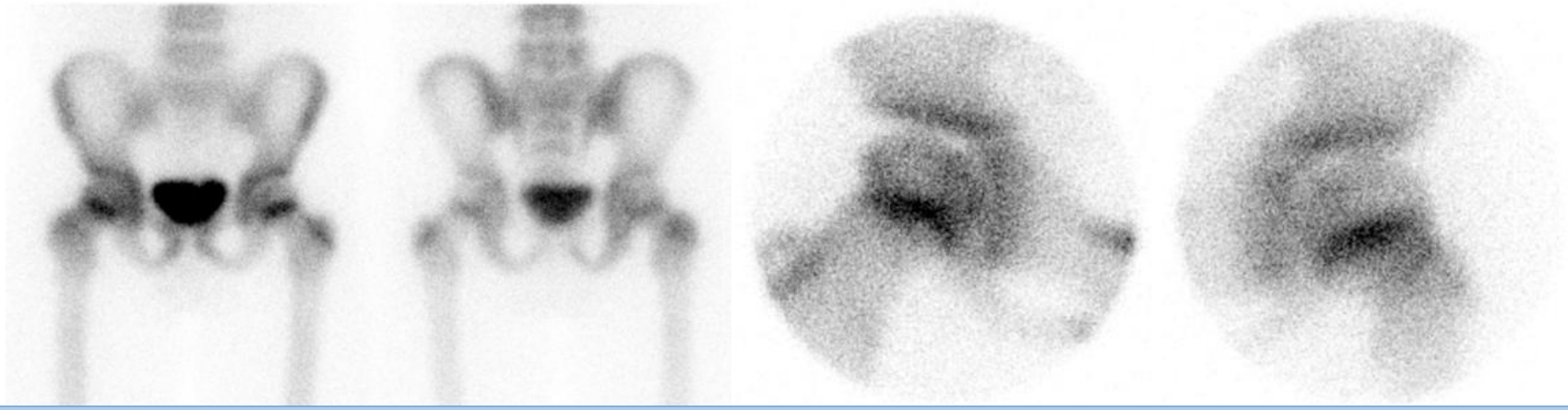

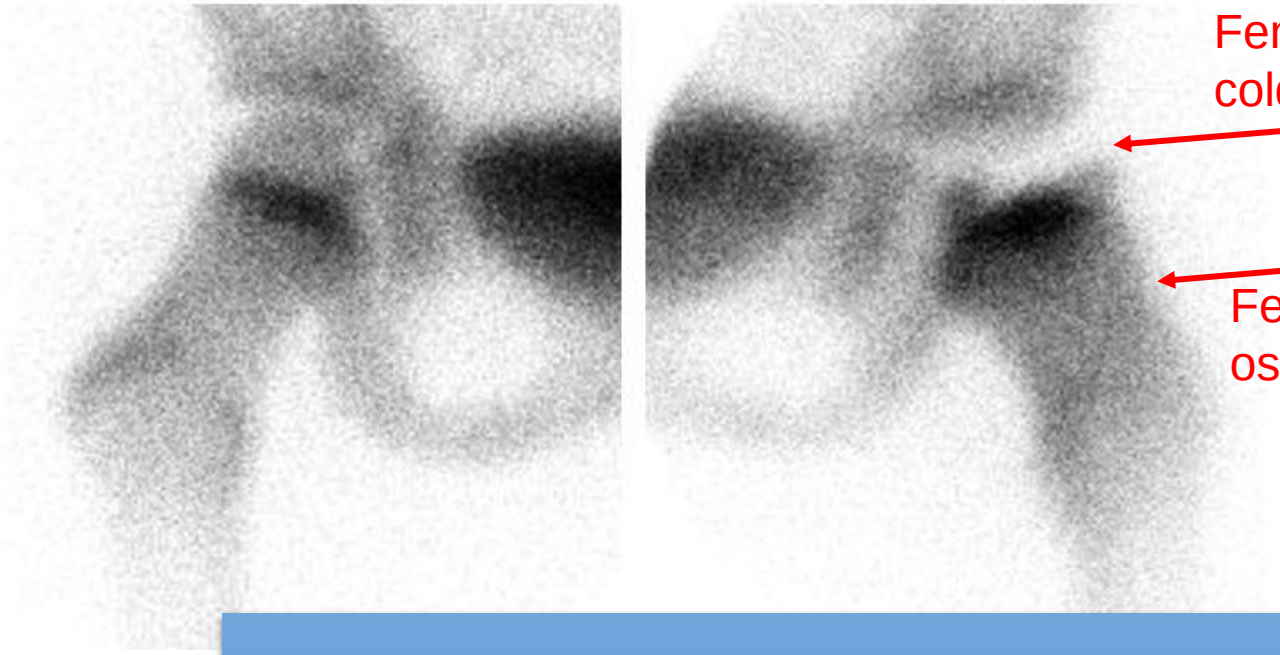

Osteomyelitis and Arthritis

in babies and children

- Value the epiphyseal perfusion
- Value submetaphyseal areas

BONE AND JOINT INFECTION

- focal decreased bone uptake can be detected.
- hip arthritis with “cold” hipoperfused femoral head
  = interruption of the blood supply to the epiphysis

Due to :

-an increased intraarticular pressure
-bone marrow edema or
-bone necrosis

Treharne LJ, Banwell P, Cadier M. Mandatory bone scans for the assessment of extremity loss in meningococcal septicaemia? Br J Plast Surg 2003, Jan;56(1):55-7.

Rosovsky M, Goldfarb CR, Finestone H, Ongseng F. "Cold spots" in pediatric bone imaging. Semin Nucl Med 1994, Apr;24(2):184-6

Focal cold osteomyelitis can be found in some cases, especially during first hours/days and in case of medullary extens involvement

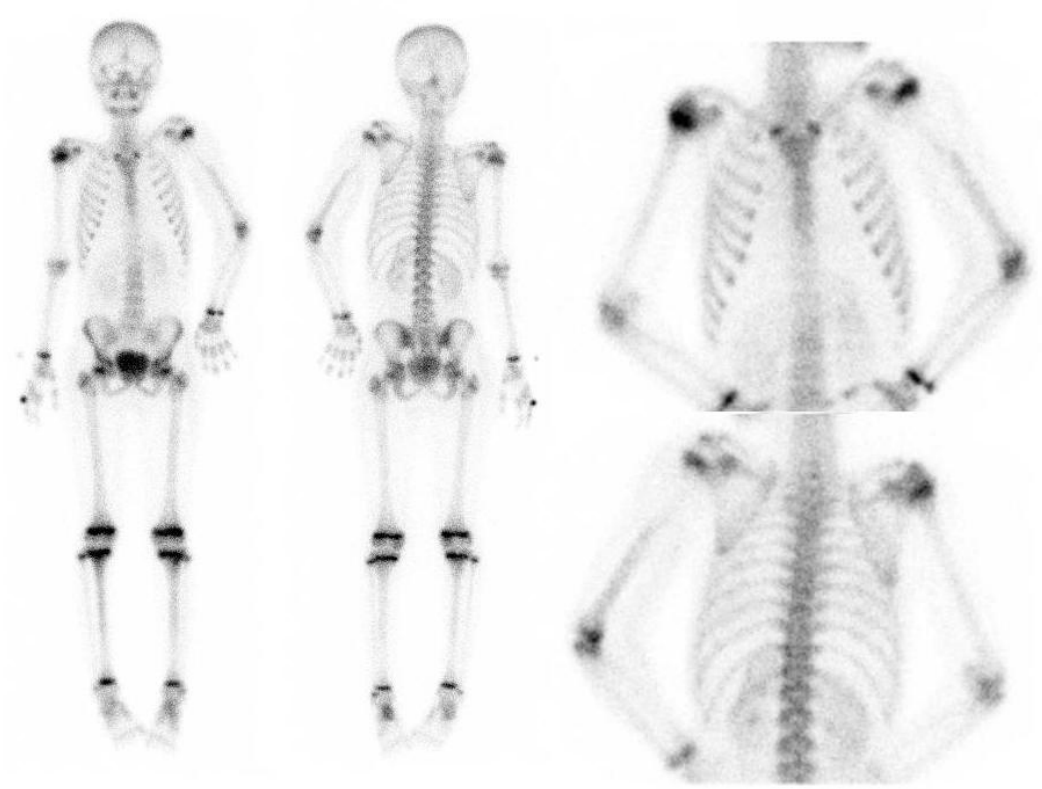

11 Y
LEFT HUMERUS OSTEOMYELITIS

Sacrum osteomyelitis with Brodie abscess

- BP image
- SPECT-CT is crucial

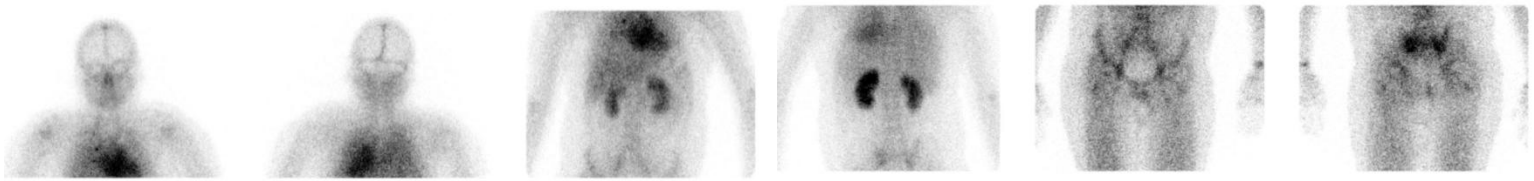

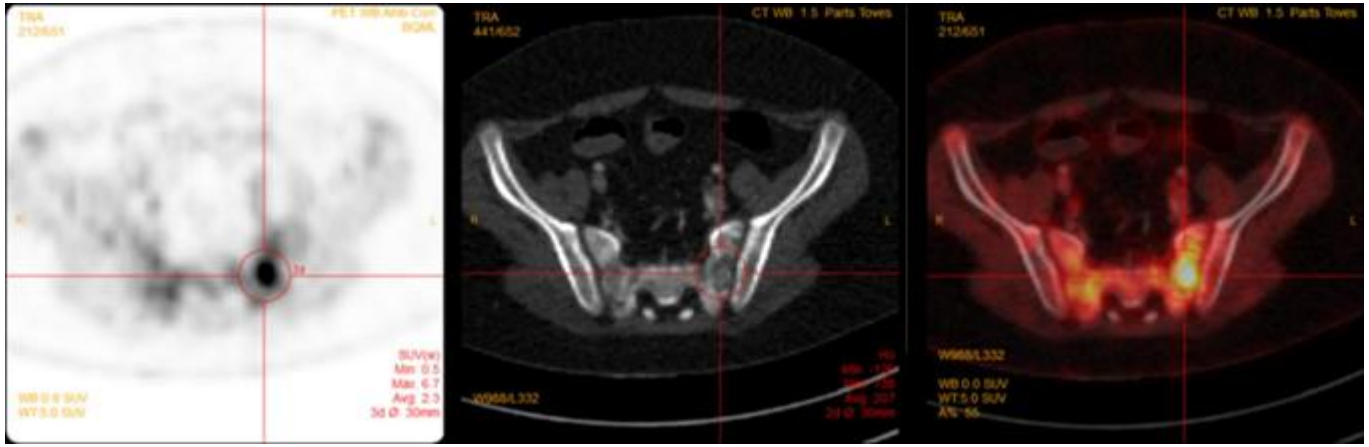

Chronic Recurrent Multifocal Osteoyelitis

- WB BP image: extent

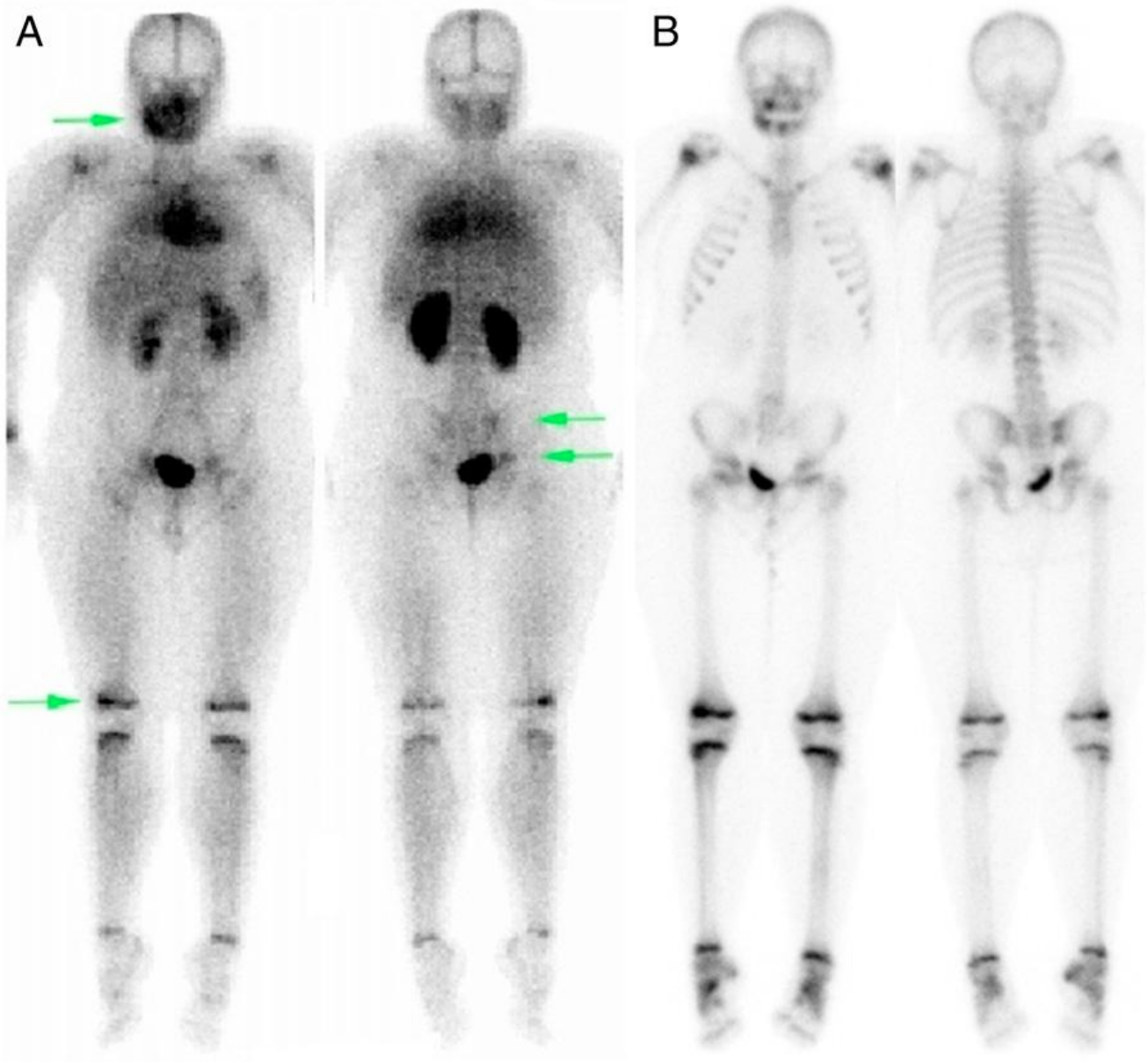

Martín-Nalda A, Roca I, Fontecha CG, Fernández-Polo A, Barber I, Martinez-Gallo M, Soler-Palacin P. Chronic Recurrent Multifocal Osteomyelitis and Thalidomide in Chronic Granulomatous Disease. Pediatrics. 2016 Aug;138(2).

INFLAMMATION

Still Disease
Juvenile idiopathic arthritis

Systemic involvement

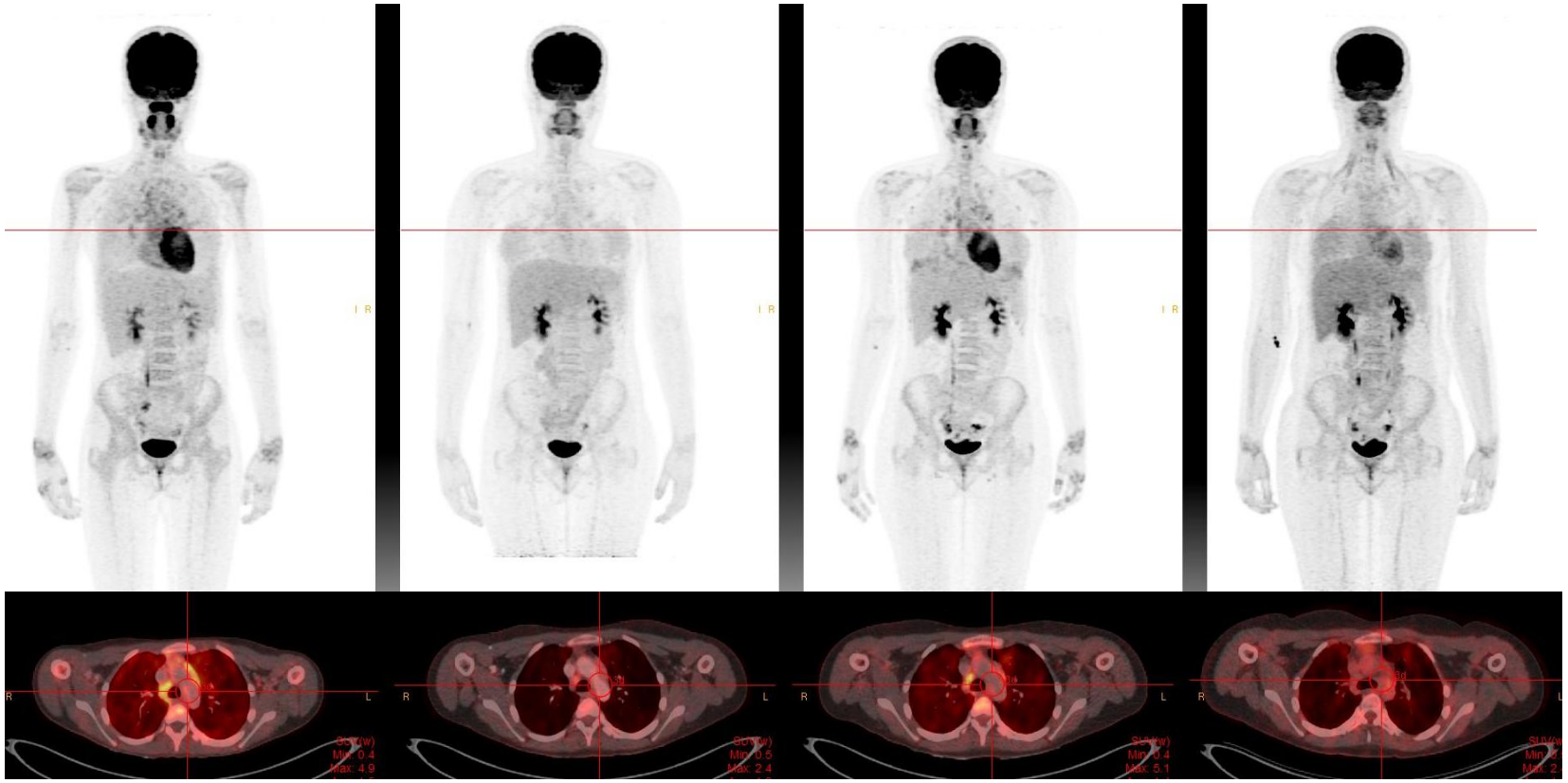

Diagnostic value of FDG-PET/(CT) in children with fever of unknown origin and unexplained fever during immune suppression

Eur J Nucl Med Mol Imaging (2014) 41:1916–1923

Incorporemos el PET al estudiar la extensión de tumor/ infección

FDG-PET in INFECTION

16 y old girl
Open fractures of both tibia
Multiple surgeries
DD bone vs soft tissue infection
XR normal

Bone scan:
- BP neg
- Bone uptake nearly normal

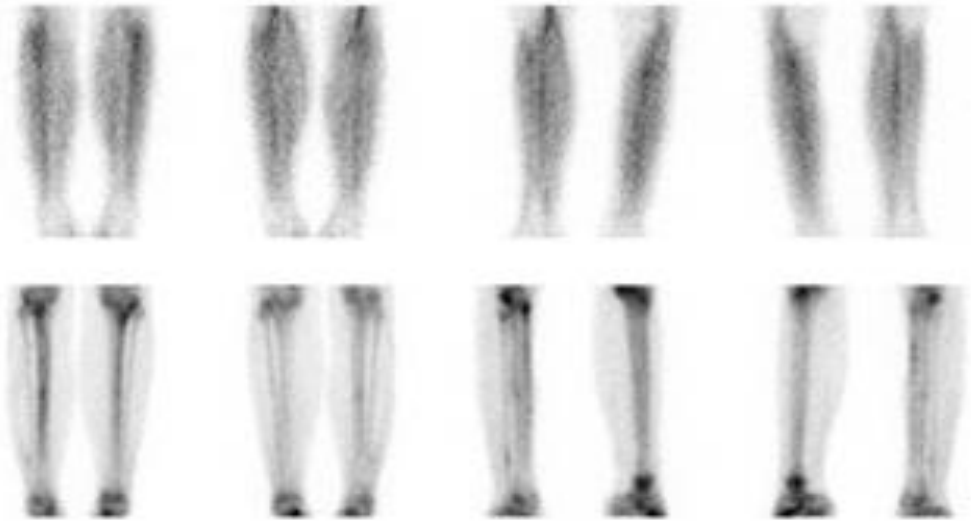

Blood pool

Bone images

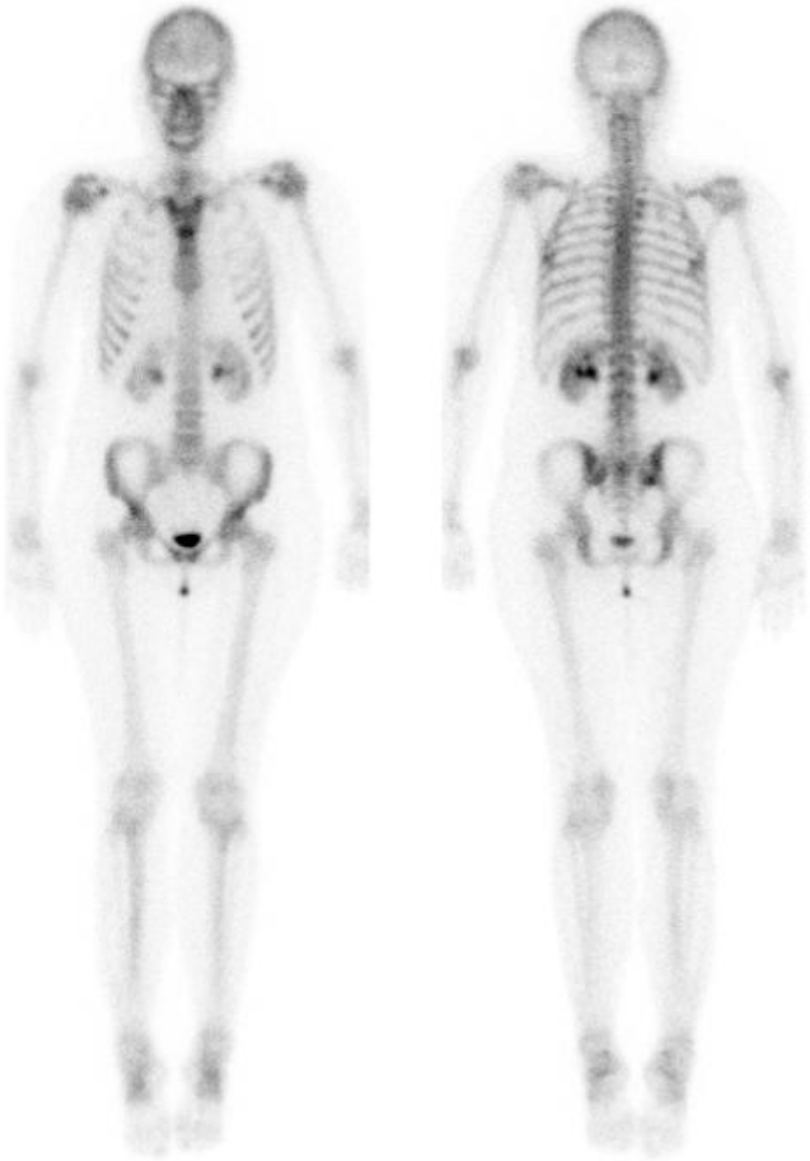

Incorporemos el PET al estudiar la extensión de tumor/ infección

FDG-PET in INFECTION

FDG PET:
- Soft tissue uptakes
- No bone involvement

16 y old girl
Open fractures of both tibia
Multiple surgeries
DD bone vs soft tissue infection
XR normal

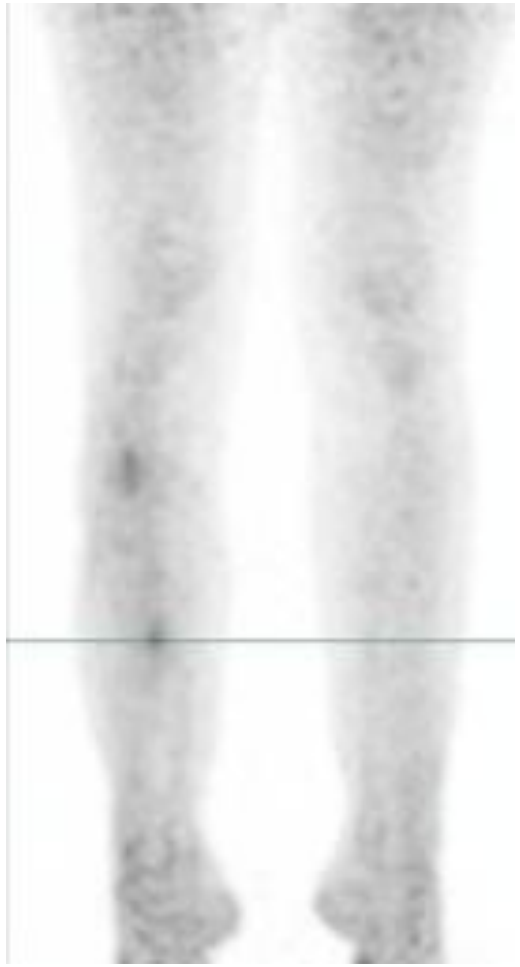

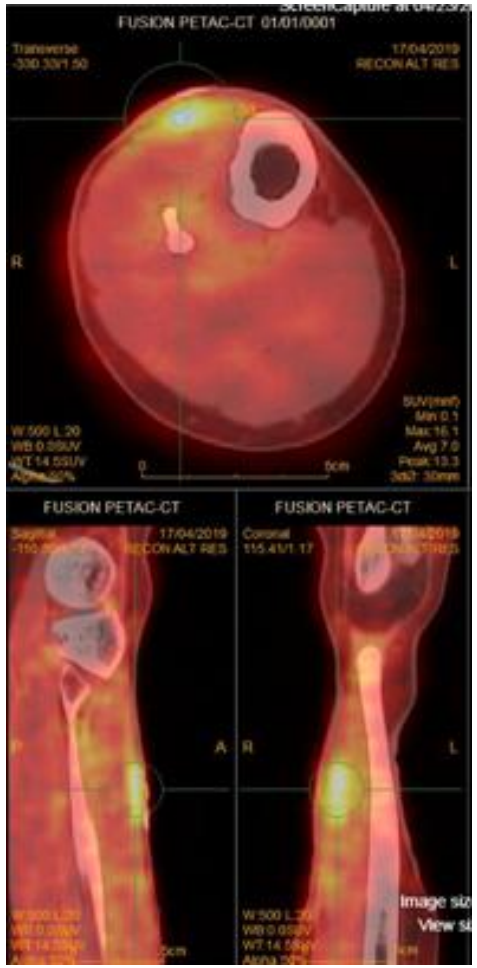

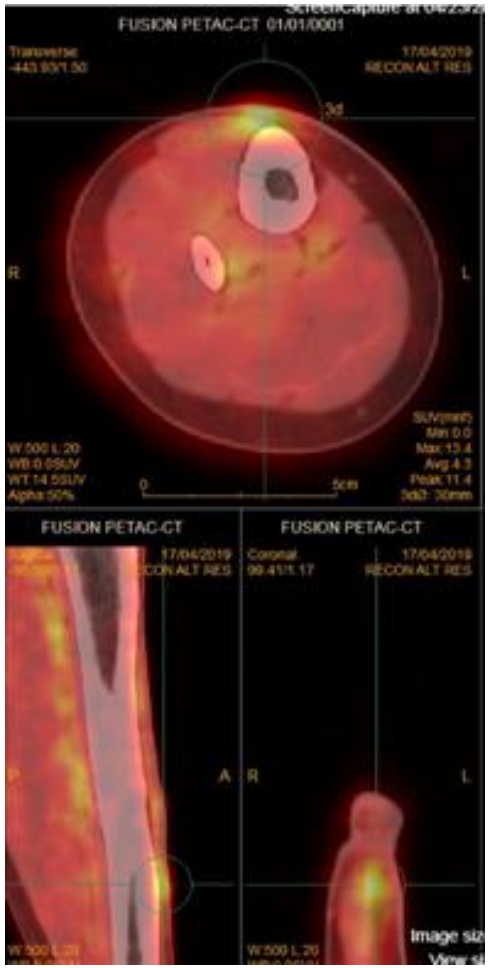

Incorporemos el PET al estudiar la extensión de tumor/ infección

FDG-PET in INFECTION

23 y old girl
Right femur pseudoarthrosis
Infection?

Bone scan:
- BP +
- Bone uptake
  2 foci +
  - heterotopic calcif
  - pseudoarthrosis

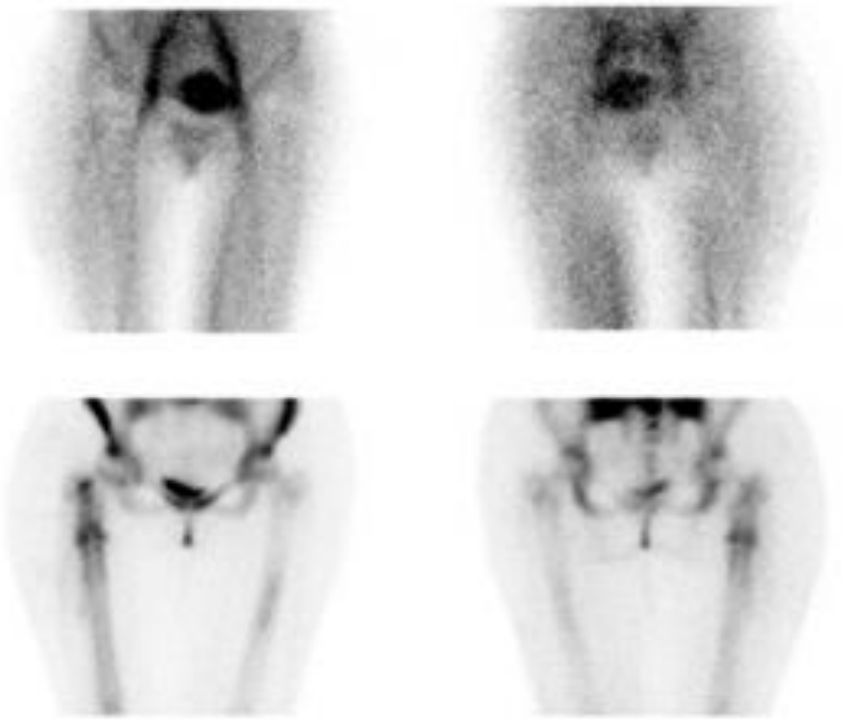

Blood pool

Bone images

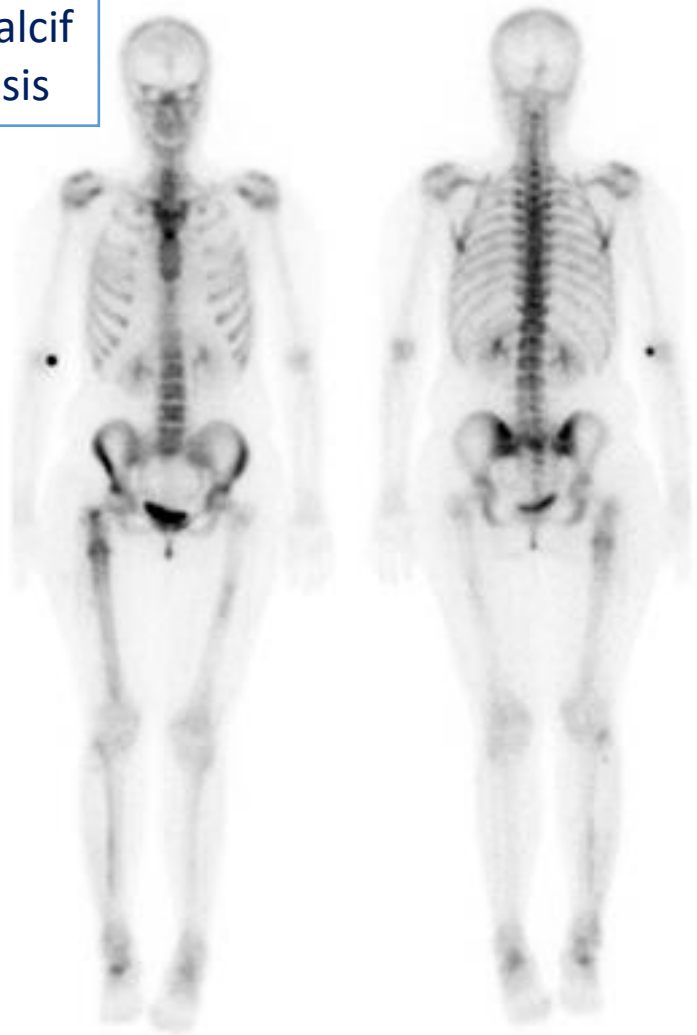

Incorporemos el PET al estudiar la extensión de tumor/ infección

FDG-PET in INFECTION

FDG PET:

- heterotopic calcif
- Pseudoarthrosis

23 y old girl
Right femur pseudoarthrosis
Infection?

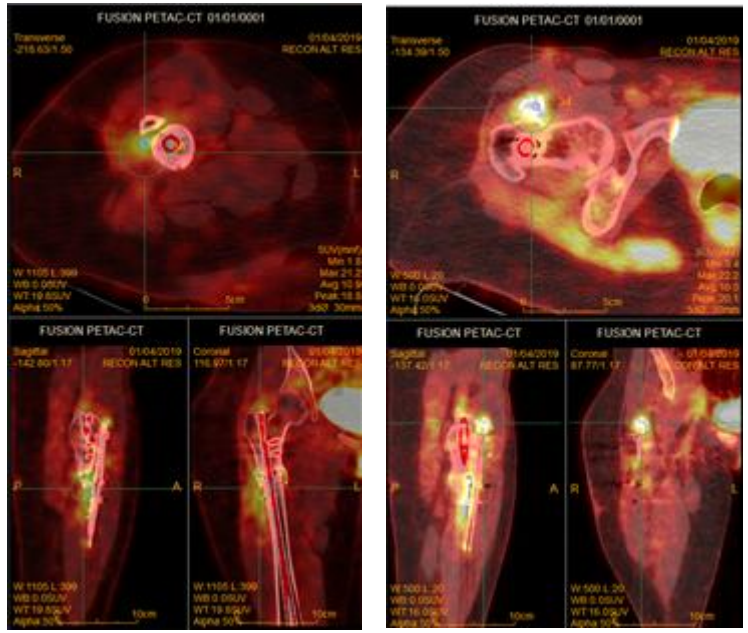

Incorporemos el PET al estudiar la extensión de tumor/ infección

POINTS TO TAKE HOME

Bone Scan and Bone PET are gold standard to value bone metabolism and viability

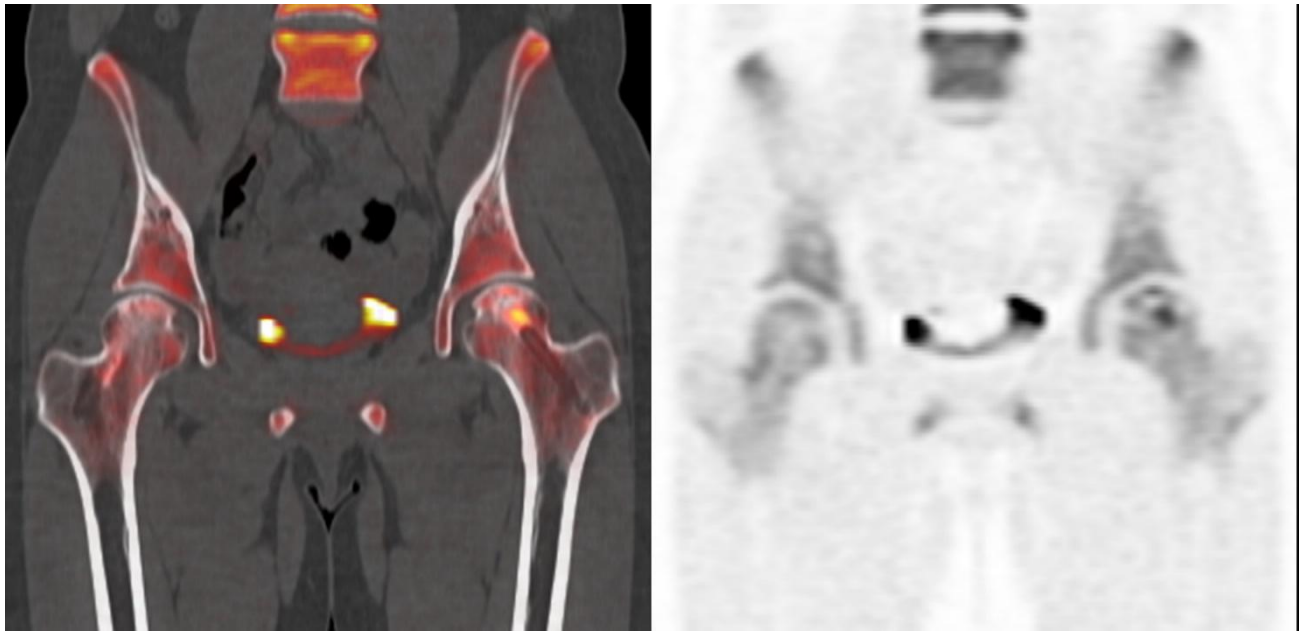

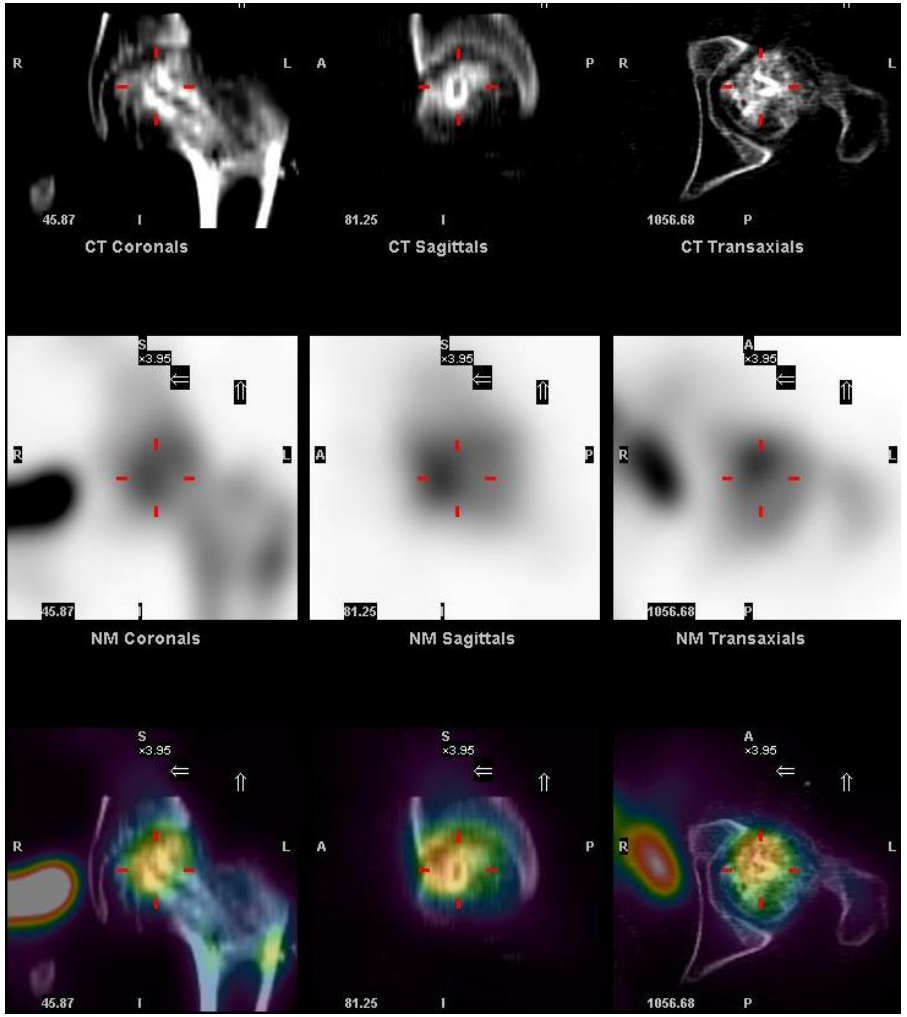

POINTS TO TAKE HOME

Bone scan is critical for the detection and characterization of osteonecrosis in an early phase when interventions may be most effective to ameliorate its progression.

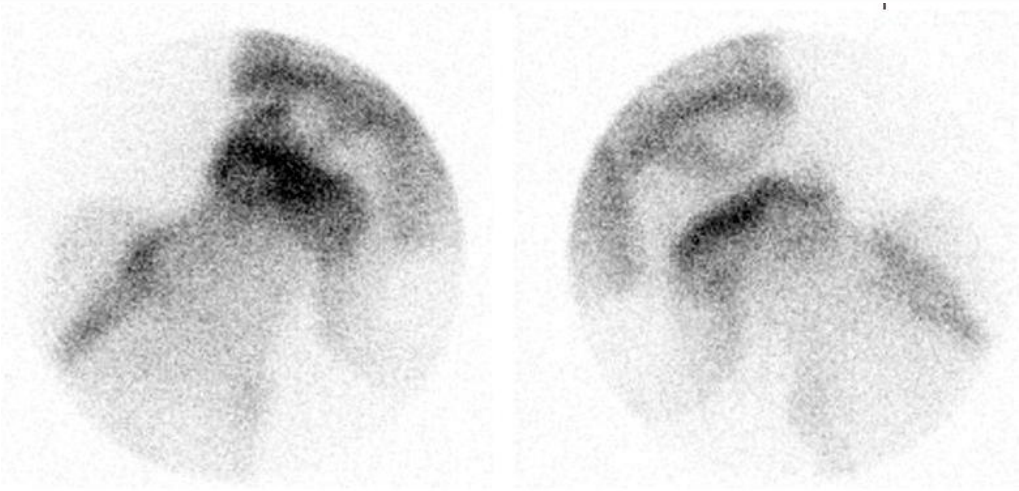

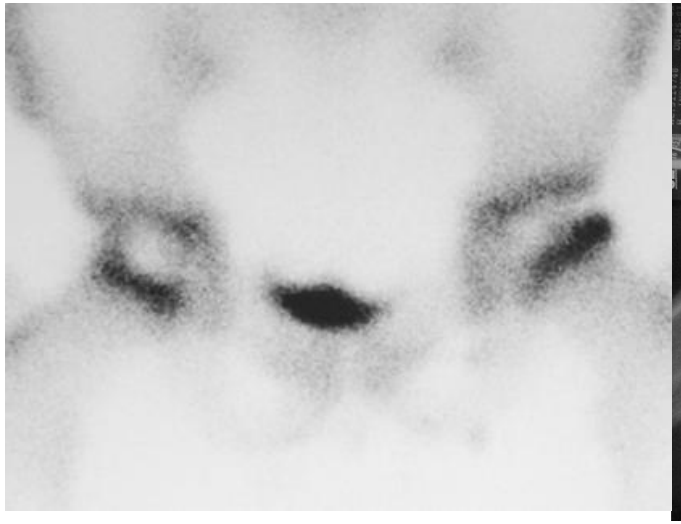

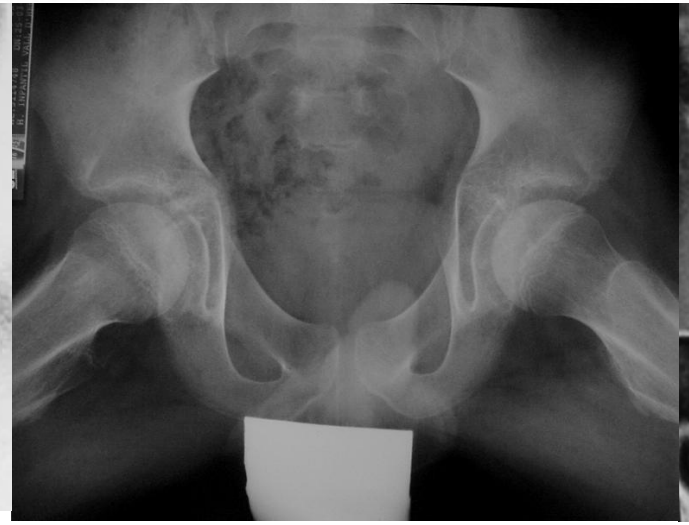

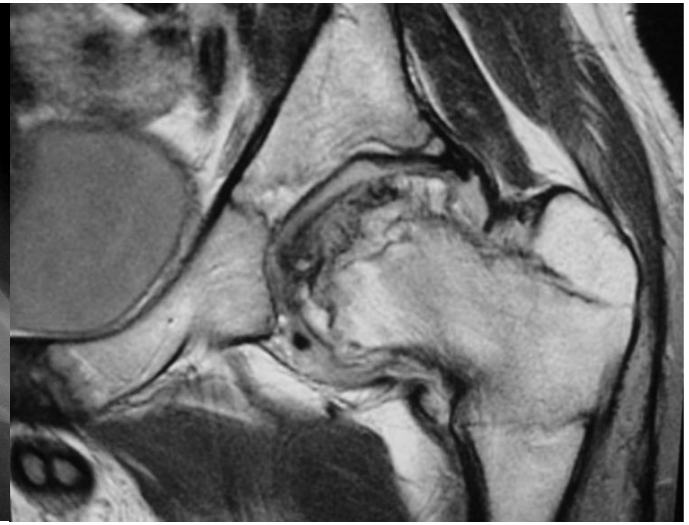

POINTS TO TAKE HOME

SPECT-CT and bone PET are useful imaging tools to evaluate bone viability for both graft and host in new surgical interventions using vascularised bone grafts.

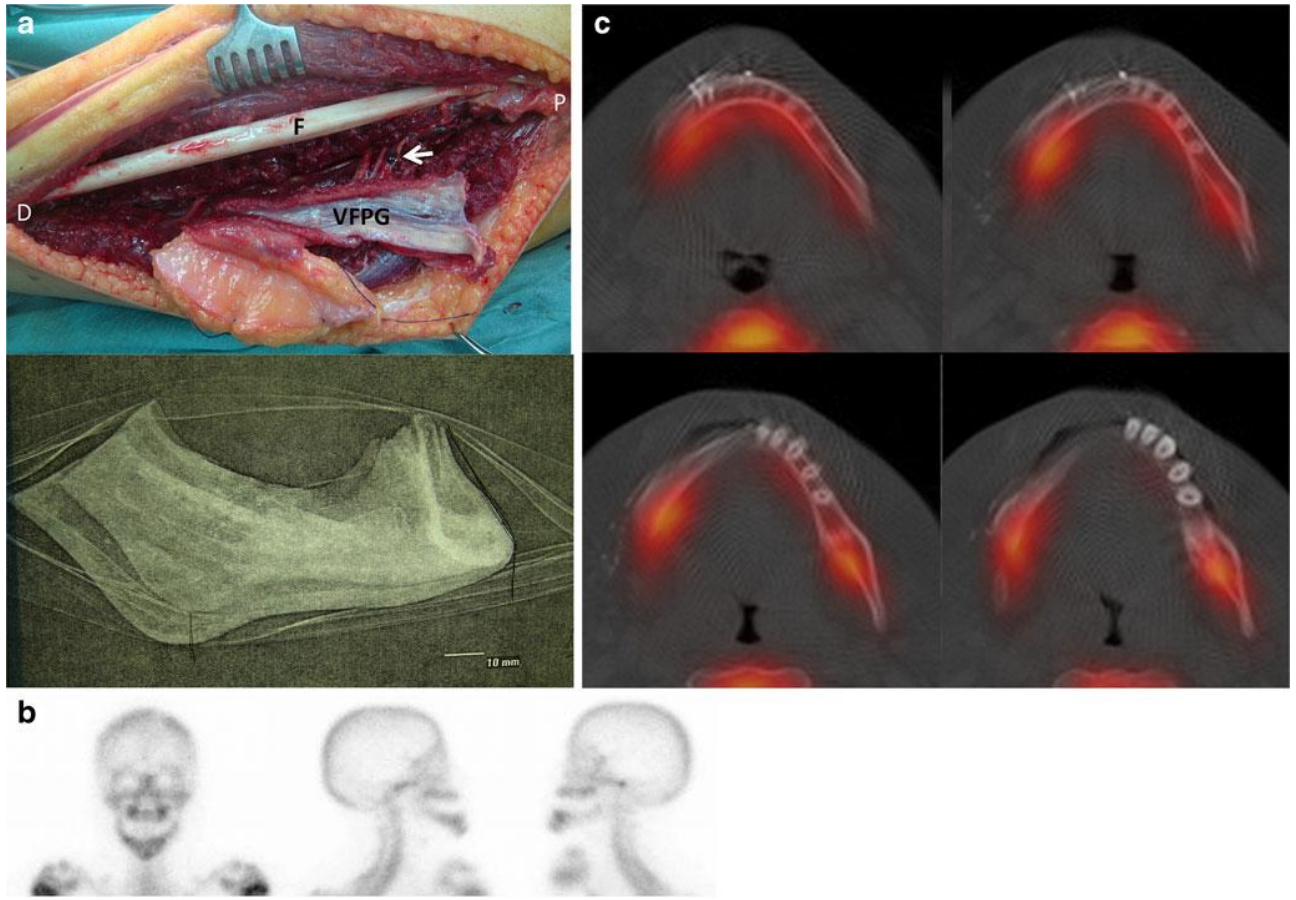

POINTS TO TAKE HOME

Correlative Imaging is the best diagnostic tool that the imaging specialists we can offer to the clinicians.
Best clinical diagnostic can be reached interpreting the correlation between anatomic and functional or metabolic images.

Overall interpretation of molecular and anatomic images, in the clinical setting, will allow us to reach the best diagnostic accuracy

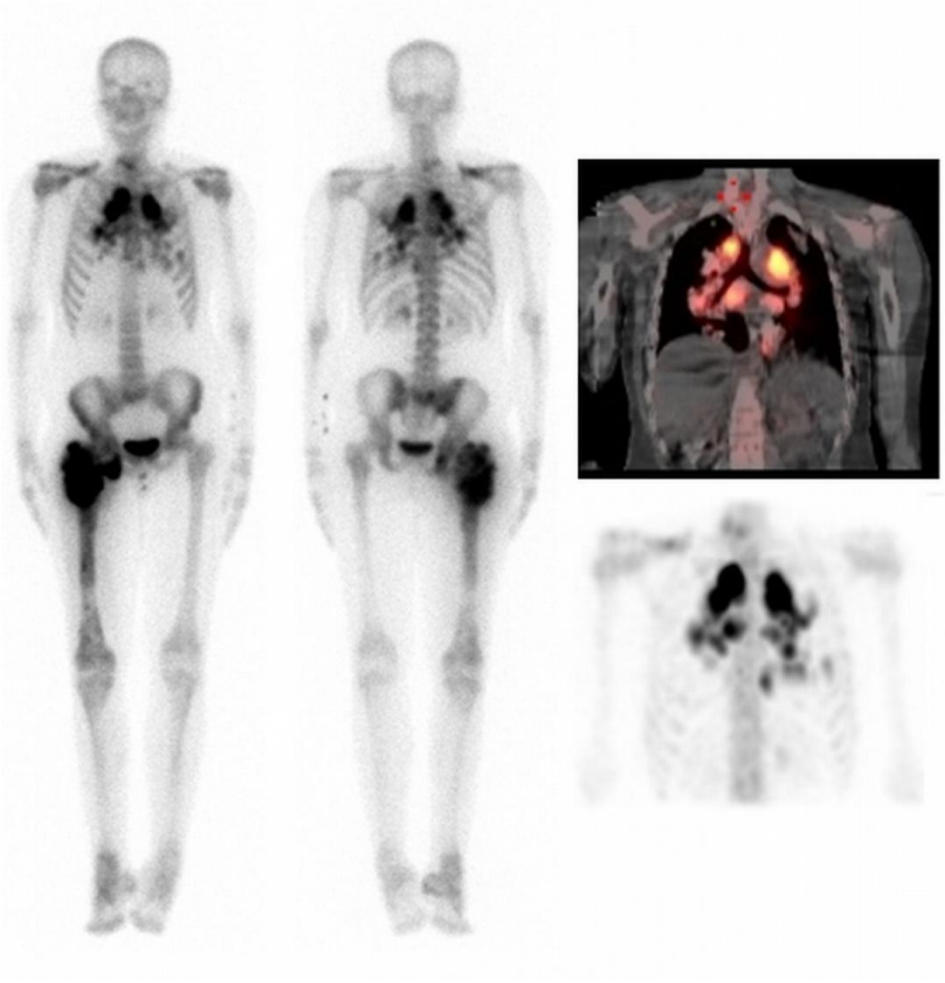

POINTS TO TAKE HOME

BONE PET will be the reference metabolic bone image

- Higher sensitivity
- Lower dosimetry
- Better image quality
- CT not needed, limited use to the lesion

After Sepsis

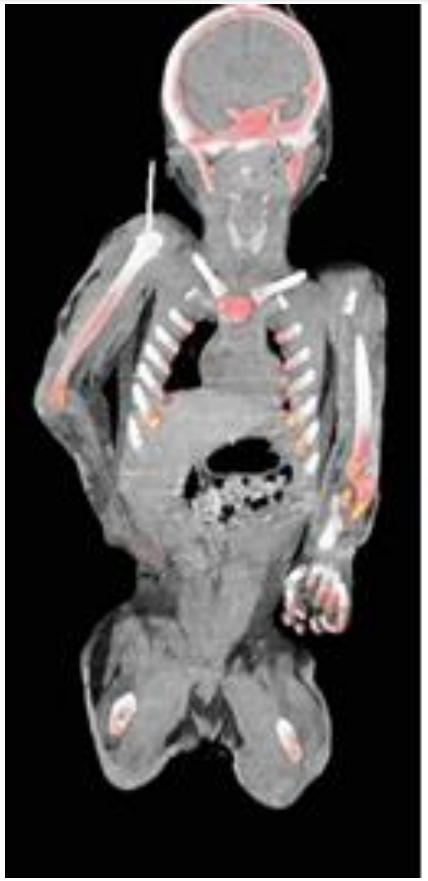

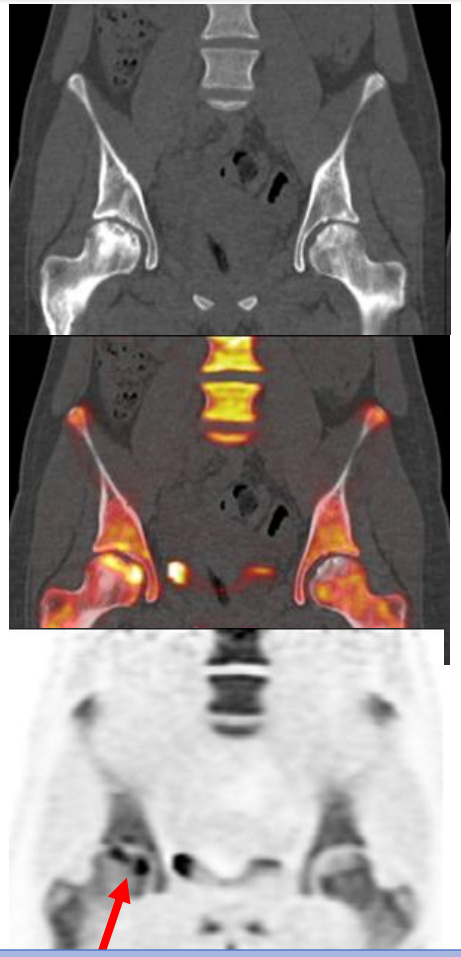

After revascularization Surgery

Incorporemos el PET al estudiar la extensión de tumor/ infección